

The present volume describes
and illustrates timed surgery,
the most efficacious and versatile
operating system in the field of dermatological,
aesthetic and plastic surgery.
Timed surgery is an easy-to-use
standardised technique,
which enables any specialist
to achieve consistent, predictable results
that are unobtainable
with any other method.
The treatise also described a revolutionary
sclerotherapy technique: three-dimensional
regional bisclerotherapy.

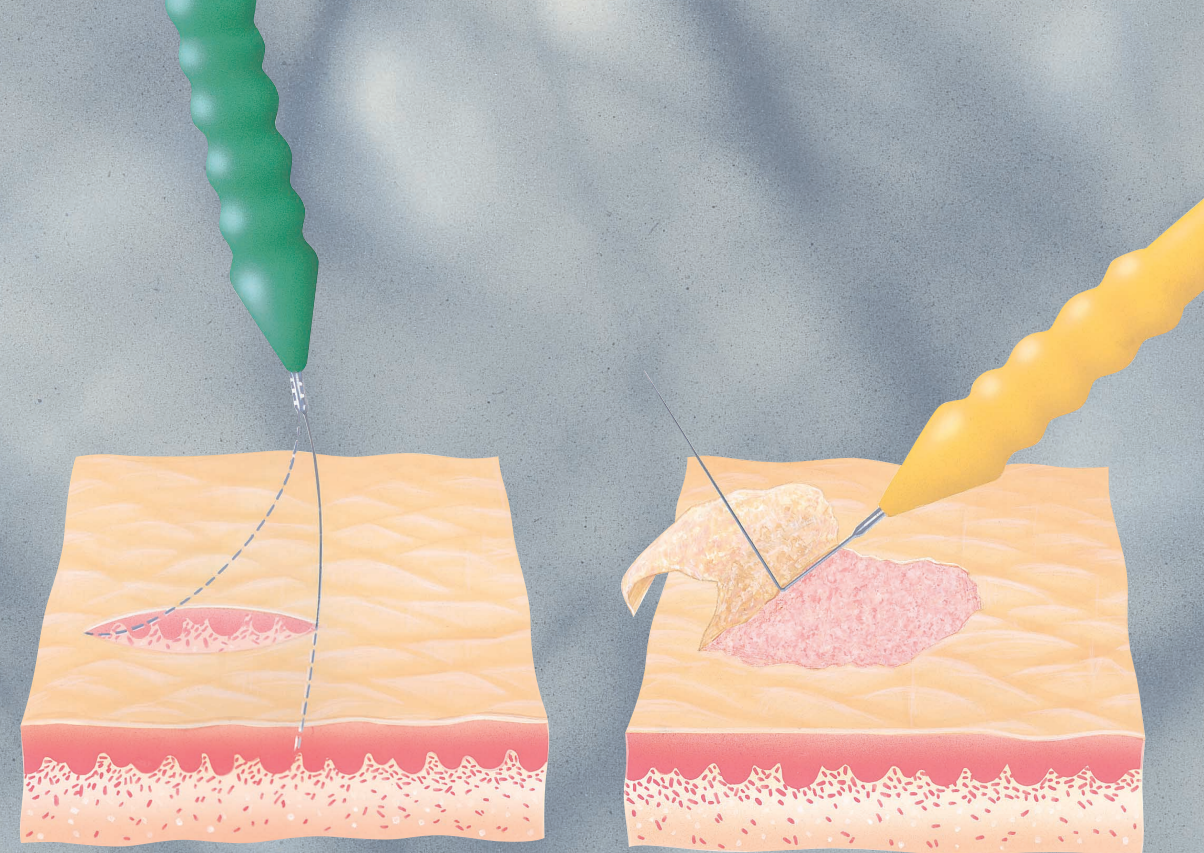


€ 100,00

EDIZIONI
D'ARSONVAL

TIMEDSURGERY®

S. CAPURRO



DERMATOLOGICAL
PLASTIC
AND
AESTHETIC

TIMEDSURGERY®

SERGIO CAPURRO
EDIZIONI D'ARSONVAL

DERMATOLOGICAL
PLASTIC
AND
AESTHETIC

TIMEDSURGERY®

SERGIO CAPURRO

*To Silvia, the muse
of my research*

DERMATOLOGICAL
PLASTIC
AND
AESTHETIC

TIMEDSURGERY®

copyright © 2000 by Sergio Capurro
sergio.capurro@tin.it
www.timedsurgery.org

Previous editions: Timedchirurgia
copyright 2000

Edizioni D'Arsonval® - Korpo® srl
Via XX Settembre, 3/28 - Genova
Tel. +39 010 580335 - Fax +39 010 566968
Internet www.korpo.com
E-mail info@korpo.com

Contributor: Dr Richard Motley
Department of Dermatology University Hospital of Wales, Cardiff

Translation: Bernard Patrick

Illustrations: Mauro Annigoni e Sabrina Marzagalli

Colour plates: Francesco Pachi e Franco Migliorisi

Page layout: Giorgio Cominoli

Photolithography: Studio Colore - Milano

Composition: Fausta Picollo

Printed by: Press Point - Abbiategrasso - Milano

ISBN 88-85185-05-3

March 2002

All rights reserved. No part of this publication may be reproduced, stored in a retrieval system, or transmitted, in any form or by any means, electronic, mechanical, photocopying, recording, or otherwise, without prior written permission from the publisher.

Cover: timed cutting and timed surgical de-epithelialisation.

“... The fact that an opinion is strongly supported does not mean that it cannot be completely absurd...”

Bertrand Russell

ACKNOWLEDGEMENTS

My debt of gratitude extends to all those whose co-operation, support and patience have sustained me in my work, and particularly to Silvia Perrella Segre, who has constantly spurred me to solve the problems of the patient. Silvia runs Korpo s.r.l. and looks after just about everything, from quality control to the construction of the Timed apparatus. She is a pleasure to work with.

I wish to thank Bernard Patrick, who translated the treatise and the CD-ROM into English with the patience and devotion that only a friend can show. Faced with my seemingly endless additions and alterations to the text, necessitated by the ongoing evolution of timed surgery, he never once lost his composure. My thanks also go to Ken Dinnen, Dr Richard Motley and Steven Tilling, who translated the first version of the treatise in 1995 and who provided valuable advice in writing chapters: 5 and 21.

I am indebted to Dr Angela Sementa, who wrote the introduction to the treatment of skin hyperpigmentation and took care of the histological specimens featured in the treatise. She is a pathologist of outstanding quality and our frequent discussions of clinical cases are of great value to me in suggesting new indications and therapeutic possibilities for timed surgery.

I wish to thank Carlo Rava and my colleagues in the Plastic Surgery and Burns Department at San Martino Hospital and the University Clinics in Genoa for their contribution to the experimentation of timed surgery.

Particular thanks are also due to Graziella Pellegrini, Liliana Guerra, Michele De Luca and Sergio Bondanza of the Tissue Engineering Laboratories (IDI, Pomezia-Roma), who cultivated keratinocytes and melanocytes for my technique for the repigmentation of vitiligo.

My affectionate thanks go to Ezio Rizzo, who designed the Timed TD 50 Micropulse, and to Enzo Pronzato, who put it into production together with Franco Rossi, Albert Coccoli, Renato Traverso and Elena Lazzari.

I wish to express my gratitude to Mauro Annigoni, who produced the music and graphics for the CD-ROM and several of the illustrations in the treatise, as well as the beautiful frescoes for the ceilings of my house.

I wish to thank Matteo Pampolini, who produced the CD-ROM and whose intelligence and enthusiasm were a constant source of encouragement. My thanks also go to Vito Brunetti, who patiently and skilfully filmed the timed surgical operations.

I would also like to thank dermatologist Paolo Fiallo and otorhinolaryngologists Marco Barbieri and Renzo Baricalla for their co-operation, Fausta Piccolo, who typed my manuscripts, the graphic designer Giorgio Cominoli for the layout of the figures and Sabrina Marzagallo for her high-quality pencil drawings.

FOREWORD


This treatise describes the numerous surgical, dermatological and aesthetic applications of timed surgery.

Timed surgery has been made possible by the invention of the Timed apparatus. The programme data provide a standardised system which enables any specialist to consistently achieve results that used to be impossible.

Timed surgery and its associated methods compare favourably with the latest and most sophisticated physical techniques, being more economical, safer, simpler, more efficacious and more versatile.

The therapeutic possibilities of timed surgery are constantly being extended and upgraded. The most recent innovations, which do not appear in the Italian addition of the treatise, involve the use of timed surgical resurfacing to eliminate epidermal hyperpigmentation from the face and hands and to remove naevi flammei. The section dealing with three-dimensional regional sclerotherapy, a new sclerotherapy technique made possible by the invention of Bisclero, has also been slightly modified. This technique revolutionises the traditional method, and yields results that were previously unobtainable.

THE AUTHOR



Sergio Capurro was born in Genoa in 1948.

After graduating in Medicine and Surgery at the University of Genoa, he specialised in Reconstructive Plastic Surgery at the University of Milan. He currently works at the Plastic Surgery and Burns Division of San Martino Hospital in Genoa.


In 1978, together with the engineer Ezio Rizzo, he designed the first programmable diathermocautery .

His research in this field subsequently gave rise to the invention of timed surgery and the Timed apparatuses. In 1985, he came up with the idea of the electromaniple, an essential tool in the practice of timed surgery.

Through meticulous experimentation of this method, he perfected the innovative techni-

ques described in the present treatise. These include timed and pulsed cutting; resurfacing to remove tattoos and to level scars; mixed peeling to eliminate wrinkles, blemishes and telangiectatic naevi, de-epithelialisation for the repigmentation of vitiligo; timed surgical cleansing of ulcers, and rapid permanent epilation.

In 1992, he formulated a new sclerosing solution, Bisclero, and created an innovative method of sclerotherapy, three-dimensional regional bisclerotherapy, a valuable complement to some of the above-mentioned techniques.



Prototype for emission duration control (1976)



Experimental prototype (1978)



Timed® TD 100 C (1985)



Timed® TD 52 (1990)



Timed® TD 100 D (1996)



Timed® TD 50 A micropulse (1999)

CONTENTS

1	PREFACE	1
2	BIOLOGICAL EFFECTS OF ELECTRICAL CURRENT	3
2.1	DIRECT CURRENT	
2.2	ALTERNATING CURRENT	
2.3	HIGH-FREQUENCY CURRENT	
2.4	INTERFERENCE CAUSED BY HIGH-FREQUENCY CURRENT	
3	TISSUE CONDUCTIVITY	7
3.1	INSULATORS	
3.2	CONDUCTORS	
3.3	PARTIAL CONDUCTORS	
4	ELECTROSURGERY	9
4.1	MEDICAL DIATHERMY	
4.2	SURGICAL DIATHERMY	
4.3	HISTORICAL DEVELOPMENT OF ELECTROSURGERY	
4.4	SPARK-GAP APPARATUS	
4.5	VACUUM-TUBE APPARATUS	
4.6	TRANSISTOR APPARATUS	
4.7	CONTROL OF EMISSION	
5	TIMEDSURGERY	15
5.1	GENERAL PRINCIPLES	
5.2	COAGULATION	
5.3	MICRO-ARC	
5.4	CUTTING	
6	TIMED APPARATUS	19
6.1	PULSED EMISSIONS	
7	ELECTRODES	23
7.1	MONOPOLAR AND BIPOLAR MODES	
7.2	BIPOLAR ELECTRODES	
7.3	NEUTRAL ELECTRODE	

7.4	MONOPOLAR ELECTRODES	
7.5	EM 10 ELECTROMANIPLES	
7.6	EM 15 ELECTROMANIPLE	
7.7	FEATURES OF ELECTROMANIPLES	
7.8	ADAPTING THE CURRENT TO THE DIMENSIONS OF THE ELECTRODE	
7.9	THE HIGH-FREQUENCY SUPPLY CABLE AND ELECTROMANIPLE CONNECTOR	
7.10	POSITIONING AND TESTING OF CABLES	
8	FUNCTIONS	39
8.1	FULGURATION	
8.2	MICRO-ARC	
8.3	VAPORISATION	
8.4	COAGULATION	
8.5	COAGULATION WITH MICROELECTRODES AND WITH MACROELECTRODES	
8.6	MONOPOLAR AND BIPOLAR COAGULATION	
8.7	TIMED BIPOLAR COAGULATION	
8.8	CUTTING	
8.9	COAGULATION CUTTING	
8.10	TIMED CUTTING	
8.11	TIMEDSURGICAL PULSED CUTTING	
9	FACTORS RESPONSIBLE FOR CUTTING AND COAGULATING	57
	EFFECTS	
9.1	MODULATION	
9.2	PULSED EMISSION	
9.3	ELECTROMANIPLE DIMENSIONS	
9.4	POWER	
10	ELECTROBLITERATION AND ELECTROCOAPTATION	61
10.1	ELECTROBLITERATION	
10.2	ELECTROCOAPTATION	
10.3	COAGULATION OF VESSELS	
11	PRACTISING TIMEDSURGICAL TECHNIQUES	65
11.1	COAGULATION EXERCISES	
11.2	MICRO-ARC EXERCISES	
11.3	CUTTING EXERCISES	
12	ANAESTHESIA IN TIMEDSURGERY	69
12.1	ANAESTHETIC SOLUTIONS	
12.2	TOPICAL ANAESTHETICS	
13	GENERAL RULES	71
13.1	TECHNICAL RULES	
13.2	CLINICAL RULES	

14	ADAPTABILITY OF PROGRAMME DATA	73
15	TREATMENT FOR FACIAL TELANGIECTASIA	75
15.1	8% BISCLEROTHERAPY	
15.2	TIMEDSURGICAL TREATMENT	
15.3	TECHNIQUE	
15.4	POST-OPERATIVE TREATMENT	
16	TREATMENT OF “RED NOSE”	95
16.1	8% BISCLEROTHERAPY	
16.2	TIMEDSURGICAL TREATMENT	
17	TREATMENT OF RHINOPHYMA	99
17.1	DECORTICATION OF LOW-GRADE RHINOPHYMA	
17.2	TECHNIQUE	
17.3	TREATMENT OF HIGH-GRADE RHINOPHYMA IN TWO SESSIONS	
18	BIPOLAR COAGULATION OF SPIDER NAEVUS	107
18.1	TECHNIQUE	
19	TREATMENT OF VENOUS LAKES, VARICES AND MUCOUS CYSTS	117
20	TREATMENT OF ECTATIC VESSELS OF THE LOWER EXTREMITIES	121
20.1	SCLEROTHERAPY EQUIPMENT SCLEROSING SOLUTIONS	
20.2	THREE-DIMENSIONAL REGIONAL BISCLEROTHERAPY	
20.3	TIMEDSURGICAL TREATMENT TECHNIQUE	
20.4	ENDO-OBLITERATION OF VEINS	
21	RAPID DEFINITIVE EPILATION	139
21.1	ANATOMY AND PHYSIOLOGY OF HAIR GROWTH	
21.2	TIMED EPILATION	
21.3	TECHNIQUE	
21.4	PULSED EPILATION	
21.5	EPILATION OF THE FACE	
21.6	EPILATION OF THE BODY	
21.7	POST-OPERATIVE TREATMENT	
21.8	HAIR GROWTH	
22	TIMEDSURGICAL PEELING	159
22.1	PEELING AT LOW POWER	

23	TIMEDSURGICAL RESURFACING FOR LEVELLING SCARS	161
23.1	TECHNIQUE	
24	TIMEDSURGICAL DE-EPITHELIALISATION	165
24.1	CHARACTERISTICS OF THE TIMEDSURGICAL CURRENT	
24.2	DE-EPITHELIALISATION AT 1 WATT	
24.3	PULSED DE-EPITHELIALISATION	
24.4	DE-EPITHELIALISATION OVER MEDIUM-SIZED OR LARGER AREAS	
25	RE-PIGMENTATION OF STABILISED VITILIGO AND ACHROMIC SCARS	173
26	ELIMINATION OF CUTANEOUS HYPERPIGMENTATION	179
26.1	EPIDERMAL HYPERPIGMENTATION TECHNIQUE	
26.2	ELIMINATION OF LENTIGINES ON THE HANDS	
26.3	DERMAL-EPIDERMAL AND DERMAL HYPERPIGMENTATION TECHNIQUE	
26.4	DEPIGMENTATION OF NORMOCHROMIC SKIN	
27	REMOVAL OF TATTOOS	199
27.1	TIMEDSURGICAL RESURFACING	
27.2	ELECTROSALTING TIMEDSURGICAL DE-EPITHELIALISATION SALTING	
28	ELIMINATION OF WRINKLES	213
28.1	MIXED PEELING	
29	TREATMENT OF BIRTHMARKS	223
29.1	BISCLEROTHERAPY	
29.2	MIXED PEELING	
30	TREATMENT OF SMALL CAVERNOUS HAEMANGIOMAS	231
30.1	CUTANEOUS CAVERNOUS HAEMANGIOMAS	
30.2	SUBCUTANEOUS CAVERNOUS HAEMANGIOMAS	
31	INTRODUCTION TO TREATMENT OF BENIGN SKIN LESIONS	237
31.1	SURGICAL EXCISION	
31.2	CRYOTHERAPY	
31.3	ACIDS AND CAUSTIC SALTS	
31.4	THERMOCOAGULATION	
31.5	LASERSURGERY	
31.6	RADIOTHERAPY	

31.7	ELECTROSURGERY	
31.8	TIMEDSURGERY	
32	COAGULATION OF WARTS	241
32.1	COMMON WARTS TECHNIQUE	
32.2	PLANTAR WARTS	
32.3	SMALL COMMON WARTS	
32.4	PLANE WARTS TECHNIQUE	
33	TREATMENT OF CONDYLOMATA ACUMINATA	253
34	COAGULATION OF PYOGENIC GRANULOMAS	257
35	VAPORISATION OF RUBY ANGIOMAS	259
36	VAPORISATION OF SMALL NON-PEDUNCULATED LESIONS	263
37	COAGULATION OF VERY SMALL LESIONS	267
38	COAGULATION OF XANTHELASMAS	269
39	TREATMENT OF KERATOSES	273
39.1	LARGE-SIZED KERATOSES	
39.2	SMALL MULTIPLE KERATOSES	
39.3	TIMEDSURGICAL UNDERMINING	
40	TREATMENT OF INGROWING TOE-NAILS	285
41	COAGULATION OF LACHRYMAL CANALS	289
42	BIPOLAR COAGULATION OF NASAL TURBINATES	293
42.1	COAGULATION OF NASAL TUBINATES	
42.2	COAGULATION OF THE NEUROVASCULAR CENTRE	
43	EXCISION WITH TIMED AND PULSED CUTTING	297
43.1	CUTTING THROUGH THE WHOLE THICKNESS OF THE SKIN TECHNIQUE	
43.2	ELECTROSHAVING TECHNIQUE	
44	TIMED AND PULSED CUTTING IN EYELID SURGERY	307
44.1	EXCISION OF LESIONS ON THE EYELIDS	
44.2	BLEPHAROPLASTY OF THE UPPER LID	
44.3	TRANSCONJUNCTIVAL LOWER BLEPHAROPLASTY	

CONTENTS

45	TIMED AND PULSED CUTTING IN ORAL SURGERY	323
45.1	TECHNIQUE	
46	EXCISION OF PEDUNCULATED AND LIFTABLE LESIONS	329
46.1	TECHNIQUE	
47	REMOVAL OF WHITEHEADS	337
47.1	TECHNIQUE	
48	REMOVAL OF MILIA	341
48.1	TECHNIQUE	
49	ATRAUMATIC EXCISION OF MELANOMA	343
49.1	TECHNIQUE	
50	TREATMENT OF PRECANCEROUS LESIONS	347
51	TIMEDSURGICAL CLEANSING OF ULCERS	349
51.1	TECHNIQUE	
52	APPENDICES	365
	PROGRAMME DATA	369
	BIBLIOGRAPHY	383
	INDEX	387

1

PREFACE

Since the early 20th century electricity has been used in treatments in medicine and surgery. The term electrosurgery encompasses the techniques in which heat generated by the passage of a high-frequency current enables living tissues to be incised and coagulated. An understanding of electrosurgery is essential for surgeons, who rely on its use for many surgical procedures, and is also invaluable to those working in the field of dermatology.

Electrosurgery is an empirical technique; it is not taught at undergraduate level, and even in specialist training it is difficult to acquire the experience necessary to take full advantage of the techniques available. In 1978 the invention of the Timed apparatus, which allows control of all of the parameters affecting diathermic emissions in living tissue, gave rise to a new technique: timed surgery (technique for the implementation of measured electrosurgical data). This has led to new possibilities in the utilisation of high-frequency current, thus enabling operations to be carried out which were previously considered impossible and facilitating traditional procedures.

With timed surgery it is possible to make a perfectly controlled cut (timed or pulsed cutting) which does not burn at the edges. Micro-incisions in particularly delicate regions can be made, for example in the eye-

lid, and precise bloodless operations can be performed on the oral mucosa. Timed cutting is also useful in the excision of malignant melanomas, in that it prevents intraoperative metastatic spread. Cutaneous and mucous membrane incisions can be stitched and heal rapidly.

Timed coagulation permits complete elimination of spider naevi and microtelangiectasias of the face without scarring, elimination of small lesions without anaesthesia, and rapid definitive epilation. With timed surgery it is possible to carry out treatment of telangiectatic naevi, the elimination of wrinkles, the removal of tattoos, the cleansing of ulcers, skin re-pigmentation and de-pigmentation, timed surgical de-epithelialisation and resurfacing etc. With timed surgery, even those using the method for the first time can achieve optimal results. The programme data are valid for all patients, since the current, unlike other forms of energy, is based on the electrical conductivity of the tissues, which is practically the same from one individual to another.

The ease of use and improved versatility of this operating method allow its adoption in various fields, such as plastic surgery, dermatology, otorhinology, oral surgery, and ocular surgery.

The efficacy of each procedure will be checked visually and the operator will

adjust the values specified for the various applications in accordance with the concepts described in the following pages.

Video clips of each procedure can be seen on the CD-ROM which accompanies the treatise.

At the beginning of the description of each procedure, the specific set of recommended programme data is given.

In the first 9 sections the theoretical principles of timed surgery are presented. It is important that these be read in order to understand the numerous possibilities of this operating method.

2 BIOLOGICAL EFFECTS OF ELECTRICAL CURRENT

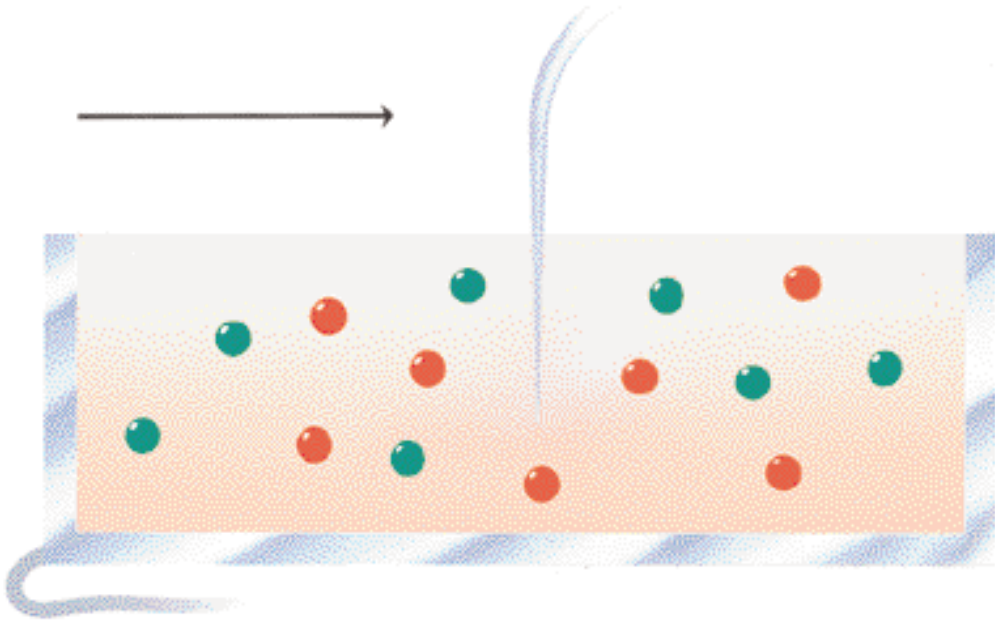


Fig. 2.0.1 A graphical representation of the ions within living tissue prior to the application of electrical current.

In order to understand timed surgery, it is necessary to understand the effect of an electrical current on living tissue (**Fig. 2.0.1**).

Three types of current can be distinguished: direct current, alternating current and high-frequency alternating current. Only this last is used in timed surgery.

2.1 Direct current

Direct current, which is produced by batteries and dynamos, flows in a

single direction and does not change polarity. If a direct current is passed through living tissue, the ions, which are normally distributed uniformly, migrate toward the electrodes (electrolysis).

The “anode” or positive electrode acquires negative ions (e.g. Cl^- and HCO_3^-) while the “cathode” or negative electrode acquires positive ions (e.g. Na^+ and K^+). If the current is applied for sufficient time, the accumulation of ions leads to a chemical lesion due to local acid/base imbalance (**Fig. 2.1.1**).

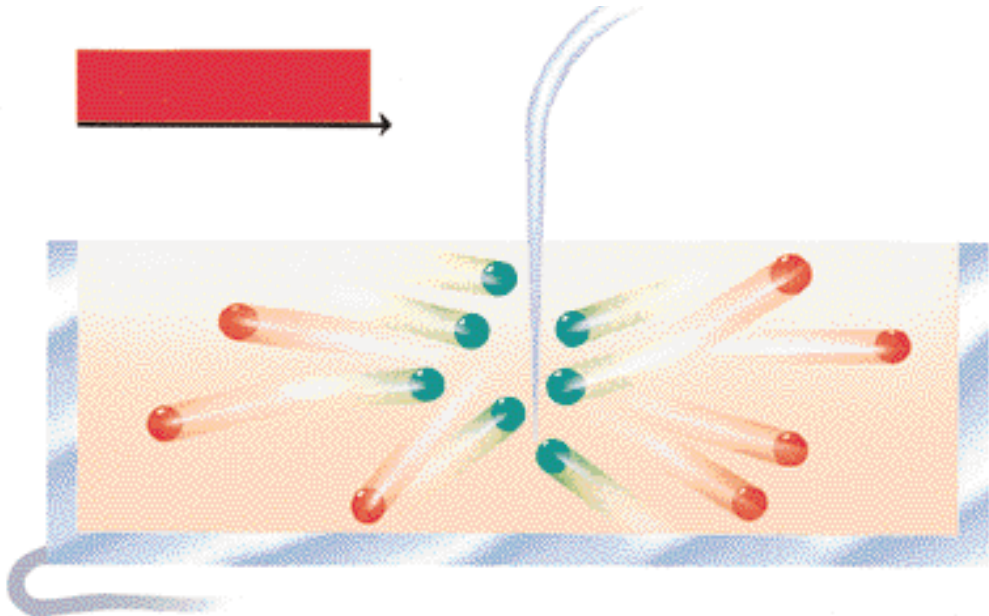


Fig. 2.1.1 With the application of direct current to living tissue, there is a movement of ions towards the electrodes, thus producing local concentrations of acid and base zones. This gives rise to a chemical lesion of the tissue.

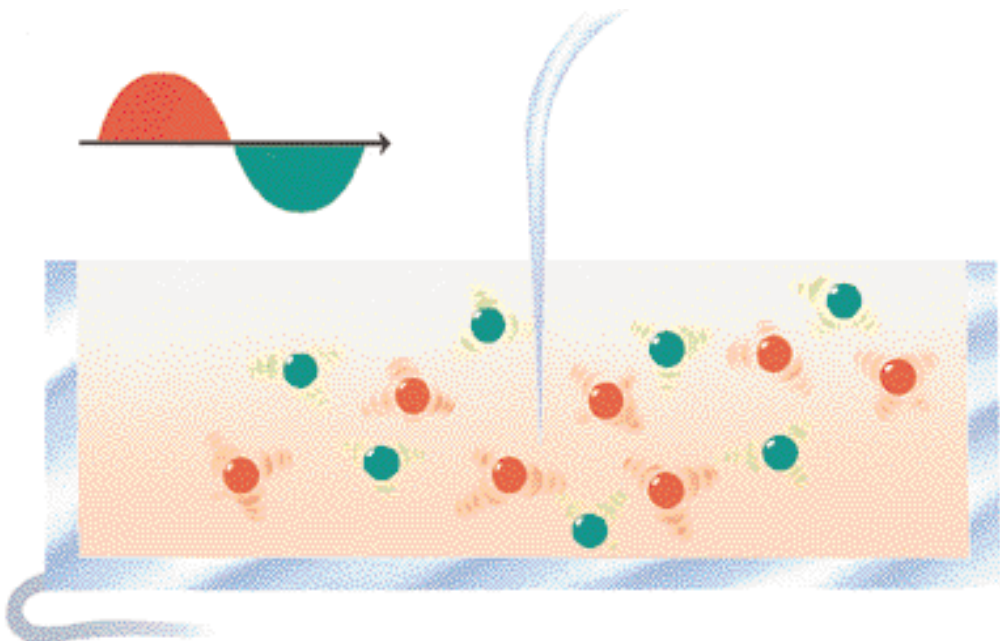


Fig. 2.2.1 A low-frequency alternating current stimulates nerves and muscles but produces no net movement of ions in the tissue and no change in tissue pH.

2.2 Alternating current

Alternating current is generated by an alternator and is characterised by cyclical reversal of polarity and direction of current flow. The normal domestic electricity supply is an alternating current which changes direction 50 or 60 times a second (50 - 60 Hz).

If an alternating current is applied to living tissue, the direction of movement of ions in the tissue changes with each change of current direction. If the frequency of the current is high enough, the ions oscillate closely about their original position and there is no net migration of ions and no production of acid and base zones. Low-frequency alternating current is, however, able to stimulate nerves and muscles at relatively low power levels (**Fig. 2.2.1**).

2.3 High-frequency current

High-frequency alternating current may be produced by several types of oscillator. Spark-gap coil and capacitor circuits were the first to be used, followed shortly afterwards by the first vacuum tube oscillators; more recently, solid-state electro-surgery machines were developed. The typical frequency used in electrosurgery is of the order of 500 KHz. At this frequency the changes in direction of current flow are so rapid (500,000 times a second) that heat is generated in the tissue (**Fig. 2.3.1**). As the threshold for nerve and muscle stimulation increases with frequency, at lower frequencies muscular fibrillation may occur, producing an unpleasant sensation of electric shock in the unanaesthetised patient. This can also occur if a spark

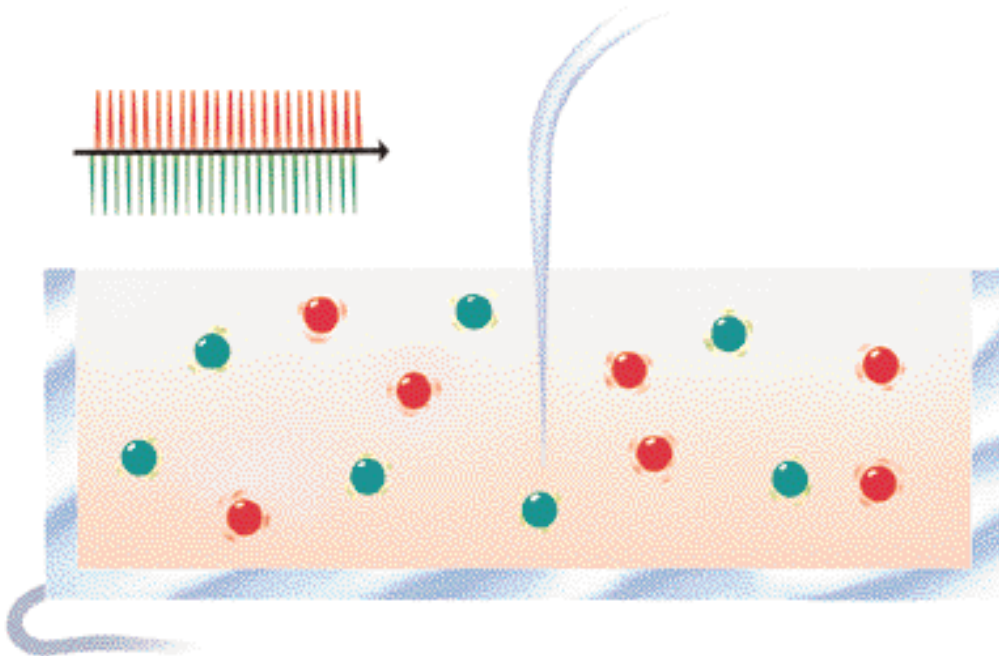


Fig. 2.3.1 With the application of high-frequency alternating current, the oscillation of ions is so rapid that the only effect is the generation of heat.

forms between the electrode and the tissue, in which case the high frequency current may be partially split into lower frequency components or even direct current. To minimise these untoward effects, it is desirable to use frequencies above 800 KHz. At this frequency, the changes in direction of current flow are 800,000 a second.

2.4 Interference caused by high-frequency current

High-frequency current can propagate through mechanisms other than the movement of ions, or charged particles, through materials normally considered to be insulators, for example rubber, plastics and air. Indeed, the transmission of radio waves is possible because of these phenomena. For this reason electrosurgical generators may interfere with local radio and television reception as well as with monitoring equipment attached to the patient (e.g. electrocardiographs and implanted pacemakers).

Although the frequency used in timed surgery is selected to minimise such interference, it is impossible to prevent it totally. Interference is not produced by the generator itself, but by the emission of high-frequency current.

Very high frequencies (> 2 MHz) are not used in timed surgery because it is very difficult to contain the current within a cable and electrical dispersion tends to occur through many routes, leading to the generation of heat over a wide area. This property can be utilised to advantage;

for example, when operating on parenchymatous organs (e.g. liver) a series of coagulations can be produced intentionally in the general area of an incision.

With very high-frequency currents, dispersion through the air is also influenced by atmospheric conditions; such high frequencies are therefore unsuitable for use in timed surgery, which requires a perfectly constant energy transfer to the patient at all times.

High frequencies are also used to induce hyperthermia with ferromagnetic implants.

3 TISSUE CONDUCTIVITY

High-frequency current produces heat as it flows through the tissue. To understand this, it is necessary to understand the concept of conductivity. Conductivity is the readiness of a material to allow the passage of current, through the movement of ions and charged particles. Materials can be classified into three categories according to their conductivity: insulators, conductors and partial conductors.

3.1 Insulators

Insulators do not allow the passage of electrical current. They have virtually zero conductivity. Examples of such materials are glass, plastic, rubber, ceramics, oil, fat and distilled water. Because no current passes through them, the application of electric potential produces no effect.

3.2 Conductors

These materials allow current to pass easily; they have high conductivity. These materials are mostly metals. The passage of current produces a heating effect, which is normally small because of the ease with which the current flows.

3.3 Partial conductors

Moderately conductive materials allow current to pass but provide resistance to its flow. Examples include animal and vegetable tissues, which contain water. The heating effect of the current is dependent upon the current density, i.e. the flow of current divided by the cross-sectional area of the conductor. In formulating the heating effect of electricity, it is customary to refer to the resistance of the material, which is the reciprocal of the conductivity.

Power dissipated in the form of heat by the passage of current through a section of tissue is given by:

$$P = I^2 * \rho * L/A$$

where: P = power (watts)

I = current (amps)

ρ = resistance (ohm.m)

L = length (m)

A = area (m²)

High-frequency current does not produce noticeable chemical effects or stimulation of nerves and muscles. It is utilised to coagulate or cut tissue; these effects are produced by localised heating in the vicinity of the active electrode.

Electrical conductivity is related to the amount of water contained in the tissues, and to the characteristics of the current. When the tissue contains

water, its resistance (or, more correctly for alternating currents, impedance) is lower; when the tissue is dry, its impedance is high. In practice, any variation in conductivity between individuals is very slight, which enables the data to be standardized for all the various timesurgery applications.

The conductivity of animal organs is not identical to that of electrolytic solutions, since it varies according to the type of tissue. The skin, for example, has within its structure various components with differing conductivity. The stratum corneum is a fairly good insulator, while blood vessels and nerves in the dermis constitute a preferential route for the passage of electricity. The most conductive tissues allow the greatest current flow and are therefore more easily damaged.

The high conductivity of the nerves accounts for the fact that little pain is felt post-operatively when high-frequency current has been used. In fact, the nerve endings which suffer the most damage are those farthest away from the area operated on, and are therefore farther from phlogogenic substances (kinin, bradykinin, histamine). They are also less involved in the scarring process which occurs later. In 1935, Mock noted that mastectomies carried out with electrocautery caused less post-operative pain than those carried out with a scalpel.

In the vicinity of important nerves, for example in the region of the eyelid, it is desirable to use brief, controlled timesurgical emission in order to reduce the risk of current channelling through the nerves and causing damage.

The high conductivity of blood vessels and the use of electrodes with a mechanical function (e.g. forceps) facilitate haemostasis by means of diathermocoagulation.

4

ELECTROSURGERY

Electrosurgery or surgical diathermy was conceived at the end of the nineteenth century when d'Arsonval demonstrated that an alternating current of sufficiently high frequency could pass through living tissue without causing a shock, producing only localised heating, due to the electrical resistance of the tissue (D'Arsonval 1893). This effect was named diathermy from the Greek *diá* = through, and *thermós* = heat. (Nagelschmidt 1907).

If the diathermy current is distributed over a large area, it produces a widespread heating effect without tissue coagulation (medical diathermy). If, on the other hand, electrical current is concentrated in a small area, the heat generated is sufficient to produce cutting or tissue coagulation (surgical diathermy).

4.1 Medical diathermy

When two electrodes with large surface areas are used, current density is low and tissue damage does not occur; the only effect is heating in the area between the electrodes. This is known as medical diathermy (**Fig. 4.1.1**)

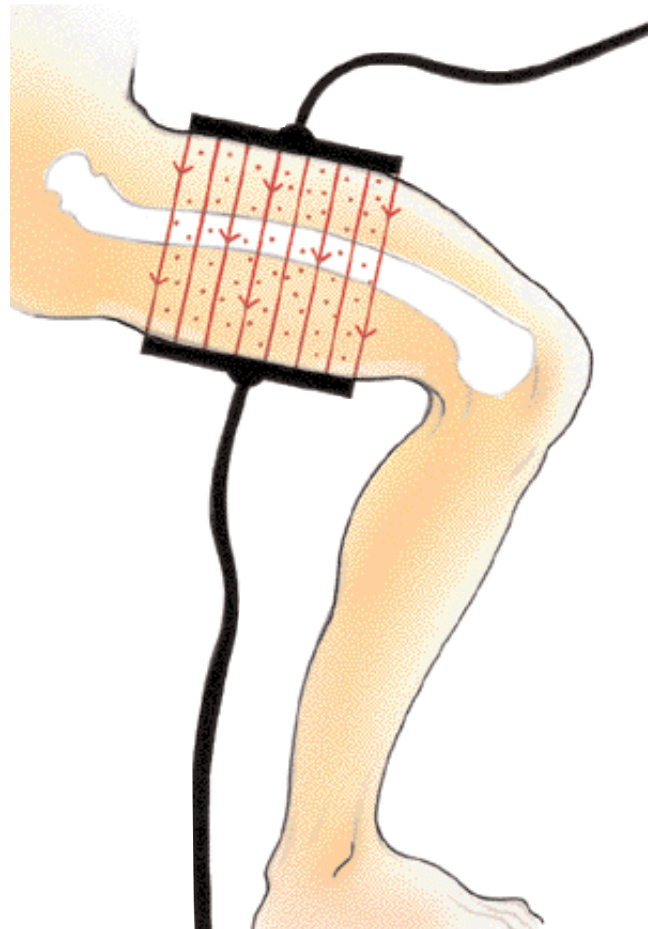


Fig. 4.1.1 Medical diathermy. This is obtained by using two large, equally-sized electrodes. As the high-frequency current is distributed over a large area, it produces heating but does not damage the intervening tissues.

The heat thus produced accelerates chemical changes, speeds up the metabolism and increases blood flow by dilating blood vessels and releasing vasodilatory substances.

It induces a relaxing effect on muscles and soothes nerves.

With a sufficiently powerful current, this effect may also be used to destroy tumours which are particularly sensitive to heat.

4.2 Surgical diathermy

Surgical diathermy, or electrosurgery, utilises the effect produced when one or both of the electrodes is reduced in size. When the electrode is small, the current density is increased to the extent that, at the site of application, it causes coagulation of proteins or vaporisation of water contained in the tissues (**Fig. 4.2.1**).

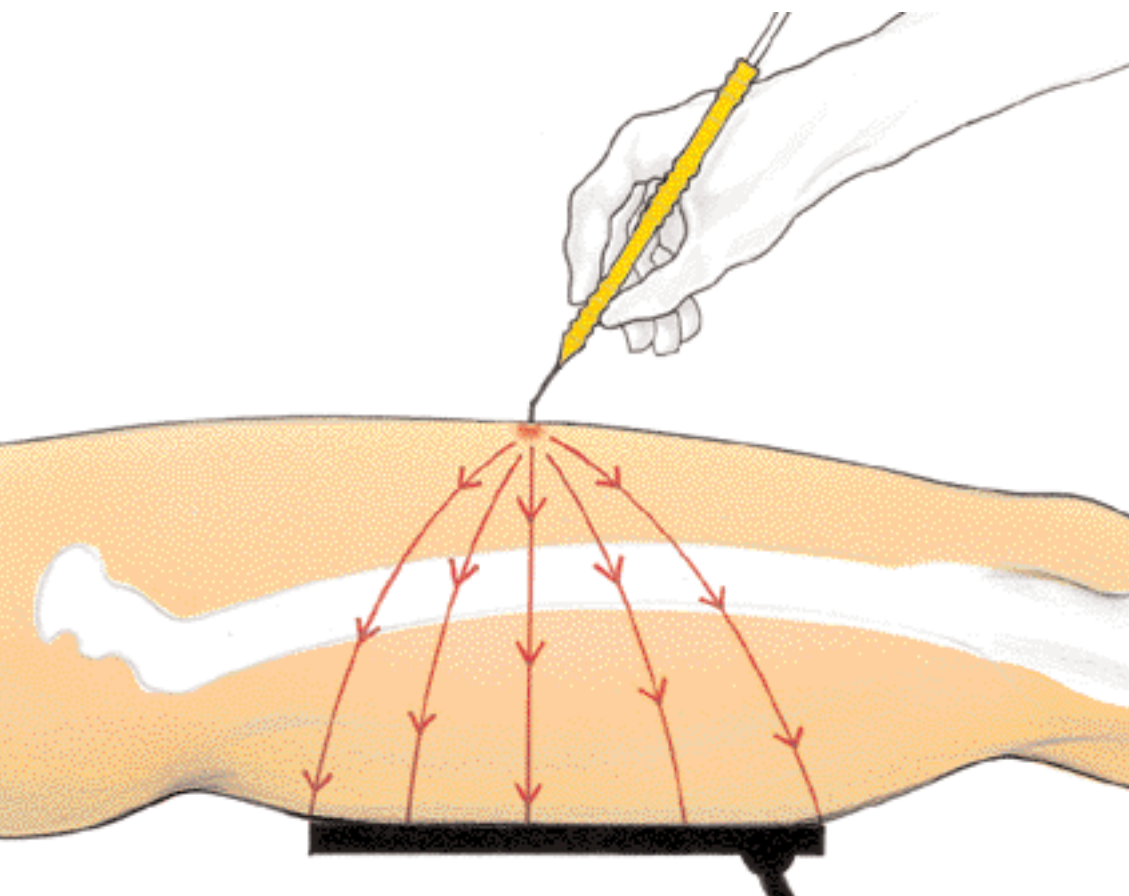


Fig. 4.2.1 Surgical diathermy. When the dimensions of one or both electrodes are reduced, the resulting high current density leads to localised tissue destruction.

Tab. 4.1 Subtypes of Surgical diathermy

Diathermocoagulation	Diathermic cutting
Micro-arc	Fulguration

Surgical diathermy can be subdivided into fulguration, micro-arc, diathermocoagulation and diathermic cutting (Tab. 4.1). In the two latter procedures, diathermic heating is produced within the tissue, while the metal electrode, because of its very low resistance, remains virtually unchanged in temperature by the passage of the high-frequency current. In the past, this technique was called “cold coagulation” to distinguish it from the “hot coagulation” produced by thermocautery. Thermocautery, which utilises a resistive metal loop, is still used today, but its effects are slow and superficial and the results are difficult to reproduce. The greater efficacy of surgical diathermy is due to the fact that the electrical conductivity of tissue is far greater than its conductivity of heat.

Surgical diathermy has many other advantages: it is rapid, precise and effective; the equipment is relatively simple and requires little maintenance and is consequently economical. As it has several possible functions (see section 8), it can be used in numerous procedures. Accurate regulation of power permits well-controlled and localised tissue destruction. Using very small electrodes, it is possible to work in

areas with restricted access, for example in endoscopic surgery. Diathermic cutting has an excellent haemostatic effect, seals lymphatic vessels and kills tumour cells. It can be used to operate on infected areas. Post-operative pain is limited. There are of course a few disadvantages associated with surgical diathermy. It cannot be used in the presence of inflammable or explosive substances. It produces fumes which may be unpleasant for both user and patient, and the fine electrodes are subject to wear. Formerly, an additional disadvantage was the difficulty in learning the technique, but with the development of timed-surgery the training has become simple.

4.3 Historical development of electrosurgery

Owing to its characteristics, surgical diathermy rapidly found many applications. It was used initially to destroy tumours, later for cutting and surgical haemostasis and subsequently for numerous dermatological and cosmetic operations. In 1900, Riviere demonstrated that, at equal power, a greater lysive effect was produced with small electrodes,

owing to the greater current density. In 1907 de Keating - Hart and Pozzi coined the term fulguration (from Latin **fulgor** = lightning) to describe the superficial carbonisation caused by a spark between the electrode and the tissues.

In 1907 de Forest patented the triode vacuum tube and in 1908 he used a vacuum tube oscillator to produce the first diathermic cutting effect. In 1909 Doyen used a low voltage, high-current, biterminal instrument to produce temperatures of 500-600°C, which were far higher than those previously obtained. In 1911 Clark differentiated electrocoagulation and fulguration. Later, in 1924, Wyeth and Clark demonstrated the different effects of modulated and non-modulated high-frequency current on the tissue. In 1926 Wyeth produced a generator capable of providing a cutting current and called the device "endothermic knife".

Much of the credit for the popularity of diathermosurgery is due to Bovie, who in 1928 described an instrument in which cutting and coagulation functions could be combined to control bleeding during electrosurgery. In 1940, Greenwood produced an important accessory, the bipolar forceps. These forceps had blades which were electrically insulated from each other and were connected to both outputs of the diathermic generator. This technique of bipolar coagulation became indispensable in micro- and neurosurgery.

In 1958, Malis developed a bipolar diathermocautery with a floating

patient circuit completely insulated from the electrical supply, thereby increasing the safety of the technique.

In 1970, spark-gap and vacuum-valve apparatus started to be replaced by more reliable and precise transistor-driven equipment and, by the end of that decade, the Timed apparatus had been developed (Capurro 1979).

In the middle of the 1990s, timed-surgery exploited medical scientific innovations to transfer knowledge from one operator to another in a methodical way, thus giving rise to timed surgery, the most versatile operating system in the field of dermatological, plastic and aesthetic surgery.

4.4 Spark-gap apparatus

Spark-gap generators are the simplest means of producing high-frequency currents. They function by discharging a capacitor across two electrodes of large surface area but in close proximity (approximately 1 mm apart). The potential supplied to the capacitor is increased to a few thousand volts by means of a transformer. When the voltage across the capacitor is sufficiently high, a spark arcs between the electrodes. The repeated charging and discharging of the capacitor generates a series of pulses of current with a wide range of frequencies (100 KHz - 1 MHz) and a high peak voltage, which is maximum at the initiation of the spark and falls to zero as the capacitor discharges. This process is repeated at every cycle of the main

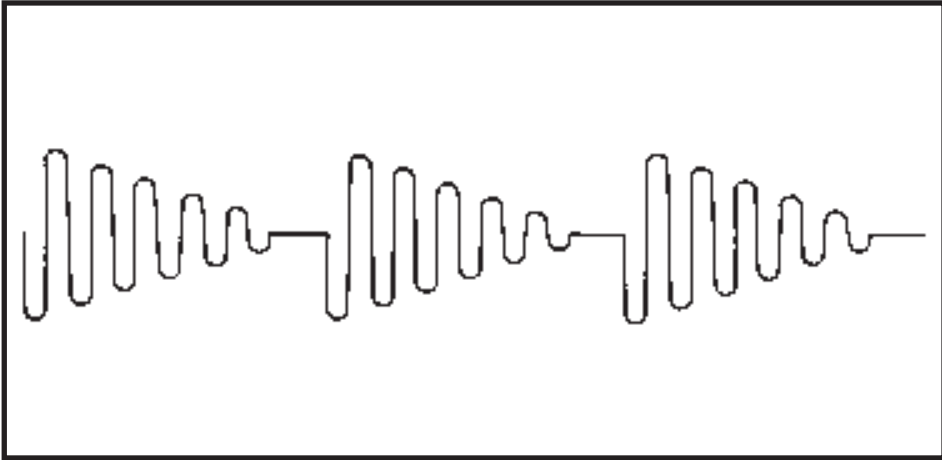


Fig. 4.4.1 The typical waveform produced by spark-gap apparatus. The intermittent nature of the output makes it impossible to achieve reproducible effects with timed outputs.

supply (**Fig. 4.4.1**). The frequency of the electrical discharge can be altered by modifying the spark-gap distance, but the pulse frequency is fixed by the frequency of the supply (i.e. 50-60 Hz.). The output can be filtered electronically to remove low frequencies.

The series of current pulses produces a concentration of energy at the point of application, causing rapid cellular dehydration and carbonisation of the tissues (see section 8.1). Since the spark-gap generator utilises an arc between two electrodes, its frequency is imprecise and consequently results are not reproducible. Fulguration finds no application in timed surgery.

4.5 Vacuum-tube apparatus

The invention of the thermionic vacuum tube led to the production of generators with characteristics

far superior to those of the spark-gap.

The most common circuit used valves to amplify a high-frequency signal producing oscillation by returning a part of the output back to the input (positive feedback).

The frequency was determined by a resonance circuit and was stable. High-frequency current generated with one or more oscillators was produced, and combined valve / spark-gap generators used the valve oscillator for cutting and the spark-gap circuit for coagulation, with the possibility of blending the outputs to achieve a mixed effect.

4.6 Transistor apparatus

Modern generators use solid-state electronics. The function of the internal oscillator is the same as that seen in the valve apparatus, but oscillators utilising solid-state com-

ponents can be more precise, reliable and resistant to damage.

The patient circuit can be filtered, enabling a high-frequency waveform to be produced exactly as required and thus making the equipment far safer.

The latest development is the Timed apparatus. The high frequency is generated by a stable circuit and drives a square wave inverter producing a 921 KHz signal.

The current is regulated so as to guarantee the precision, safety and repeatability necessary for timed-surgery.

The power is regulated by varying the output tension; all the other features of the high-frequency current therefore remain unchanged.

Power is indicated in Watts, and only at higher values does a micro-arc occur between the electromaniple and the tissue.

The micro-arc is used in numerous innovative operations. The need for a sophisticated power system stems from the fact that the intrinsic features of the current influence the quality of cutting and coagulation.

4.7 Control of emission

Control over the emission of high-frequency current can be manual, by pedal, or automatic. In microsurgery a foot-pedal control is used to avoid the consequences of hand tremours.

5 TIMEDSURGERY

Timedsurgery (technique for the implementation of measured electrosurgical data) has transformed the hitherto empirical techniques of electrosurgery to produce a standardised reproducible method for many procedures previously considered impossible. Timedsurgery is the most versatile physical technique in dermatological applications and in the aesthetic and surgical fields.

It has been made possible by the creation of an innovatively conceived instrument: the Timed apparatus.

5.1 General principles

The basis of timedsurgery is precise control of all parameters which determine a specific effect of high-frequency current on the living tissue. Power output, expressed in Watts, must remain perfectly constant even during prolonged use.

Emission time is controlled down to one hundredth of second and active electrodes are of standardised dimensions (electromaniples). If the procedure is properly applied, these factors will yield a precise, controlled and predictable effect which can be reproduced by other operators in similar cases (Tab. 5.1).

Tab. 5.1 Parameters that enable the effects of a diathermic emission on tissues to be predetermined.

Stable power output expressed in Watts
Scale of power variability in steps
Controlled emission time expressed in hundredths of a second
Standardised dimensions of electromaniples
Shape of output wave-form appropriate to function

With timedsurgery, the emission time can be precisely controlled, thus allowing the safe and effective use of short high-power emissions and eliminating the risk of collateral tissue damage around the point of application of the electromaniple.

With emissions of high power and short duration, the zone of tissue destruction is well-defined. This is in part due to the high temperatures reached, since there is little time for heat dispersion.

Other factors are the variation in thermal conductivity of the tissue during coagulation and the disper-



Fig. 5.1.1 A high-power lamp burning for a short time (left) uses the same total amount of energy as a lower-power lamp burning for a longer time (right). However, when considering the effects of timed surgery, equal energies do not achieve equal effects on tissue. The brief, high-power, emission (left) is more effective and more selective in its action than the same amount of energy delivered at low power for a longer time (right).

sion of heat by the circulation of body fluids. However, in energy terms, a low power applied for a long time may be equal to a higher power applied for a shorter time (Power · Time = Energy).

The lysive effects of an emission are dependent upon its power, i.e. the rate of delivery of energy (**Fig. 5.1.1**). At high power, short emission times allow effective and controlled microcoagulation and produce precise cuts which are easy to control and do not burn at the edges. With

lower powers, the precisely controlled emission times enable delicate operations to be performed which were formerly considered impossible. In order to produce these effects the emission times must be controlled automatically, as it is impossible to achieve the required degree of precision when the emission is directly controlled by the operator. Automatic control is required for emissions up to 1 second duration. Timedsurgery is being adopted for a rapidly increasing number of purpo-



Fig. 5.2.1 A prolonged emission produces a widespread lesion. The extent of the partially damaged area depends on the power and duration of the emission.

ses and is already used in many specialised medical fields. One of the reasons for its success is the fact that simple operations, even those which have been recently developed, can be reproduced by any user with the aid of the programme data and the detailed descriptions of the procedures found in the medical-scientific literature (book, video, cd-rom, scientific publications).

5.2 Coagulation

The intensity of coagulation caused by diathermic emissions varies gradually from the zone adjacent to the electrode, where complete coagulation occurs, to tissue some distance away, which is unaffected by the process (**Fig. 5.2.1**). Analysis shows that the extent of complete coagulation depends mainly upon the level of power applied, whilst the extent of partially coagulated tissue depends upon both power and duration of the emission. If, therefore, the power, emission time and electrode size are carefully cho-

sen, it is possible to predetermine the type and extent of the lesion produced, and to minimise collateral tissue damage. With high power applied for a short time, the coagulation produced does not spread over a zone significantly larger than the electromaniple used. If the chosen power level and emission time do not produce sufficiently large coagulation, further timed emissions can be used.

The spread of diathermic heat depends upon the electrical conductivity of the tissue. High power causes vaporisation of liquids contained in the tissue, producing rapid dehydration and carbonisation, which greatly reduces conductivity and, therefore, the production of heat. If treatment of a small localised area is required, it is necessary to use a higher power with a shorter emission time. If, on the other hand, propagation of heat over a large area is required, low power for a long duration is necessary. (**Fig. 5.2.2**).

The effect of the electrode dimensions should also be considered. A




Fig. 5.2.2 A brief emission produces a localised lesion without damaging surrounding areas. The extent of the totally damaged area depends mainly on the power used.

small diameter electromaniple (**EM 10**) concentrates power, while a larger diameter electromaniple spreads the same power over a larger area. In order to affect an area larger than the actual dimension of an **EM 15** electromaniple, it is necessary to extend the emission time (see section 36).

5.3 Micro-arc

The power system used in the Timed apparatus does not generate sparks between the electromaniple and the tissue; at a high power and continuous emission it generates a micro-arc.

A high-power pulsed current with an extremely short emission time produces an efficacious superficial effect without heating the deep tissues (timedsurgical resurfacing).

The **EM15** electromaniple is used.

5.4 Cutting

Using a small electrode, a high density of energy is achieved, which produces cutting. The lesion remains localised (see section 8.6). Using an electromaniple with a flexible steel tip (**EM 10**) and a timed or pulsed emission, a cut can be made with hardly any damage to the tissue lateral to the wound. This new method of cutting exerts hardly any pressure on the tissues, while incision with a scalpel blade requires considerable pressure (see section 8.8).

A cut produced in this way can be sutured and will heal rapidly.

6

TIMED APPARATUS

In the following section, the functional characteristics of the Timed apparatus are examined.

The Timed apparatus (**Fig. 6.0.1**) incorporates many interesting features into its construction. It provides a stable high-frequency current which is unaffected by prolonged use or fluctuating mains supply (see section 4.6). The full power may be delivered continuously and the unit is resistant to short-circuiting. The power control has a series of discrete settings, which enables the required power to be selected rapidly.

The Timed TD 50 micropulse has twelve pre-set positions, arrayed in geometric progression (Tab. 6.1), so that each step increases the power by the same ratio (about 1:4).

The set power is shown on the front panel and the emitted power is indicated.

The apparatus may be used in the direct or timed mode.

In the timed mode, the Timed apparatus allows emission time to be set between 1 and 99 hundredths of a second. The increments in emission time are on an arithmetic scale,



Fig. 6.0.1. Timed TD 50 micropulse.

having discrete and equal graduations of 1 hundredth of a second. A safety circuit checks that all circuits are operating correctly and

Tab. 6.1 Power scale of the Timed TD 50 micropulse

Set Value (Watts)	Actual Value (Watts)
1	1.45
2	2.02
3	2.80
4	3.87
5	5.36
7	7.42
10	10.28
14	14.22
20	19.69
27	27.25
38	37.71
50	52.20

alerts the user to any faults which may arise (Tab. 6.2). If any malfunc-

tion occurs which could be harmful to the patient (e.g. if the power control or the time control become unreliable) the emission is inhibited. This is a necessity chiefly when using high power and short times, as human intervention in the case of malfunction is too slow.

In the direct mode, the Timed apparatus can be used as a traditional diathermocautery. In addition to the standard set of electromaniples designed specifically for timed surgery (see sect. 7), the apparatus can be equipped with ordinary electro-surgical maniples.

The power system is the heart of the Timed apparatus; it generates the current.

Different types of current produce different clinical effects. For instance, de-epithelialisation of the skin at 1 Watt using a traditional generator would be unthinkable.

The intrinsic features of the current also influence tissue healing.

The currents generated by the Timed apparatus are specifically designed for use in timed surgery procedures.

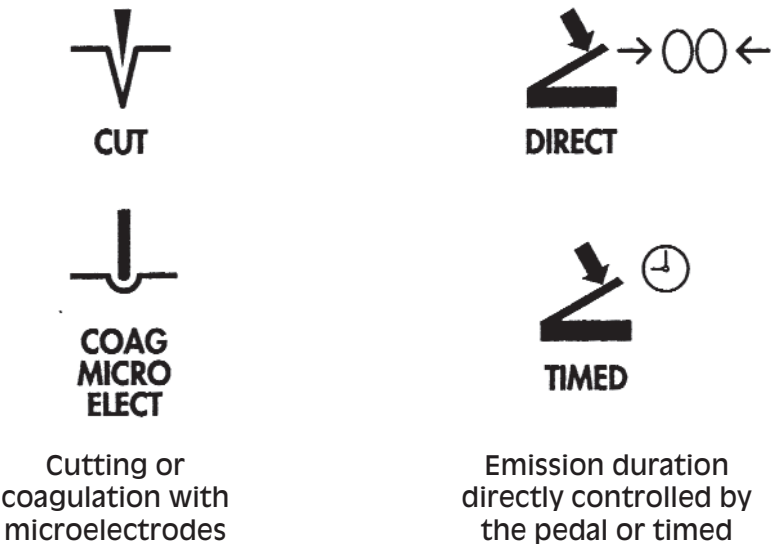
Tab. 6.2 Safety and Monitoring Circuits of the Timed TD 50 micropulse

Machine self-tests when switched on
Internal failure and power indicator *
Alarms for faults in patient return electrode **

* The circuit indicates internal failure and checks that the power generated is that which has been set.

** Timed has a functional - type circuit to control the neutral electrode.

Tab. 6.3- Symbols of the Timed TD 50 micropulse controls



6.1 Pulsed emissions

The Timed TD 50 micropulse can generate 5 types of pulsed current to facilitate specific operations. The pulsed functions are used in the direct mode (Tab. 6.3). The shortest pulsed emission is used

in timed surgical resurfacing and rapid pulsed cutting; one is specifically suited to de-epithelialisation for the repigmentation of vitiligo and for eliminating wrinkles on the eyelids and patches on the hands, while the other pulsed emissions make certain procedures more rapid (Tab. 6.4).

Tab. 6.4 Types of pulsed emission of the Timed TD 50 micropulse apparatus

(1/100s)	Main application
25/67	Epilation
5/29	Telangiectasias, small neoformations
4/9	De-epithelialisation for repigmentation of vitiligo and elimination of wrinkles on the eyelids. Pulsed superficial timed surgical coagulation for patches on the hands.
0.5/24.5	Slow pulsed cutting
0.3/5.3	Timed surgical resurfacing for levelling scars (Cut) and eliminating tattoos (Coag microelectrodes) Rapid pulsed cutting

Tab. 6.5 Principal features of the Timed TD 50 micropulse

High efficiency with solid-state power system *
Insulated floating power system
Discrete power and emission time control
Power scale designed for timed surgery
High-frequency current designed for timed surgery
Output power indicated in Watts
Output short circuit protected (no time limit)
Output protected against short-circuiting
Immune to electromagnetic disturbance
Operating frequency 921 KHz
Coagulation function matched to electrode dimensions
Safety and monitoring circuits (see table 6.2)
Completely enclosed case

* High efficiency in terms of the amount of energy delivered by the machine as high-frequency current compared with its energy consumption from the electrical supply. High efficiency leads to minimum heat production within the apparatus; this is preferable as, even after prolonged use, the apparatus will not become unpleasantly hot to touch. Moreover, as the characteristics of the electrical components are not modified by changes in their temperature, the power output remains stable.

7

ELECTRODES

7.1 Monopolar and bipolar modes

There are two modes of delivering electrosurgical currents: monopolar and bipolar (Tab. 7.1). Monopolar diathermy utilises a small active electrode and a large "neutral" electrode, the patient return electrode (P.R.E.), which remains in contact with the patient's skin.

The shape and dimensions of the active electrode are chosen to suit the procedure being performed. The operator is protected from

electrical contact with the electrode by an insulated hand grip.

In monopolar operation, the current emitted from the active electrode returns to the machine via the P.R.E. This avoids dispersion of the high-frequency current, preventing burns and allowing a constant and reproducible current flow to be obtained (see Fig. 8.5.1). In the bipolar mode, the operator has two active electrodes of equal size (e.g. bipolar forceps); current flows between these electrodes, thereby eliminating the P.R.E. (**Fig. 7.1.1**).

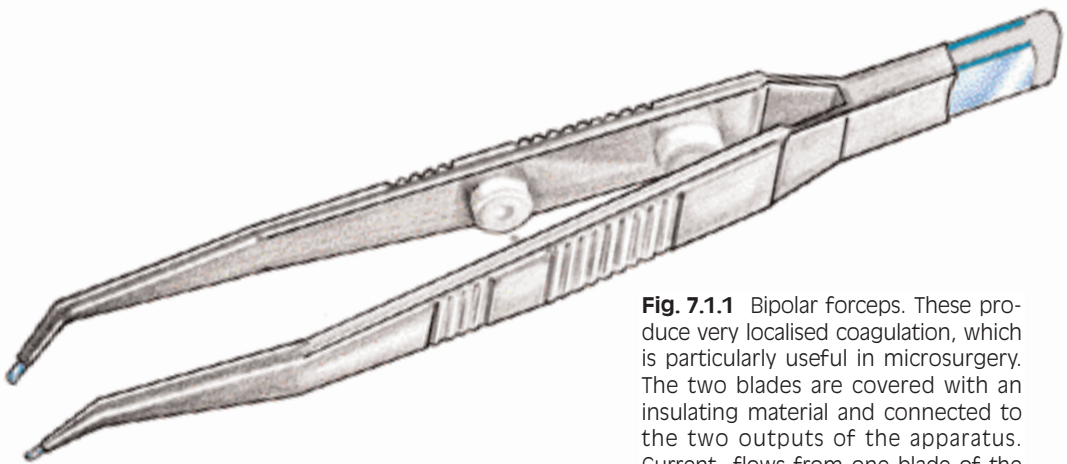


Fig. 7.1.1 Bipolar forceps. These produce very localised coagulation, which is particularly useful in microsurgery. The two blades are covered with an insulating material and connected to the two outputs of the apparatus. Current flows from one blade of the forceps to the other through the intervening tissue, which is coagulated. P.R.E. is not required.

Tab. 7.1 Modes of delivering HF current

Monopolar	1 active electrode 1 return electrode
Bipolar	2 active electrodes (e.g. bipolar forceps)

7.2 Bipolar electrodes

Bipolar electrodes are bipolar forceps, electrodes for the coagulation of nasal turbinates (see fig. 42.0.1), for gynaecology and endoscopy. Bipolar forceps are used in microsurgical and surgical procedures in which it is necessary to produce an extremely precise and localised effect without damaging other delicate structures in the vicinity. The technique is also useful for patients with implanted cardiac pacemakers. Bipolar coagulation is also performed with two **EM 10** electromaniples (see section 18).

7.3 Neutral electrode

The patient return electrode (P.R.E.) or neutral electrode is a metallic plate electrically connected to the unit. It must make good electrical contact with the patient’s skin, preferably as near to the operating site as possible. The relatively large surface area of the plate ensures that the current density flowing through it is low and no physical effect is caused at its site of application. It is possible, however, for burns to occur, especially in anaesthetised patients, if only partial contact is made, thus producing an effect

similar to that of the active electrode (**Fig. 7.3.1**). To prevent such an occurrence, the Timed apparatus has a control system which will signal any potentially hazardous situation and immediately interrupt the emissions. Inside the apparatus, the safety circuit checks that all current emitted from the electromaniple returns to the generator via the P.R.E. If this is not the case, owing to the P.R.E. being disconnected, not in contact with the skin or in partial contact with the skin, an alarm sounds and the emission is instantly stopped. The same happens if the electromaniple touches a metallic object or the skin of a person other than the patient. In timed surgery it is important that the patient return electrode be positioned in the standard way. When working on the back, the P.R.E. may be positioned on the appropriate thigh. When working on the face, it should be applied to the chest and held in place by the patient’s bra or belt. A hand undergoing treatment should be placed on the P.R.E. (**Fig. 7.3.2**). If the patient asks what the P.R.E. is, the operator should explain that it completes the circuit and that the apparatus cannot function without it. For patients under general anaes-

sthetic, an adhesive P.R.E. is normally used, so as to ensure continuity of contact if the patient moves during the operation.

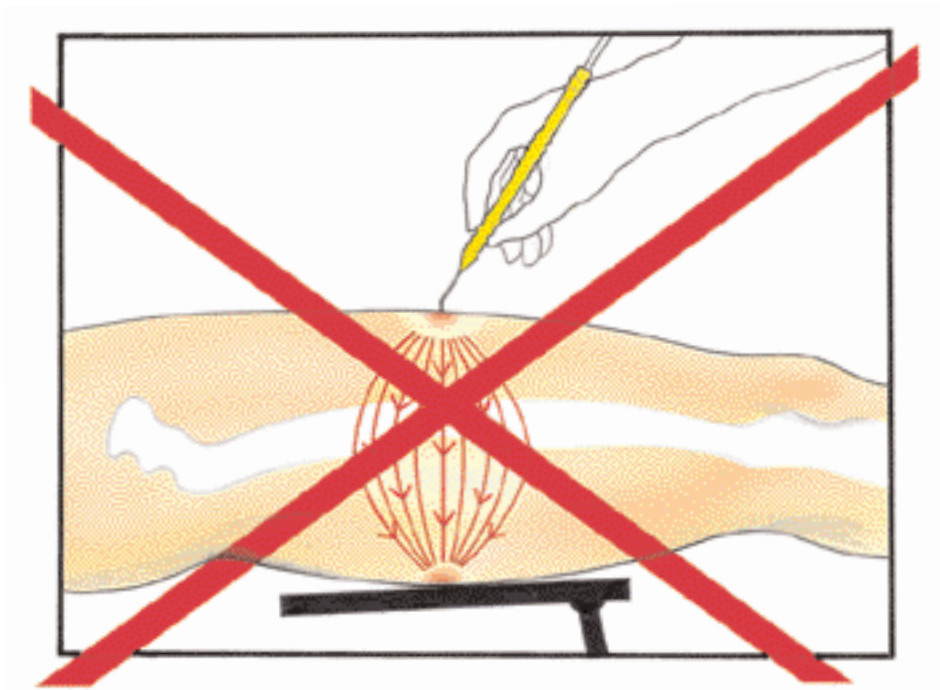


Fig. 7.3.1 The entire surface of the neutral electrode must make good contact with the patient's skin. If contact is partial, the plate may operate as an active electrode and cause a burn. The Timed apparatus has safety systems which monitor return current and interrupt the emission if the return electrode is not functioning correctly.

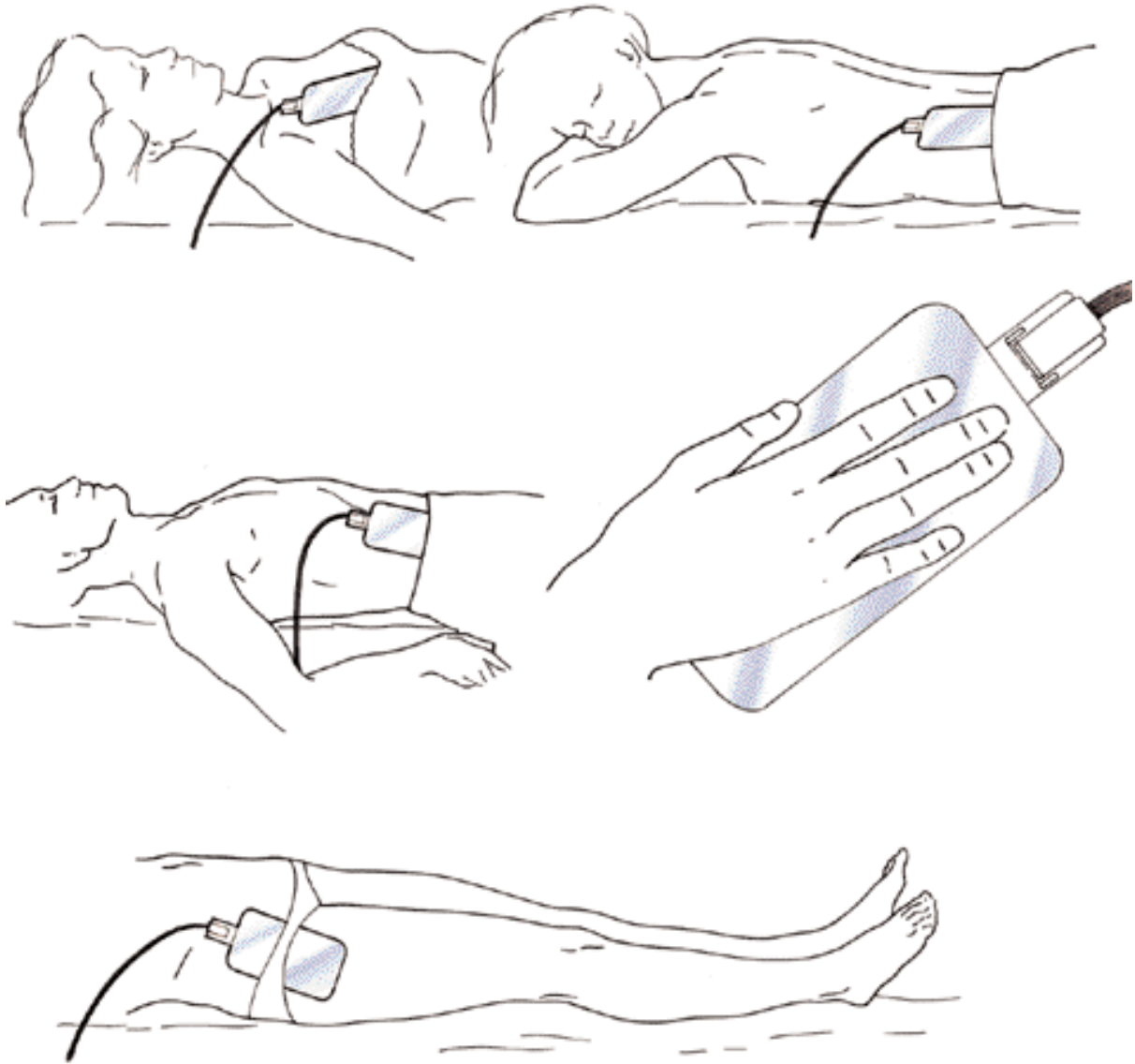


Fig. 7.3.2 The neutral electrode must be in close contact with the skin, near to the site of the operation. In dermatological applications it is held in place by the patient's clothing. A hand undergoing treatment can be rested on the plate.

7.4 Monopolar electrodes

In traditional electrosurgery the active electrode is connected to the handpiece by a simple spring or clip (**Fig. 7.4.1**).

In timed surgery it is an integral part of a manipulator equipped with a rear-mounted connector (electromanipulator).

In outpatient applications the integrated electrode and handpiece has numerous advantages; everything that the operator has handled during the procedure can be sterilised, the size of the electrode is immediately recognisable and electrodes can be replaced quickly.

The electromanipulator is held in the

most convenient way, like a pen for example. Electromanipulators used in dermatological procedures fall into two categories: pointed and smooth.

Loop-shaped electrodes are used exclusively in gynaecological procedures (**Fig. 7.4.2**).

The electromanipulator dimensions affect the emission. The **EM 10** electromanipulator concentrates the power in a small area. The lesion produced is therefore small and requires little energy.

The **EM 15** electromanipulator requires proportionally greater power and produces a larger lesion, but a less intense one, and, in extreme cases, no lesion at all.

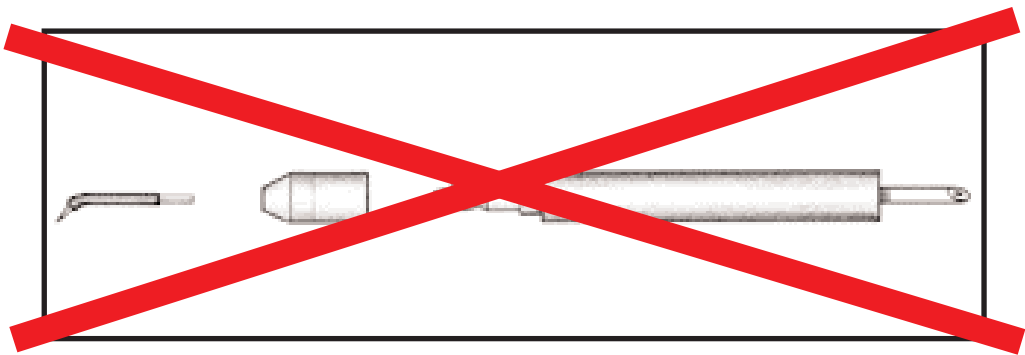


Fig. 7.4.1 Handpiece with mandrel. The electrode is fixed by a screw clip. Substituting one electrode for another is not as easy or as quick as simply selecting a different electrode, as is the case when the electrode is integrated with the handpiece.




Fig. 7.4.2 Pointed, smooth and looped electrodes.

7.5 EM 10 electromaniples

EM 10 electromaniples are equipped with fine conical steel needles; the point of the needle has a triangular section (see Fig. 7.7.1).

The energy delivered by these electrodes is most intense around the point of the needle, over the last 2 or 3 millimetres. Over the remaining surface of the point, where the diameter is greater, current density is lower.

In the skin, the effect of the increasing intensity of current, as the point is approached, is augmented by the varying conductivities that exist in the layers of the skin; the stratum corneum is poorly conductive, whereas the dermis is rich in vessels and, therefore, more conductive. The conical needle can be regarded as a series of cylinders which diminish in diameter as they approach the tip (**Fig. 7.5.1**). The effect of the smallest cylinder is to

enable a lesion to be produced with low energy; when the diameter is larger, the energy is distributed over a larger surface, with the result that, at a low power emission, no lesional effect is produced. In the intermediate cylinders, an intermediate effect is produced; therefore, a varying grade of coagulation is produced along the length of the point.

Cylindrical needles, on the other hand, do not concentrate energy at the point, but distribute it evenly over the surface (**Fig. 7.5.2**). The lesion produced is therefore less intense and less selective. If the emission is of short duration, the conically shaped electrode produces a characteristic lesion in the shape of a water droplet with the broad end at the tip of the electromaniple and the narrow end further up the needle (**Fig. 7.5.3**). A longer emission produces a cylindrical lesion (**Fig. 7.5.4**).

If the emission is long enough and the power high enough, the lesion is largest where the electrode diameter is greatest (**Fig. 7.5.5**) and extends in a manner proportional to the diameter of the electromaniple and the conductivity of the tissue.

One may therefore suppose that the thermal action is only produced very close to the tip of the electromaniple. The last millimetre of the electrode does not need to make direct contact with the point where lesional action is desired.

The penetration of an **EM 10** elec-

tromaniple into the tissues is facilitated by the simultaneous emission of high-frequency current. The extreme tip of a conical electrode, as we have seen, accentuates the characteristic of a sharp needle (**Fig. 7.5.6**).

This phenomenon is already evident at low power, even if it does not produce a cut. Since the larger diameter portions of the electrode prevent sideways slewing, the concentration of energy at the tip of the electromaniple eases penetration into the skin.

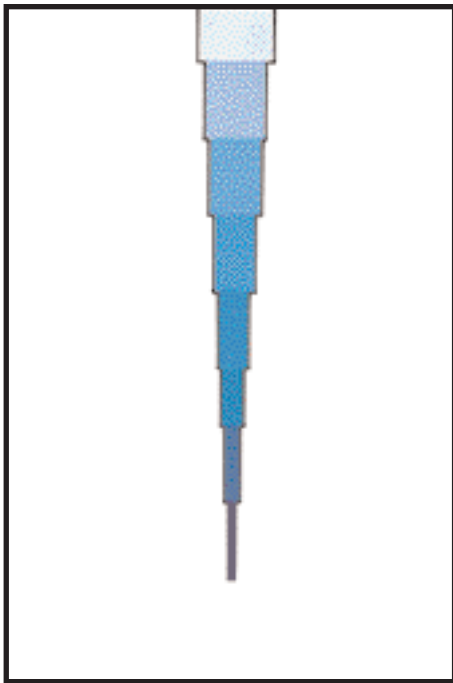

Fig. 7.5.1 A conical point can be regarded as a series of cylindrical electrodes of increasing diameters. At the tip, where the diameter is smallest, the current density, and therefore the lesional effect, is greatest.

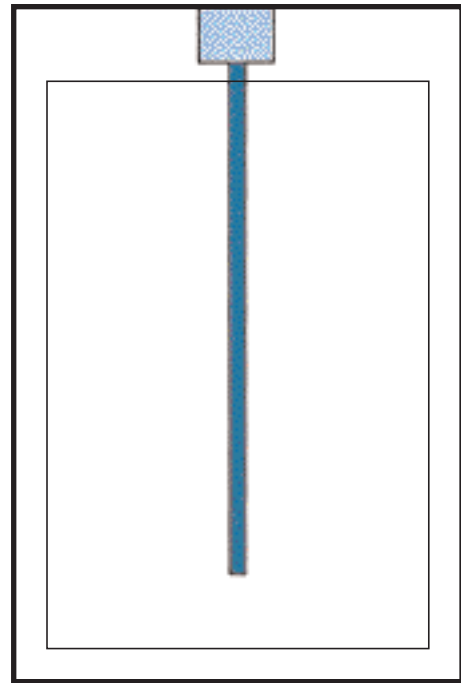


Fig. 7.5.2 A cylindrical needle does not concentrate energy at the point, but distributes it evenly over the whole surface. The lesional effect is not selective.

To penetrate the skin, the operator synchronises the movement of the hand with the timed emission and inserts the electromaniple perpendicularly (see section 15). **EM 10** electromaniples are most frequently used in timed surgery. In dermatological applications, they can be bent for easy use in any anatomical region (**Fig. 7.5.7**). For coagulation, as an alternative to the tip of the electromaniple, the side of a bent

point may be used; with this tiny surface, **1 Watt** de-epithelialisation is carried out, a most delicate and superficial procedure (see section 23).

EM 10 electromaniples are also used for cutting and coagulating cutting. A conical shape is ideal for the cutting function. Blade-shaped electrodes, which have a large surface area, produce a greater tissue lesion and should only be used if such an

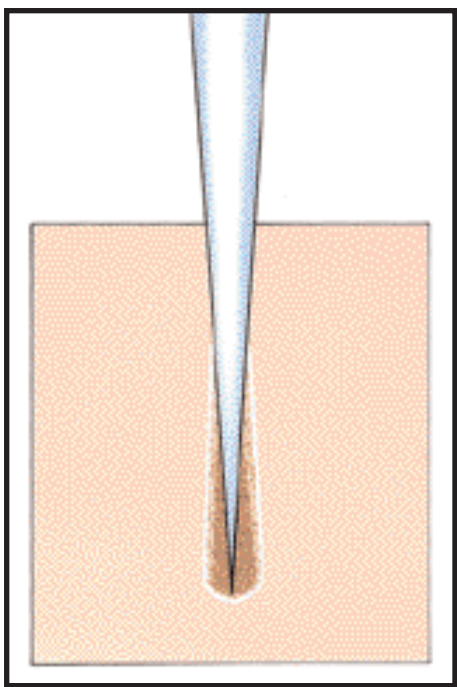


Fig. 7.5.3 An emission of short duration produces a tear-drop shaped lesion.

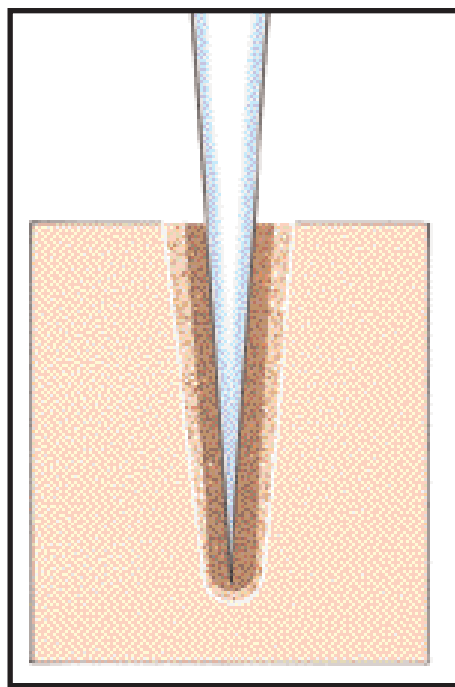


Fig. 7.5.4 A longer emission produces a cylindrical lesion.

effect is required, for example to obtain haemostasis in operations on the parenchymatous organs. If a high-powered current is used for the purpose of coagulation, it should be applied in short bursts; low-powered currents require longer emission times and are used when a greater diffusion of heat is needed within the tissue. Unlike high-powered emissions, low powers do not cause rapid dehydra-

tion and therefore allow good conductivity to be maintained. In surgical procedures, the point of the **EM 10** electromaniple is used as a scalpel.

The electromaniple is held upright and not bent. Points must be frequently cleaned, since organic matter can become attached to them. To clean the needle, a gauze or cloth is used or, on occasion, a fine abrasive paper (P 1000). After use,

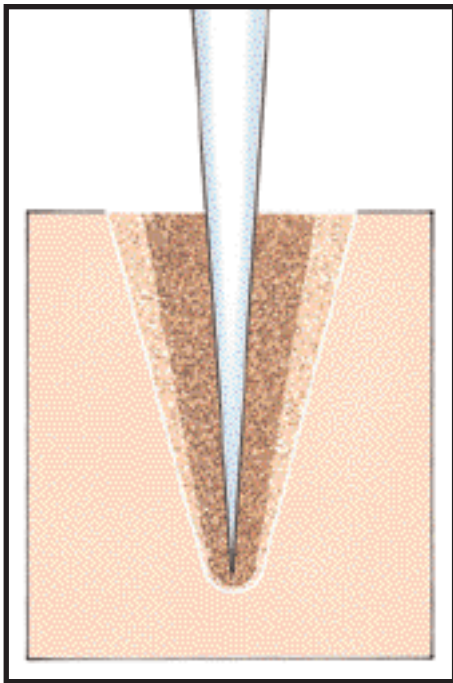


Fig. 7.5.5 If the emission is prolonged, and the power sufficient, a lesion is produced which is most extensive where the diameter of the point of the electromaniple is greatest. The extent of coagulation is dictated by the maintenance of good conductivity of the tissue.




Fig. 7.5.6 The greater density of emission at the tip of a pointed conical electromaniple (represented by a series of cylinders) enables the point to penetrate the tissue easily even at low power emissions.

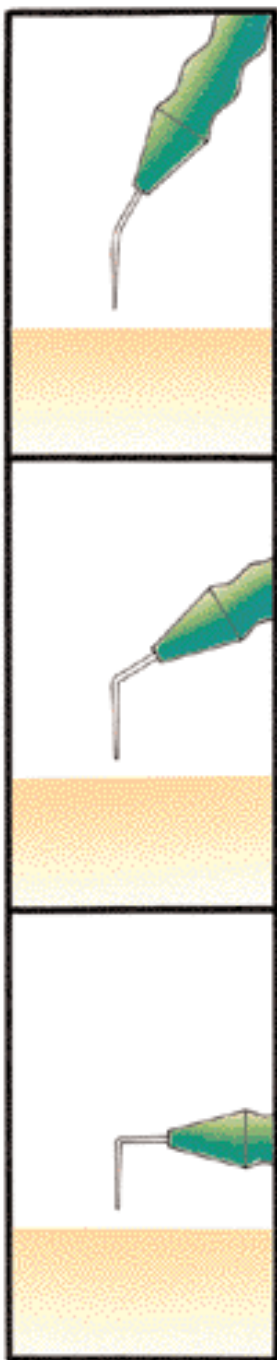


Fig. 7.5.7 For dermatological applications, the **EM 10** electromaniples can be bent to an angle of 90-120°, thus facilitating various procedures

and before sterilisation, all organic material must be removed. An ultrasonic bath is ideal for this, and if the correct solution is used, can also provide sterilisation. When the point of the electromaniple is worn out and tends to bend irregularly in normal use, the electromaniple should be discarded and replaced.

7.6 EM 15 electromaniple

The **EM 15** electromaniple can be used to perform de-epithelialisation over larger areas, peeling at high power, tattoo removal, timed surgical resurfacing, superficial timed surgical coagulation, cleansing of ulcers, coagulation of growths and haemostasis of wounds. The tip and the straight edge of the electrode can both be used according to the procedure (see appendix). To allow proper conductivity, the electromaniple must be kept clean; gauze or abrasive paper (P100) is used for this purpose and cleaning may even have to be carried out during surgery.

When the **EM 15** electromaniple is used for surgical haemostasis, the cylindrical point is held against the tips of the forceps in which the vessel is grasped. In this way, the current is carried to the tissues indirectly (see Fig. 10.3.1)

7.7 Features of electromaniples

Electromaniples are handpieces with the electrode moulded inside. The electrode protrudes from the front of the electrically insulated grip, and a male connector protrudes from the back. In this way the electrode and hand grip can easily be changed between procedures. The electromaniple plugs into an **EA 1** female connection on the end of the high-frequency supply cable. The hand grip is moulded in plastic which can be sterilised by autoclaving or with chemical solutions (but not those which contain oxidising agents or solvents which may attack the plastic). The contour and light weight of the maniple are designed for prolonged use without fatigue. The electromaniples are equipped with points of various sizes.

Tab. 7.3 Electromaniples* EM 10

EM 10 White	0.08 mm diameter
EM 10 Green	0.10 mm diameter
EM 10 Grey	0.15 mm diameter
EM 10 Yellow	0.20 mm diameter
EM 10 Black	0.30 mm diameter

* Korpo s.r.l. Genoa, Italy.

The **EM 10** electromaniples have a conical steel point with a triangular tip. (**Fig. 7.7.1**).

The diameter of the point is indicated by a colour code (**Fig. 7.7.2**) so that the slight differences in size, which are very important in the cli-

nical applications of timed surgery, can be easily distinguished (Tab. 7.3). The **EM 10** electromaniples are short enough to be used under a magnifying lens. In dermatological applications the points can be bent to facilitate various procedures.

PTFE-insulated points are also available; the user cuts away one or two millimetres of insulation from the point before use. The length of electromaniple exposed depends upon the procedure (**Fig. 7.7.3**).

Insulation over the point is useful in bipolar coagulation of spider naevi, in which a prolonged emission time is used. (see section 18).

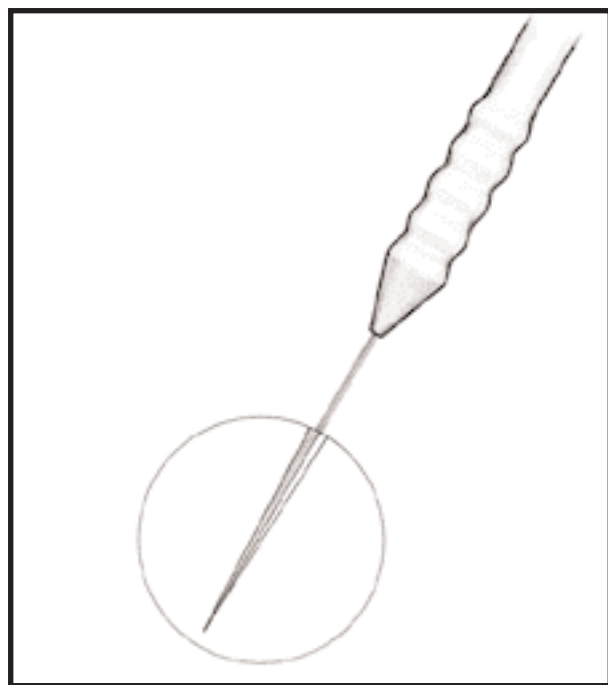


Fig. 7.7.1 EM 10 electromaniple with triangular cross section, permitting easy penetration of the skin.




Fig. 7.7.2 EM 10 electromaniples. The diameter of the points is indicated by colour coding. The use of electromaniples allows the hand grip, which often comes into contact with organic material, to be easily sterilised along with the electrode.

As has already been seen, conical points concentrate energy at the tip, where a tear-drop-shaped lesion is produced (see Fig. 7.4.3). If the emission is prolonged, the area affected by the heat extends along the axis of the electrode and is most evident where the diameter of the electrode is greatest (see Fig. 7.4.5). With insulated electrodes, the thin ($30\ \mu$) insulating layer reduces the passage of current from this part of the electrode. This is particularly noticeable at low power.

A loop-shaped electromanipule can be made by bending the point, although this is rarely used in dermatology (**Fig. 7.7.4**).

The EM 15 electromanipule has a cylindrical steel electrode with a smooth tip of 1.5 mm diameter (**Fig. 7.7.5**).

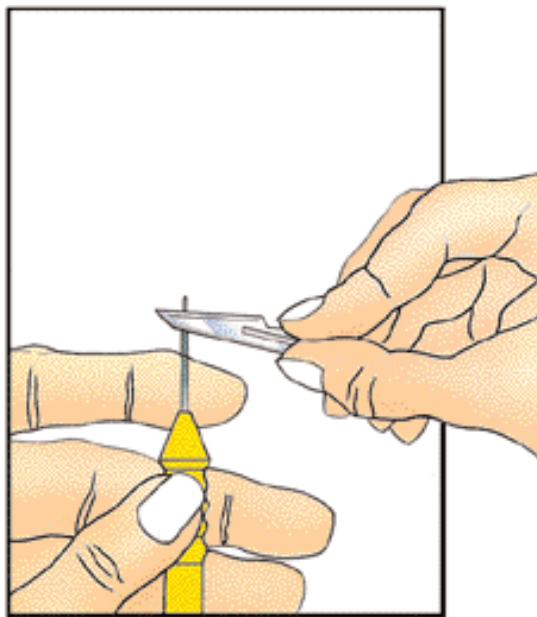


Fig. 7.7.3 Before using the insulated electromaniples, the operator exposes the tip.

This electromaniple, unlike the **EM 10**, does not easily deteriorate during use. The **EM 10** and **EM 15** electromaniples are classified as microelectrodes. Bipolar forceps and the application of current to conventional forceps by touching them with the **EM 15** constitute macroelectrodes (Tab. 7.4).




Fig. 7.7.4 **EM 10** electromaniples may be bent into a looped shape.



Fig. 7.7.5 **EM 15** electromaniple.

Tab. 7.4 Types of electrodes classified according to dimensions

MICROELECTRODES	MACROELECTRODES
EM10 electromaniples	microelectrode + forceps
EM15 electromaniple	bipolar forceps and electrodes
looped electrodes	endoscopic electrodes

Tab. 7.5 Advantages and disadvantages of energy transfer through electromaniples

ADVANTAGES	DISADVANTAGES
Possibility of intervention at various depths	Electromaniples must be sterilized
Possibility of using the tip, side and angle of the electromaniple	Wear of the EM 10 electromaniples
Possibility of using electromaniples of various diameters distinguishable by colour code.	Necessity of cleaning electromaniple during intervention
Easy positioning of electromaniple	
Possibility of generating a bipolar coagulation perfectly localised between two electromaniples in depth, without damage to the skin surface	
Possibility of exploiting the elastic property of the finest EM 10 electromaniples.	
Selective action at the tip (EM 10).	

7.8 Adapting the current to the dimensions of the electrode

A macroelectrode used for haemostasis in a wound requires higher current than a microelectrode used on the skin surface. In highly conductive tissue a higher current is required in order to produce the same effect. Indeed, when the resistance of the tissue is lower, the heating effect is greatly reduced. Furthermore, since a large electrode distributes the current over a larger area, it reduces current density; consequently, the heating effect,

which is determined by current density, is likewise reduced. To achieve coagulation with macroelectrodes, the current must be more than twice that used by microelectrodes. It is important, however, not to confuse greater current with greater power. These two types of coagulation in fact require the same power. When coagulation is carried out with macroelectrodes in a moist area, the current should be greater and the electromotive force less. By contrast, when coagulation is carried out with microelectrodes in a dry area, the current should be

less and the electromotive force greater.

$$\begin{aligned} \text{Resistance} &= \\ \text{Resistivity} \cdot \text{Length} / \text{Area} \\ (\rho &= R \cdot L / A) \quad (1) \end{aligned}$$

$$\begin{aligned} \text{Power} &= \\ \text{Current}^2 \cdot \text{Resistance} \\ (P &= I^2 \cdot R) \quad (2) \end{aligned}$$

Substituting for resistance from equation 1:

$$\begin{aligned} \text{Power} &= \\ \text{Current}^2 \cdot \text{Resistivity} \cdot \text{Length} / \text{Area} \\ (P &= I^2 \cdot \rho = R \cdot L / A) \quad (3) \end{aligned}$$

Where:

P = Power in watts

I = Current in amps

R = Resistance in ohms

ρ = Resistivity in ohm.metres

Considering the smaller cross-sectional areas of microelectrodes, it is clear from equation 3 that if the area is reduced the power will be increased and viceversa (other factors remaining constant).

Tab. 7.6 Coagulation modes

with microelectrodes
less current greater electromotive force poorly conductive field
with macroelectrodes
greater current less electromotive force highly conductive field

Furthermore, if power is reduced by increasing the area, the only way to increase the power is to increase the current. This is shown in table 7.6. The power supplied by the Timed apparatus is designed to produce the correct effect at all times but must be used in conjunction with the appropriate electromanipule. For this reason, the Timed TD 100 unit is equipped with two coagulation settings: one for macroelectrodes operating in moist environments (surgical fields) and one for microelectrodes operating in dry environments (skin and mucosa). (For further explanation of this concept, reference should be made to section 3.3).

7.9 The high-frequency supply cable and electromanipule connector

The **EA 1** connector is sterilisable in an autoclave at 126 °C, or in sterilising solution. It connects the electromaniples to a flexible cable insulated in silicone rubber; this is connected to the Timed unit by a multipolar connector which automatically selects monopolar or bipolar modes of operation.

It is desirable to have several sets of leads and electromaniples, to allow for any delay caused by sterilisation.

7.10 Positioning and testing of cables

The cable connecting the electromaniples to the Timed apparatus must not come into contact with the skin of the patient or other cables; nor must it become

entangled with the P.R.E. cable or trapped under the operating table. In such circumstances the power and/or frequency may be modified. With the Timed apparatus these circumstances are detected and partially corrected by a safety circuit. The user should check the integrity of the cables frequently, as long-

term use can result in damage or breakage, leading to intermittent transmission of current.

The cable can be checked easily by drawing it slowly through the fingers, under traction. If a breakage is encountered, the cable will be found to stretch slightly at this point (**Fig. 7.10.1**).

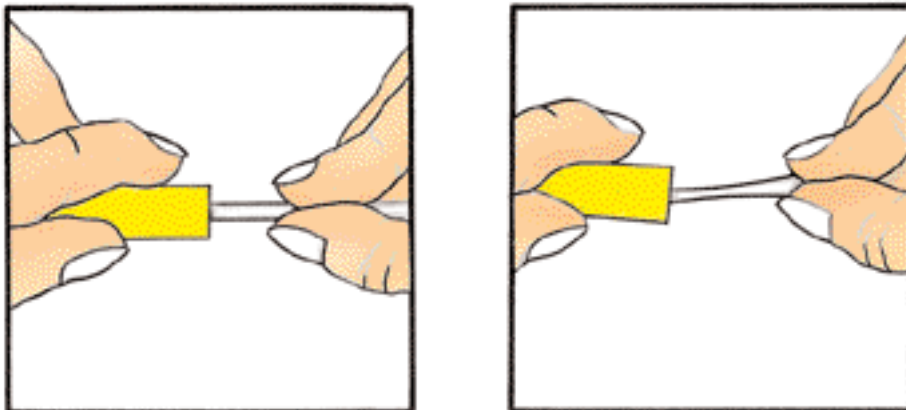


Fig. 7.10.1 To test the cable, pull it slowly through the fingers, applying slight traction. If the cable stretches, the conductor is broken. Such breaks most commonly occur near to the connector and result in total or intermittent failure to transmit current.

8 FUNCTIONS

Timedsurgery has added many new functions to the use of high-frequency alternating current, while some older functions have been abandoned.

Fulguration, for example, has been replaced by the use of the micro-arc.

Ruhmkorff (Roffo, 1935), but the limits of this type of equipment were soon evident.

8.1 Fulguration

Fulguration is the oldest form of application of high-frequency alternating current. The current is usually delivered with a spark-gap apparatus, which produces a very wide band of frequencies with a high initial peak power (see section 4.4). The operator holds the electrode a few millimetres away from the tissue and a spark is produced. The air between the electrode tip and the tissue is ionized, becoming more conductive and allowing the spark to be maintained even when the distance between the tissue and the electrode is slightly increased (**Fig. 8.1.1**). At the point of skin contact there is always some degree of carbonisation. The spark is maintained only while there is sufficient energy to keep the air ionized. The lesional effect and the result obtained by fulguration are always quite superficial, as the carbonisation and dehydration produced act as an insulating barrier. The first medical use of such a technique was in 1891, when Dos Santos treated a cutaneous tumour using a machine made by

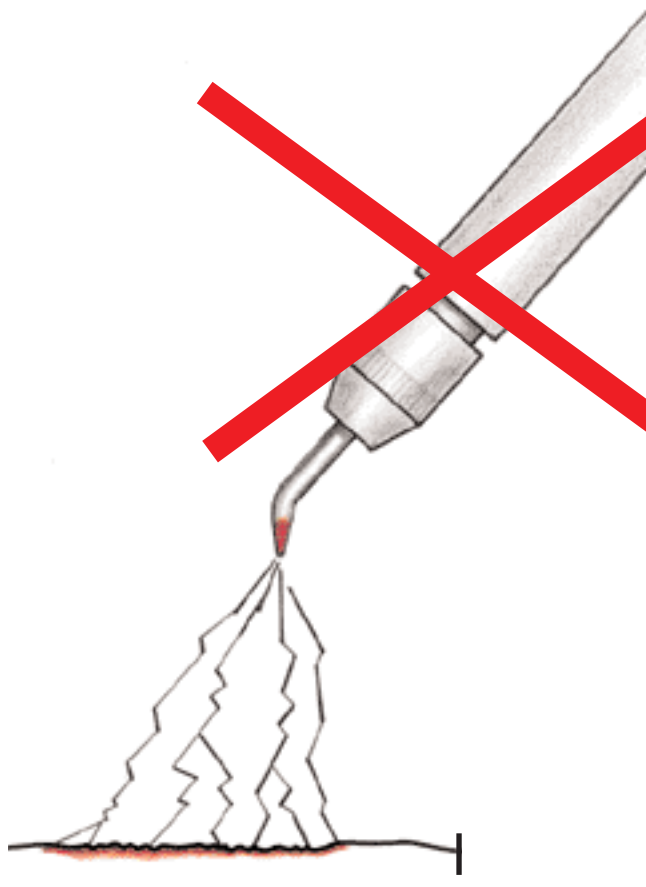

Fig. 8.1.1 Fulguration. The spark is formed in the air gap between the active electrode and the tissue, producing superficial carbonisation. The electrode tip becomes hot enough to glow.

8.2 Micro-arc

Timedsurgery does not use fulguration, but rather a micro-arc, which reaches a temperature of over 1500 °C.

At 50 Watts the micro-arc is used for the treatment of precancerous lesions and for cleaning skin ulcers (see section 50 and 51).

In the **0.3/5.3 hundredths of a second** direct pulsed mode, the technique may be used to remove tattoos and to level the skin (**Fig. 8.2.1**). This function is called timed-surgical resurfacing (see section 23).

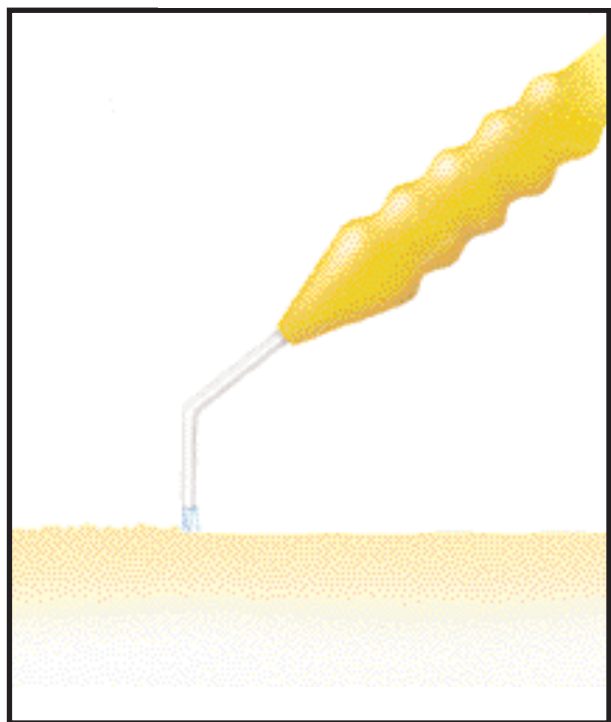


Fig. 8.2.1 Micro-arc. The tip of the **EM 15** electromaniple is brought close to the skin until the micro-arc is generated. In the cutting function, the micro-arc levels scars; in the coagulation with microelectrodes function, it removes tattoos.

8.3 Vaporisation

In vaporisation, as in coagulation, energy is transferred by placing the electromaniple in contact with the tissue. High power emitted for a short time vaporises the tissues owing to the rapid evaporation of the water contained in them. The resulting lesion has well defined edges and heals rapidly (see sect. 35). The degree of tissue destruction is perfectly controllable.

8.4 Coagulation

In coagulation and vaporisation, in contrast to the micro-arc, low energies are used. With coagulation, no spark is generated and carbonisation does not occur (**Fig. 8.4.1**); heat is produced in the tissue by the passage of high-frequency current, and the intensity of the lesional effect can be regulated. The electromaniple remains relatively cool, any heat being due to contact with heated tissues.

While the micro-arc works in areas which are almost completely dehydrated and therefore poorly conductive, coagulation requires good conductivity between the tissues and the electromaniple.

When working on the stratum corneum, which has little conductivity, the power must be increased or conductivity improved by wiping a saline solution over the skin. In a few cases, such as plantar and periungual warts, it may be desirable to remove the cornified layer with a scalpel blade before coagulation (see section 31.2). This also enables the location of the wart to be pin-pointed more accurately.

Coagulation is achieved when a temperature is reached at which the proteins coagulate rapidly and water evaporates slowly. This phenomenon is produced only in the zone where the active electrode comes into contact with the tissue; indeed the development of heat is much greater when the area through which current passes is reduced, and only in proximity to the electromaniple is the heat sufficient to produce a therapeutic lesion. Away from the tip, the current density is low and the heat produced too little to produce any significant tissue damage. If, at low power, the electromaniple makes firm contact with the tissue, an immediate coagulating effect may not be produced. If, on the other hand, the electromaniple is brushed lightly against the tissue, the area of contact is reduced and coagulation will immediately be produced. Coagulated tissues which are not removed or rehydrated become an obstacle to further propagation of current, owing to their poor conductivity.

For coagulation, the high-frequency current is modulated, that is, the current flow is interrupted periodically by the generator (see section 9.1).

Modulation is one of the factors which differentiate cutting from coagulating functions. Another factor is the size of the electromaniple, which is normally small for cutting (**EM 10**) and larger for coagulation (**EM 15**).

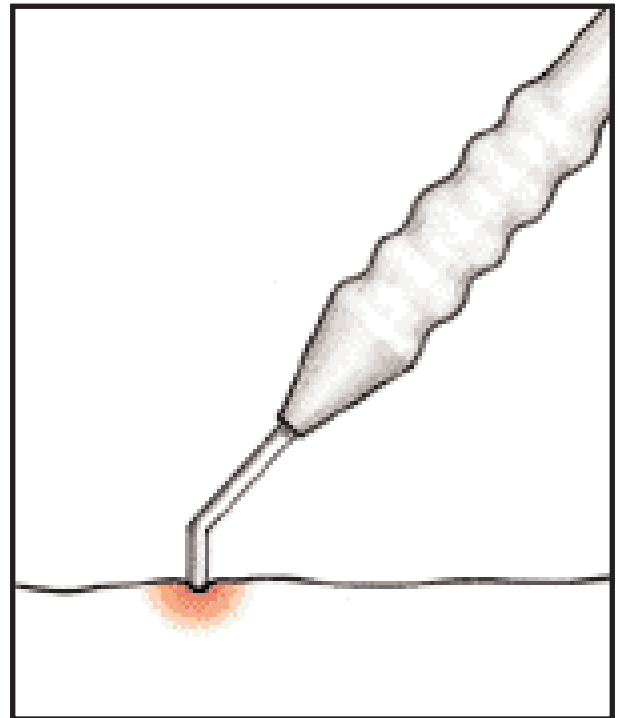


Fig. 8.4.1 Coagulation. Low power are used. The high-frequency current generates heat across the tissues. Energy is transferred by conduction.

8.5 Coagulation with microelectrodes and with macroelectrodes

In order to satisfy the requirements of specific types of timed surgical procedures, two modes of coagulation current have been built into the Timed apparatus (TD 100), one for use with microelectrodes, mainly in procedures on dry tissue, and the other for use with macroelectrodes on moist tissue. These two functions enable the high-frequency current to be adjusted to the correct values. This allows an accurate relationship between emission power, which is indicated on the front panel of the device, and the therapeutic effect. Microelectrodes and macroelectrodes should be used with the appropriate type of current (see section 7.7)

8.6 Monopolar and bipolar coagulation

Coagulation may be monopolar or bipolar. In the first case, an active electrode and P.R.E. are used; in the second, two active electrodes are used, for example bipolar forceps, and the neutral electrode is not required.

In order to visualise the difference in heat propagation produced in monopolar and bipolar coagulation, it is useful to test the effects by coagulating egg white by the two methods; the coagulated parts and differing effects will be clearly seen.

With monopolar coagulation, the high-frequency current flows directly towards the P.R.E. The coagulating effect is greatest near to the electromanipule, where the current density is greatest (**Fig. 8.6.1**). In living tissue,




Fig. 8.6.1 Monopolar emission in egg white. The current flows from the electromanipule towards the P.R.E.

current flows preferentially through vessels and nerves (see section 3.3).

With bipolar coagulation, the current flows through the tissue between the tips of the bipolar forceps, which are connected to the two outputs from the apparatus. The P.R.E. is not used. Coagulation is confined to the area between the tips of the forceps, and there is no current dispersion in the tissues (**Fig. 8.6.2**).

Bipolar coagulation is particularly useful in microsurgery, neurosurgery, or any procedure in which the coagulating effect to achieve haemostasis must be accurately localised owing to the proximity of important anatomical structures. The fact that the patient is not permanently connected to the generator offers greater safety, especially if the patient is connected to other apparatus (e.g. E.C.G.). To produce haemostasis of a vein by means of bipolar forceps, the power required is only a third or a quarter of that needed for monopolar coagulation.

The operator must take care, however, because the extent of coagulation is limited and may be insufficiently rapid to control bleeding. Bipolar coagulation enables haemostasis to be achieved in medium-sized vessels, such as the temporal artery or external jugular; larger vessels should be tied off. As with all types of coagulation, it is important to keep the tips of the forceps clear of organic debris. Any blood that gathers must be removed to prevent current dispersion and loss of effect. Bipolar forceps are macroelectrodes and must be used with the appropriate function. Bipolar coagulation may also be carried out with two separate **EM 10** electromaniples (see section 18.1), or



Fig. 8.6.2 Bipolar emission in egg white. The current produces a coagulating effect, which is confined to the area between the tips of the forceps..

bipolar electrodes (see sections 29 and 41).

8.7 Timed bipolar coagulation

Timed bipolar coagulation is programmed coagulation at high power, with a brief emission time. This permits extremely localised coagulation which is perfectly reproducible (**Fig. 8.7.1**).

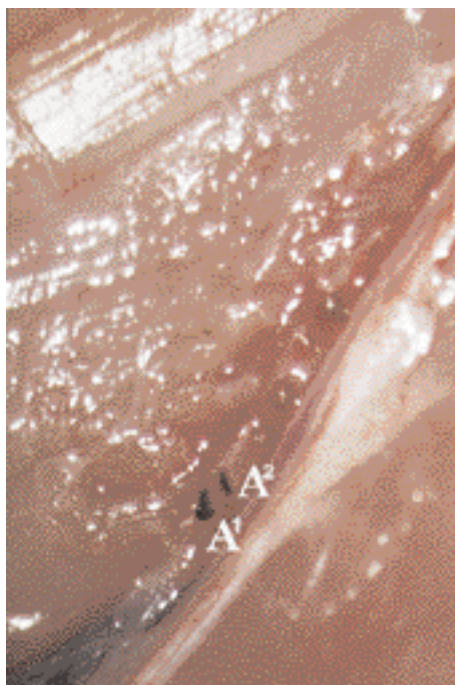
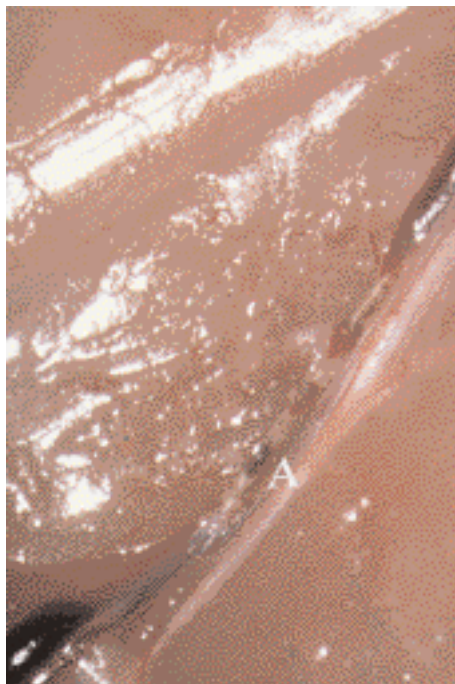


Fig. 8.7.1 Timed bipolar coagulation. High power is used (7 Watts) for a short emission time (20 hundredths of a second). Electrocoaptation (see section 10.2) is extremely localised. The perfect binding of the vein walls opens up new horizons in microsurgery.

8.8 Cutting

Cutting is achieved when the heat developed in proximity to the **EM 10** electromaniple is sufficient to vaporize organic fluids. Two phenomena take place simultaneously.

The heat produced inside the cells creates an internal pressure, which bursts the cell walls and mechanically breaks down the tissue.

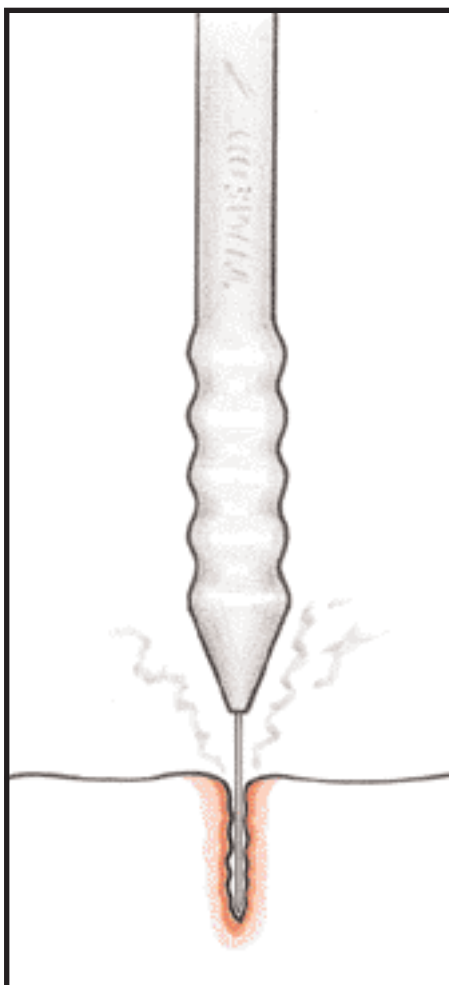
At the point of contact of the electromaniple, where the heat is greatest, a film of vapour forms between the electromaniple and the tissue. Water vapour is insulating and therefore constitutes an obstacle to the passage of electricity. However, because the film is very thin, the passage of current is not prevented altogether and the vapour is partially ionised.

In the vapour film, current density is high and, as the ionised vapour has a lower conductivity than the tissue; greater heat is developed in the vapour film than in the tissues where coagulation occurs.

Once this vaporising process has started, it tends to be maintained, as the high concentration of heat in the small area rapidly brings cells in the immediate vicinity of the electromaniple to the temperature at which vaporisation occurs (**Fig. 8.8.1**).

At the power required to produce a cut, if the current is repeatedly interrupted, the electromaniple returns to direct contact with the tis-

Fig. 8.8.1 Cutting. High power delivered through a fine electromaniple (**EM 10**) concentrates heat and causes rapid vaporisation of intra - and extra - cellular liquid, breaking down the tissues. Around the point, a film of vapour is formed, in which most of the heat is generated.



sue and a layer of dehydrated and partially carbonised, non-conductive material is formed. If the operator does not keep the electromaniple tip clean, the energy concentration may be insufficient to produce a clean cut, and coagulation ensues, as would occur with a large diameter electromaniple.

Blood must be removed from the field of the operation, as it provides a dispersive current path, and makes cutting difficult. In optimum conditions, (i.e. a dry surgical field), the coagulation effect during cutting tends to be negligible as the amount of heat generated within the tissues is relatively small. Current intensity must be sufficient to burst the cells. If the power is too low, the tissues contract and remain in close contact with the

electromaniple, cutting stops and coagulation ensues. If the power is too high, an arc is produced and the edges of the cut blacken owing to carbonisation. In cutting, the current is continuous, unlike coagulating current, and this helps to maintain the vapour film, which would disappear if the current were interrupted. Cuts produced by electrosurgery have both advantages and disadvantages (Tab. 8.1). However, many of the disadvantages are eliminated with timed and pulsed timed surgical cutting (see sections 8.10-11). With traditional electrosurgical cutting, the operator has to be careful to minimise burning at the edges of the cut. To obtain the desired results it is necessary to use a small electrode and a rapid hand movement.

Tab. 8.1 Advantages and disadvantages of traditional electrosurgical cutting

ADVANTAGES	DISADVANTAGES
Designed to cut highly vascularised tissue while achieving haemostasis of venous and lymphatic capillaries	Marginal burns and scar retraction
Ease of cutting hard and fibrosed tissue	Delayed healing of skin and mucosal tissue
Specially-shaped fine electrodes can be used	Difficulty of controlling the cut in micro-intervention
Ideal for cutting infected tissue	Difficulty in regulating cut
Ideal for cutting tumour tissue	Muscular fibrillation *
Little post-operative pain	Increased risk in the presence of inflammable agents
	Bloodless field of operation required.
	Difficulty of cutting low-conductivity tissue
	Burning odour and fumes

* Muscular fibrillation is minimised with the Timed apparatus, which generates frequencies greater than 0.7 MHz appropriately filtered.

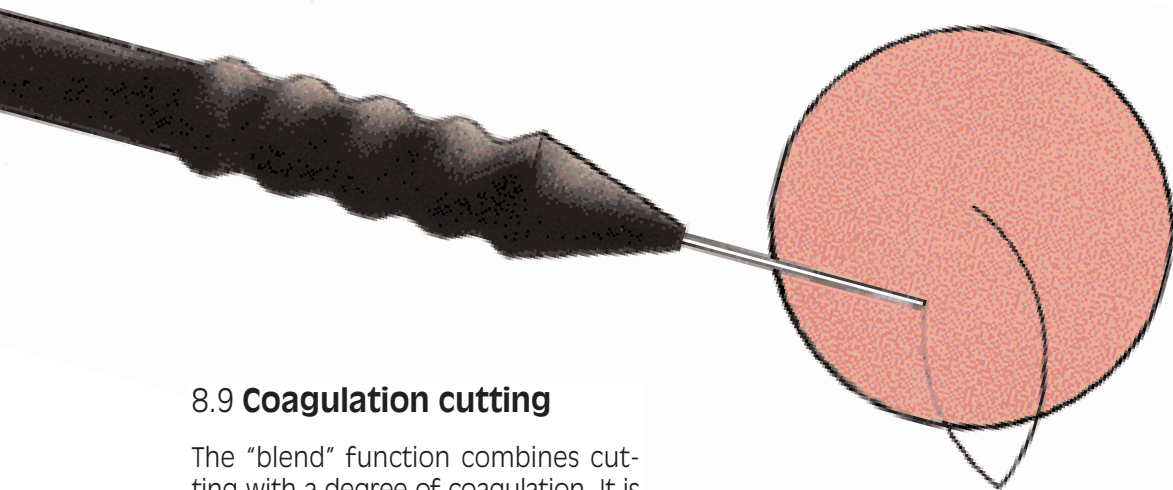
The electrode should not pass over the same point twice without an appropriate delay, as this carries a risk of overheating the tissue and causing necrosis, which in turn promotes infection and retards healing. It is important for the operator to realise that it is not the electrode which cuts, but the high-frequency current. One must never cut the skin with the traditional electrosurgical technique, especially if the cut is to be sutured (Mock 1935). Burns are always produced on the edge of the cut, causing notable delays in recovery (**Fig. 8.8.2**). Healing can commence only when the burnt tissue has been eliminated by the body, and is therefore slow. Consequently, there is a risk of postoperative wound infection and both the functional and aesthetic results are compromised.

Skin cuts can be stitched after timed and pulsed timed surgical cutting, as the edges of the cut produced are not damaged.

Cuts made with this new technique have a healing time equivalent to those created by scalpels (Brunamonti, Capurro, 1986).

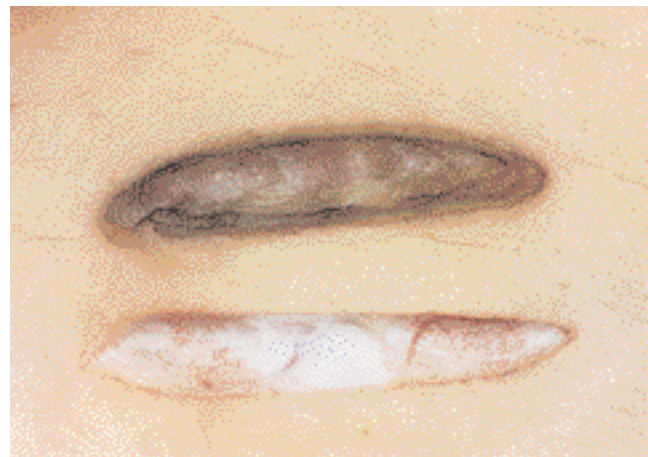

Fig. 8.8.2 Skin cuts. With the traditional electrosurgical cutting technique there is visible burning at the edges of the wound (Top). Using a timed cut, at the same power, with the same electrode, however, there are no burns at the edges of the wound (Bottom).



8.9 Coagulation cutting

The “blend” function combines cutting with a degree of coagulation. It is obtained by introducing regular interruptions in the high-frequency current in rapid succession. In this way, the process of vaporisation is briefly halted. Thus, the current resumes direct contact with the tissue around the electromanipule, the degree of lateral tissue damage is more extensive and there is a greater haemostatic effect compared with that produced by unmodulated cutting current.

The blend function is of value when cutting highly vascularised tissues, in major organs and in biopsies of malignant growths. Unlike incisions made with a scalpel it has the advantage of sealing capillary blood and lymphatic vessels. In biopsy procedures it is common to remove a portion of healthy tissue to allow comparison of the biopsied tissue with normal skin. It is good practice to start the cut in healthy tissue (**Fig. 8.9.1**).

Obviously, it is always preferable to excise the tumour completely and immediately.

The intervention ends with the coagulation of residual substances and complete haemostasis, thus diminishing the risk of spreading tumour cells (**Fig. 8.9.2**).

Fig. 8.9.1 Biopsy of malignant tumours is preferably carried out by means of coagulating cutting (blend). If the excision includes a portion of healthy tissue, this must be removed first.

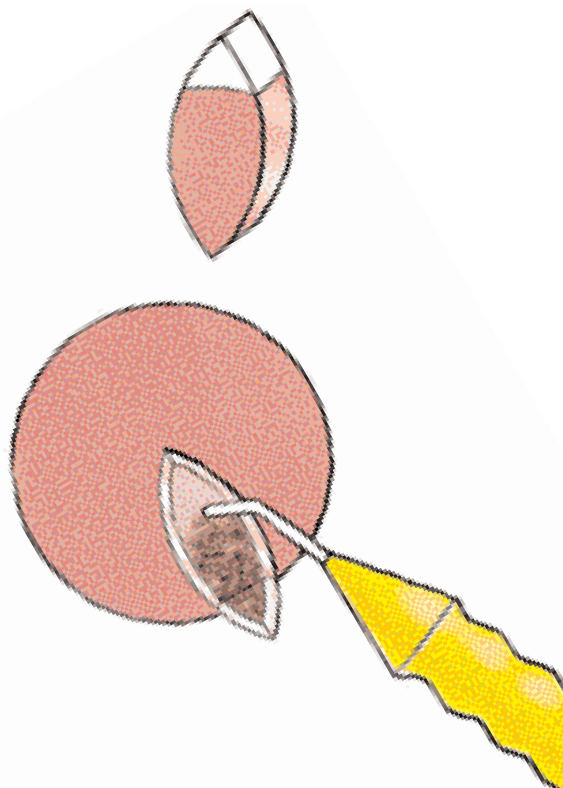


Fig. 8.9.2 After a biopsy is taken, the wound bed can be coagulated.

8.10 Timed cutting

Timed cutting is carried out with high-power current.

It may constitute multiple micro-cuts, with emission times varying between **1 and 3 hundredths of a second**. Cutting is carried out by putting slight pressure on the upright point of an **EM 10 White, Green or Grey** electromaniple (**Fig. 8.10.1**), until it bends slightly and allowing the tension to be relieved during the brief emission (**Fig. 8.10.2-3**).

The high power (20, 27, 38 or 50

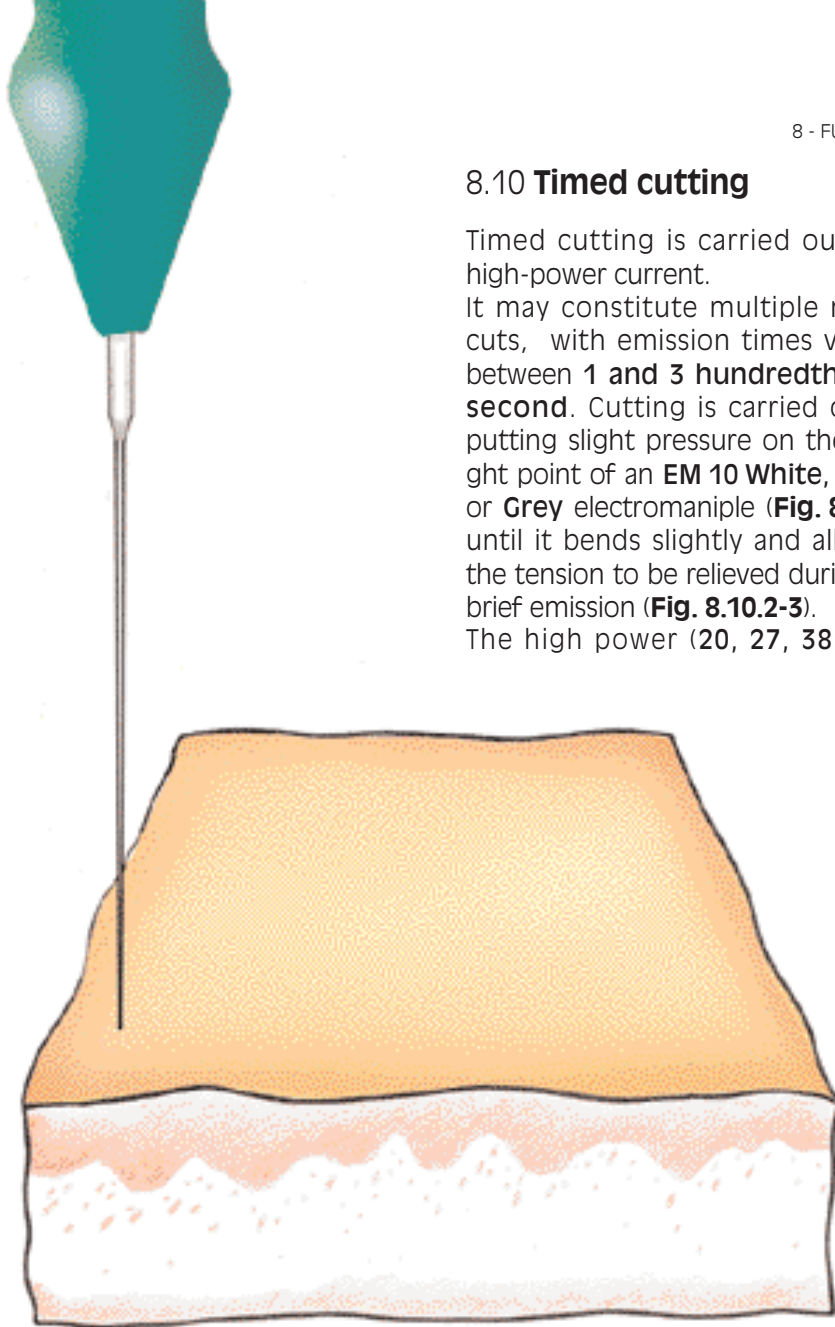


Fig. 8.10.1 Timed cutting is carried out using a point of an **EM 10** electromaniple, which has intrinsic elasticity. The smaller the diameter of the point the finer the cut.

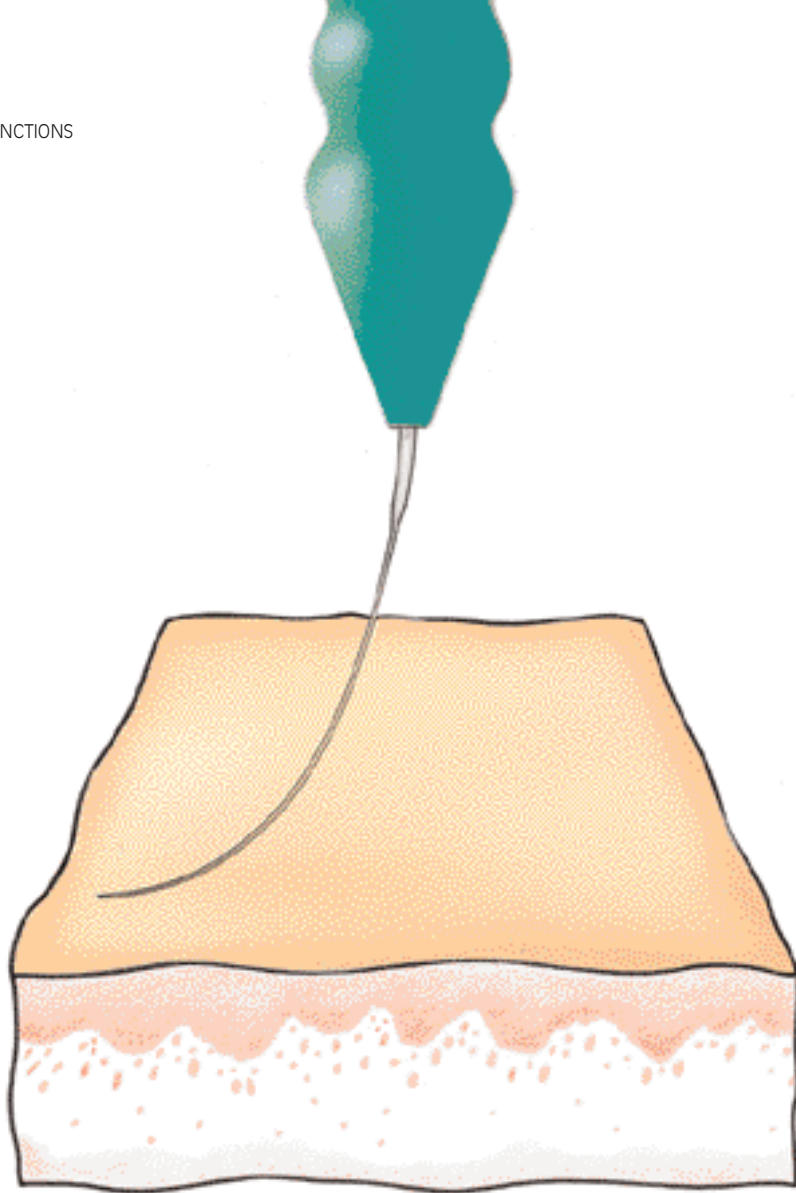


Fig. 8.10.2 The point is put under slight tension in the direction of the cut. The electromaniple is held at an angle of 90° to the line of the incision. The tip points in the opposite direction to the cut. Emission times vary between 1 and 3 hundredths of a second.

Watts) ensures that the tissues offer no resistance to the movement of the distal end of the electromaniple, in which the energy density is concentrated.

The operator must ensure that only the

tapered portion of the point is used for the cut because it is finer and offers a greater elastic traverse force.

Re-applying pressure to the point after it has moved a few millimetres (**Fig. 8.10.4**) and repeating the timed

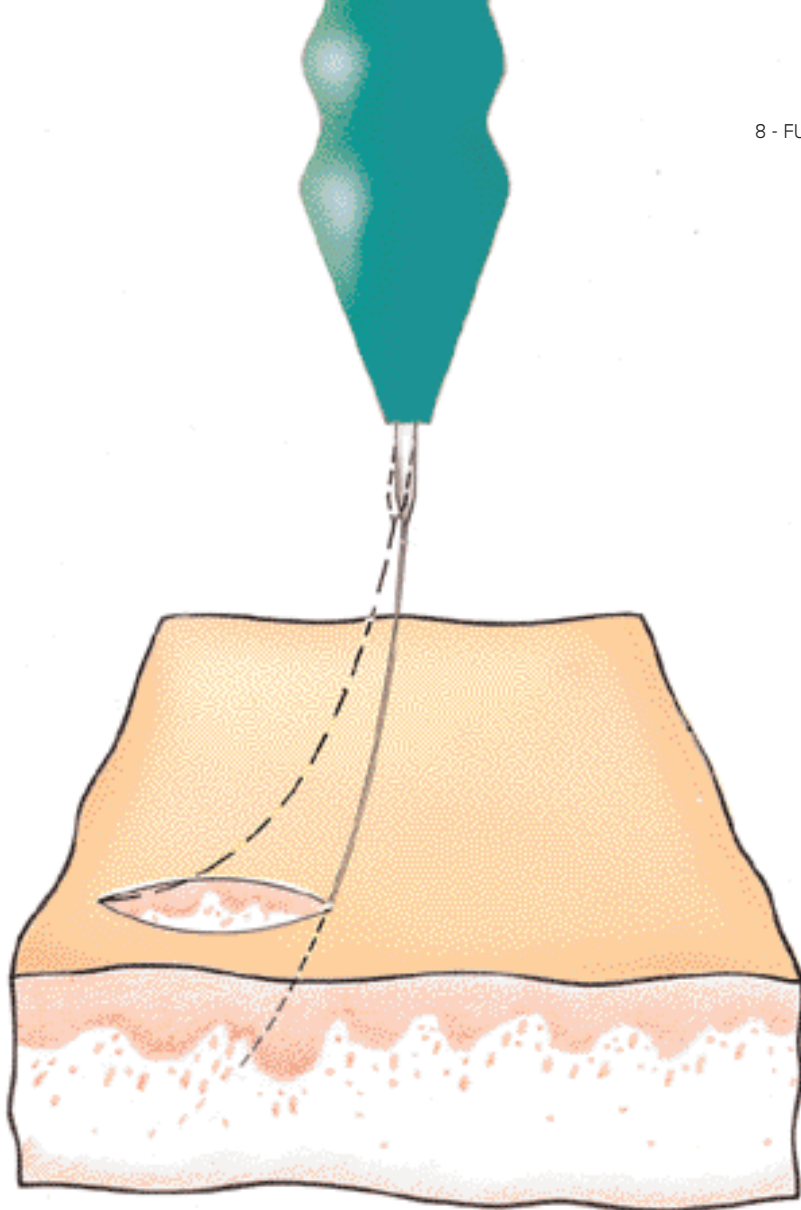


Fig. 8.10.3 During the timed emission, the electromanipule point tends to straighten out, producing a cut with the minimum delay. The length of the cut is regulated by the emission time. The pressure on the tissue is negligible (about 5 gr).

emission produces progression of the cut (**Fig. 8.10.5**).

Shortening the emission time produces a shorter progression of the cut during each emission; in this way, the high degree of precision required for

microsurgical cutting can be achieved. The energy input into the tissues during each programmed cut is sufficient to destroy cells and thus to extend the cut to a predetermined length.

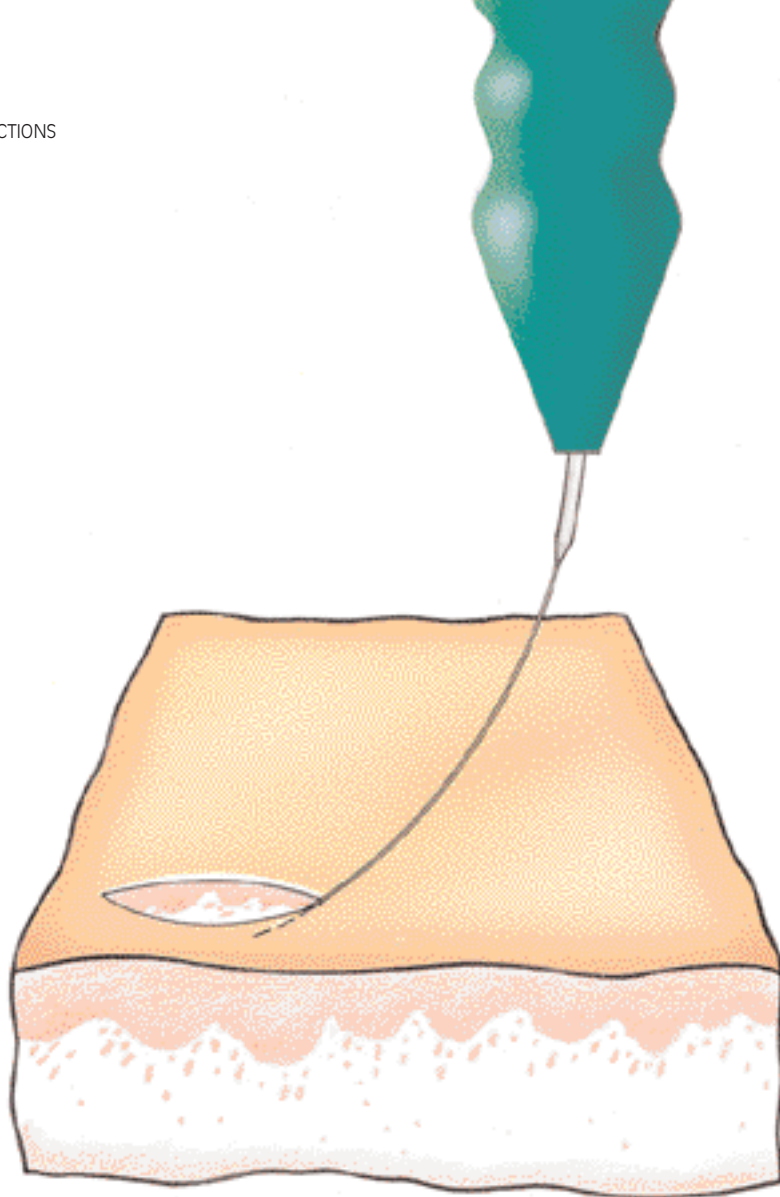


Fig. 8.10.4 The incision is made up of a series of single timed cuts, each one of which is initiated by operating the pedal. The rapid straightening of the needle due to its elastic tension ensures that no burning is produced at the edges, and the wound can be sutured to create a minimal scar.

Burns are not produced in the tissues around the cut owing to the speed of movement of the electromanipule point and the very short duration of single emissions. The total emission time is very short. The absence of

burning allows skin cuts made by this technique to be sutured. These heal in the same time as cuts made with a scalpel and bleed less (see section 42). The use of the finest **EM 10** electro-manipule (White) allows a high concen-

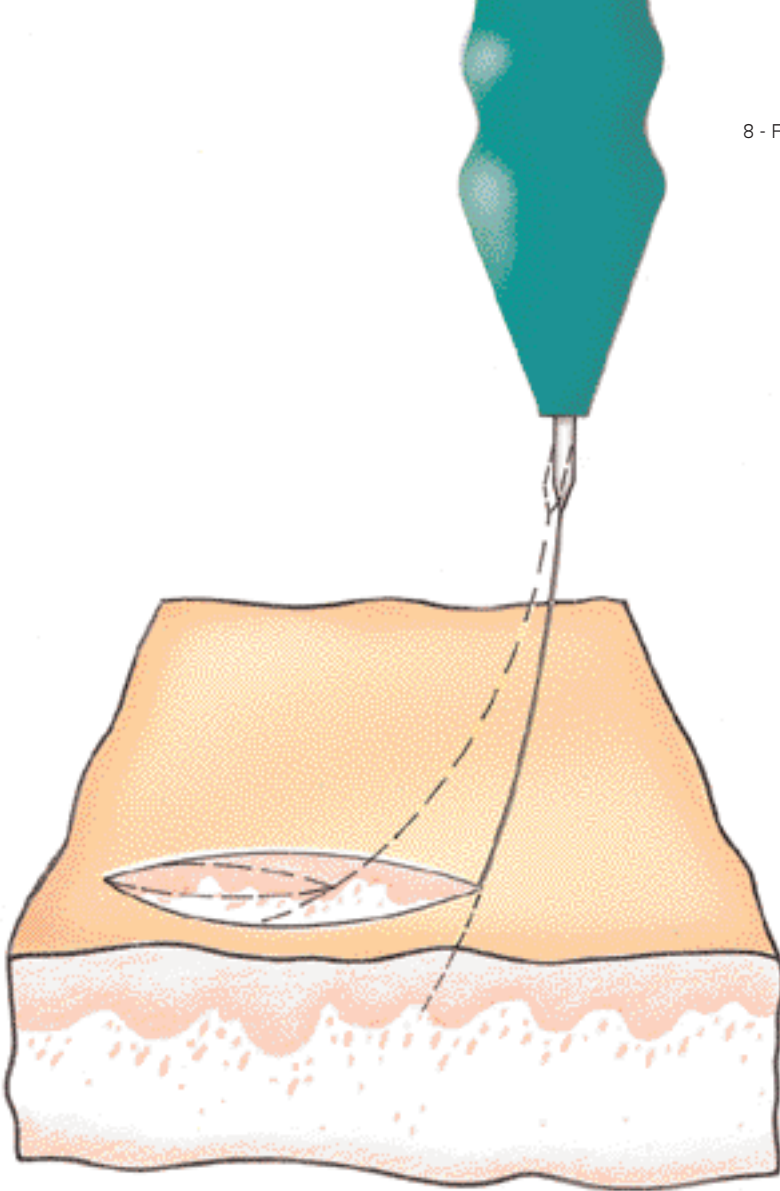


Fig. 8.10.5 The progression of the cut is obtained by moving the electromanipule slightly, applying a slight elastic pressure to it and generating a further timed emission. The shorter the emission time is, the more precise the control of the cut will be.

tration of energy to be achieved with a relatively low power. With timed cutting, the intervention is carried out with the precision and safety of microsurgery. It is possible, for example, to cut out a lozenge between two

lines 1 mm apart (**Fig. 8.10.6**). Small lesions on the surface of the eye can be removed without risk (see Fig. 42.3.4) and recovery is more rapid than after intervention with a scalpel (Capurro 1986).

Timed cutting is used in microsurgery, oral surgery and for excision in all types of malignant cutaneous lesions. In cases of melanoma, our case records suggest that it has a considerable influence on patient survival. In dermatology it is used for "electroshaving" (see section 42.2) and to remove small benign lesions such as fibromas, papillomas and benign moles, without anaesthetic.

In such cases, the lesion is gripped with forceps and pulled away from the skin; it is then excised at the base with the point of an **EM 10** electro-manipule, using one or two timed emissions of **15 hundredths of a second** (see section 42.5).

Timed cutting is extremely easy to carry out, and, once the technique is mastered, the main disadvantages of traditional electrosurgical cutting

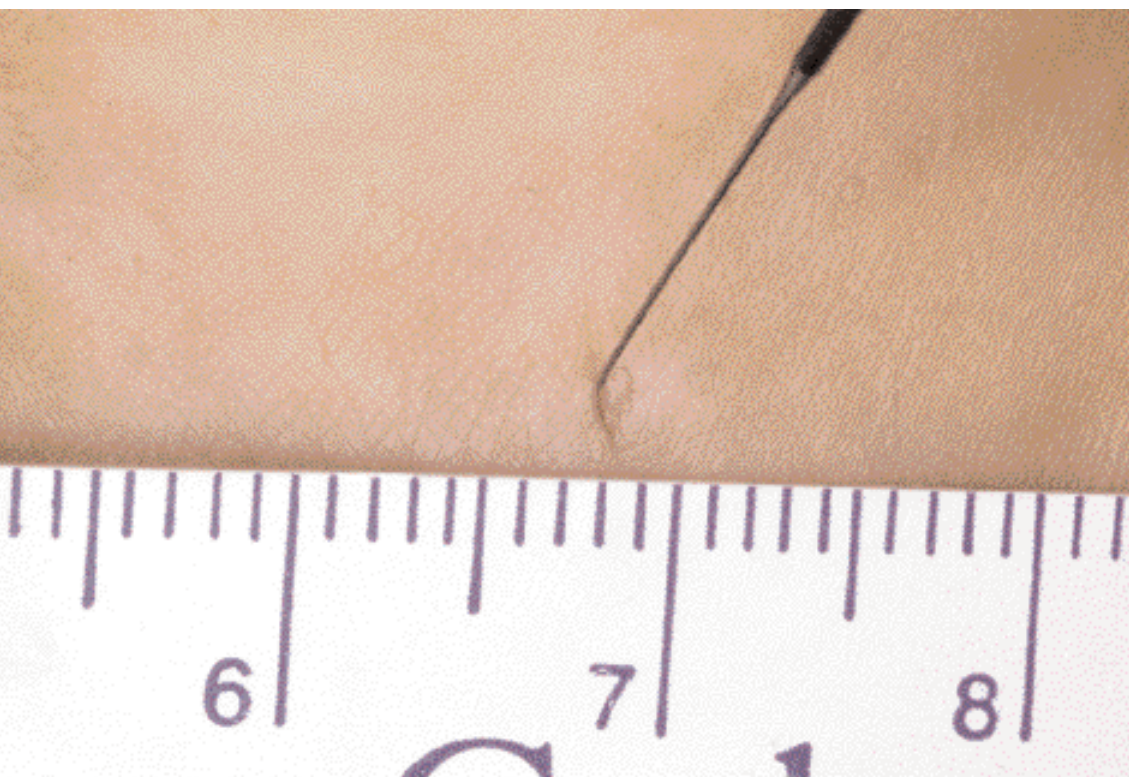


Fig. 8.10.6 With slow timed or pulsed cutting it is possible to cut out a lozenge between two lines 1 mm apart.

are eliminated (Tab. 8.2). Unlike conventional electrosurgery, the **EM 10** electromaniple is positioned in contact with the tissue before the emission is generated.

Delicate procedures can be performed with maximum control and without risk.

Correct programming ensures that the fine tip is not damaged by too high a power. When the point is not

put under slight tension and remains static during the emission, the electromaniple deteriorates more rapidly owing to the greater build-up of heat.

While progression of the cut is determined by the duration of the emission, its depth is determined by the power set (**Fig. 8.10.7**).

With timed cutting no burning of the edges is detectable (**Fig. 8.10.8**).

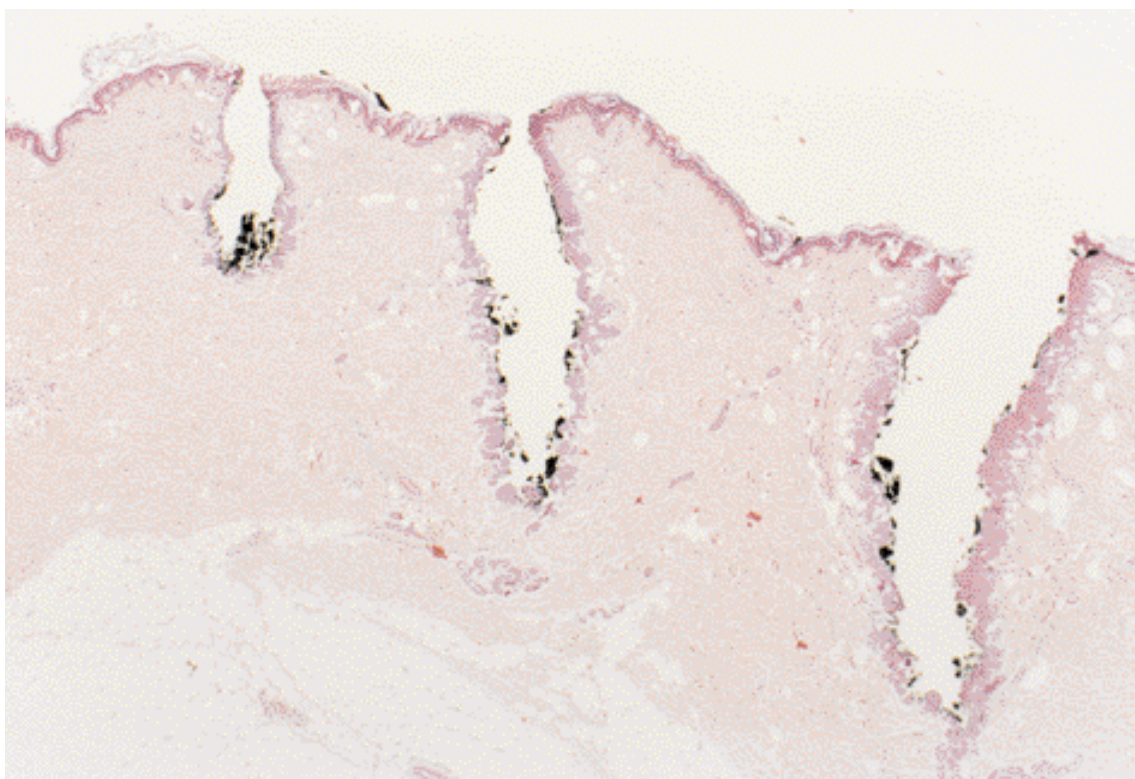


Fig. 8.10.7 The depth of the timed cut is directly proportional to the power used. Programme data: cut, 27, 38 and 50 Watts, 2 hundredths of a second, EM 10 White electromaniple. Applying India ink reveals the perfect continuity of the walls of the cut, an effect which traditional scalpels cannot achieve.

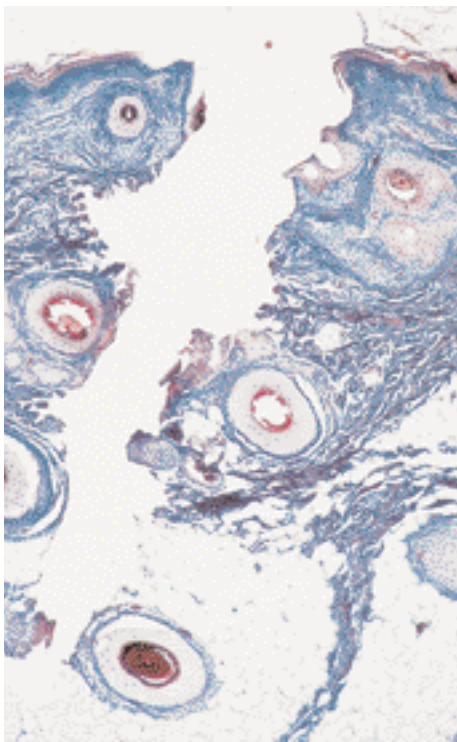


Fig. 8.10.8 Timed cutting. No burning of the edges is detectable. In both edges a fragment of hair follicle cut in half is visible. Programme data: **Cut, 38 Watts, 2 hundredths of a second, EM 10 White** electro-manipule. Temporal region.

8.11 **Timedsurgical pulsed cutting**

In two special pulsed functions, very short timed emissions are generated by keeping the pedal pressed.

Slow pulsed cutting (**direct pulsed 0.5/24.5 hundredths of a second**) facilitates micro-operations. Rapid pulsed cutting (**direct pulsed 0.3/5.3 hundredths of a second**) is used in blepharoplasty and in excising larger neoformations and scars. In such applications, slow pulsed cutting and timed cutting, would be too time-consuming.

The power used on the skin is **27, 38 or 50 Watts**. For subcutaneous and muscle tissues, a power of **50, 72 or 100 Watts** is used.

Tab. 8.2 Advantages of timed and pulsed timedsurgical cutting

Absence of burning at the edges of the wound

Negligible pressure on the tissues

Possibility of producing micro-cuts

Perfect regulation and control of cutting

Excellent visibility

Absence of involuntary lesions

Healing times equal to cuts made with a scalpel

Good quality scar

Possibility of cutting at complex angles

Haemostasis

9

FACTORS RESPONSIBLE FOR CUTTING AND COAGULATING EFFECTS

The factors determining cutting and coagulating effects are the absence or presence of modulation, electro-manipule dimensions and the power used.

9.1 Modulation

Modulation consists of regular and very brief interruption of the current and is carried out automatically by the generator. An uninterrupted high-frequency current (**Fig. 9.1.1**),

if sufficiently powerful, produces a cut. When interrupted, or modulated, a coagulation effect is produced. During each periodical interruption, the vapour film formed at the electromanipule tip cools down, losing heat to the electrode and tissue, and condenses. No more vapour is formed, as vaporisation ceases as soon as current flow ceases, and the electromanipule returns to direct contact with the tissue.

Certain modulations are particularly suitable for surgical haemostasis (**Fig.**




Fig. 9.1.1 Unmodulated high-frequency current. The absence of periodical interruptions produces the cutting effect (**cut**).



Fig. 9.1.2 Modulated high-frequency current for surgical haemostasis and bipolar coagulation (coagulation with macroelectrodes).

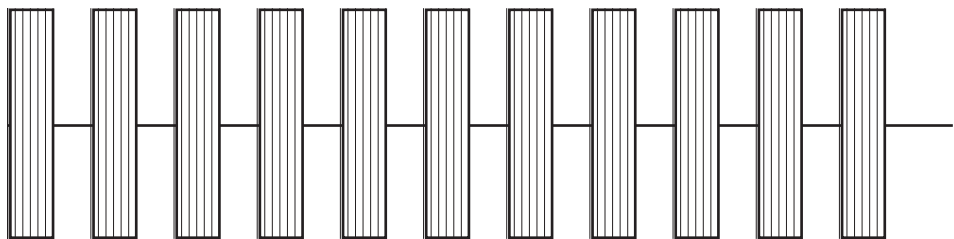


Fig. 9.1.3 Modulated high-frequency current for cutaneous coagulation (coagulation with microelectrodes).

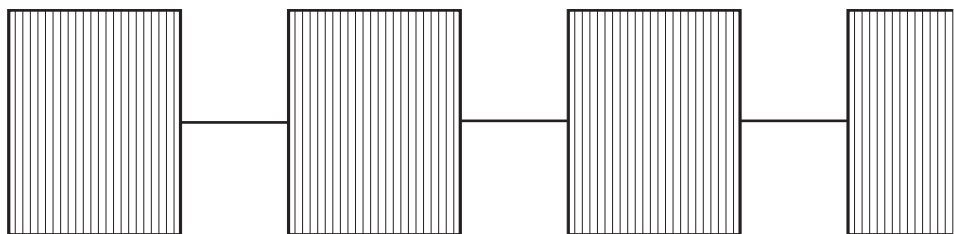


Fig. 9.1.4 Modulated high-frequency current for coagulation cutting (blend).

9.1.2); others are suitable for cutaneous coagulation, in which it is necessary to minimise damage to the tissue in order to obtain the best possible healing (**Fig. 9.1.3**).

The frequency and wave form of the current also have an effect on healing processes. In coagulation cutting (**blend**), the interruptions in the current are very brief and close together, and produce coagulation in the tissue immediately around the electromaniple (**Fig. 9.1.4**).

9.2 Pulsed emissions

Some operations specific to timed-surgery can be carried out by means of periodic interruptions of the modulated or unmodulated emission. Such prolonged interruptions have no effect on the function of cutting and coagulation. The shortest interruptions (a few hundredths of a second) allow the tissues to cool down, and are used in timed surgical resurfacing and in rapid or slow pulsed cutting.

The longest interruptions allow the operator to adjust the position of the electromaniple without having to lift his foot off the pedal. This latter function may be used in slow pulsed cutting, in rapid permanent epilation and in the coagulation of microtelangiectasias.

9.3 Electromaniple dimensions

The dimension of the electromaniple is of great importance because it governs the distribution of heat (Tab. 9.1).

The finer the electromaniple, the more concentrated the power in a small zone.

Tab. 9.1 Diffusion of diathermic action in relation to electromaniple dimensions.

SMALL ELECTROMANIPLES (EM 10)

- ➔ high energy density
- ➔ rapid dehydration of tissue
- ➔ loss of conductivity
- ➔ localised action.

LARGE ELECTROMANIPLE (EM 15)

- ➔ low energy density
 - ➔ slow dehydration of tissue
 - ➔ maintenance of conductivity
 - ➔ diffuse action
-

This effect is particularly marked when an **EM 10** electromaniple is used.

The effect of electromaniple dimensions is demonstrated by the fact that at some powers (e.g. **14 watts**), a cutting effect can be obtained with an **EM 10 White** electromaniple even in the **coagulation with microelectrodes** mode.

When the same power is used with electromaniples of greater dimensions the current is less concentrated and the tissues reach a lower temperature. In such cases, conductivity is maintained for a longer time and a larger lesion is produced.

If an electrode with a large surface area (e.g. blade-shaped) is used in the cutting function, it will produce more evident burning at the edges of the cut and a more marked coagulating effect.

9.4 Power

The temperature reached by the tissues is directly proportional to the power used. If the temperature is very high, vaporisation and carbonisation is produced.

Coagulation requires low power, but this should be in line with the electro-manipule dimensions.

Tab. 9.2 Factors determining coagulation and cutting

COAGULATION EM 15 electromaniple, lower power, modulation
CUTTING EM 10 electromaniples, high power, absence of modulation

A cut is obtained with greater energy density and a fine electromaniple **EM 10** (Tab. 9.2). In order to avoid current dispersion, the field must be free from blood in both functions.

Arbitrary linear scales for power ouput, as used in conventional electrosurgical machines, have been superseded in timesurgery, in which the emission power is precisely indicated in Watts and selected in discrete steps by the operator, according to the type of procedure (see Tab. 6.1).

10 ELECTROBLITERATION AND ELECTROCOAPTATION

High-frequency current is particularly suited to the coagulation of vascular formations, blood vessels, and lymphatic vessels. This is due to the high conductivity of these tissues, which contain liquids and so create a preferential path for the diffusion of current.

Coagulation is used to seal small and medium-sized vessels, thus shortening operating time. Larger vessels need to be tied with a ligature. Haemostasis with high-frequency current is carried out in two ways: by electrobliteration and electrocoaptation (Sigel 1963).

smaller vessels and capillaries also occurs during cutting or coagulating cutting (blend).

10.1 Electrobliteration

Electrobliteration is used in vessels less than 1 mm in diameter to produce coagulation of the vessel and the tissues around it. The current is applied by touching the vessel with the tip of the **EM 15** electromaniple or the tips of the forceps (**Fig. 10.1.1**). The emission is generated only after the electromaniple has come into contact with the vessel. Electrobliteration causes retraction of the walls and closing of the lumen of the vessel by contraction of the tunica media, tissue coagulation and thrombosis. Electrobliteration of

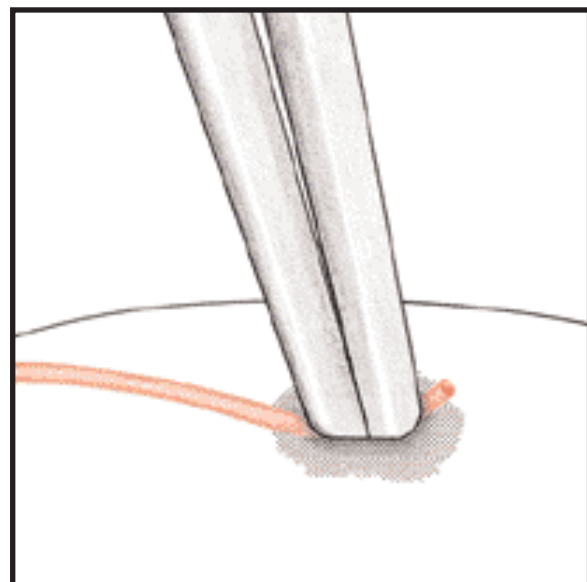


Fig. 10.1.1 Electrobliteration. The small vessels are touched and then coagulated.

10.2 Electrocoaptation

Electrocoaptation consists of clamping the walls of the vessel together with coagulation forceps and then binding them together with current. In this mode the collagen fibres are fused. Mechanical pressure on the joint at the moment of heating is essential for coaptation of the vessel (**Fig. 10.2.1**).

The process requires that power and emission time be well regulated, and is applied for the haemostasis of

medium-sized vessels.

Electrocoaptation may be performed in monopolar or bipolar modes; in the latter case, diathermic action is localised very precisely between the forcep tips (see Fig. 8.6.1).

Coaptation was first described in the 1960's as a method of sealing linear incisions in arteries and veins and of producing venous anastomoses. The success of the technique was, however, limited by the difficulty in transmitting the precise quantity of energy required to obtain coaptation of the vessel.

Insufficient heat produced a poor bond, while excessive heat destroyed the connective fibres and formed an irregular coagulation with an inelastic base, which reduced the strength of the vessel walls, as it tended to fragment and separate from normal tissue. With timed surgery, electrocoaptation preserves the anatomical characteristics of the connective fibres (see section 8.7).

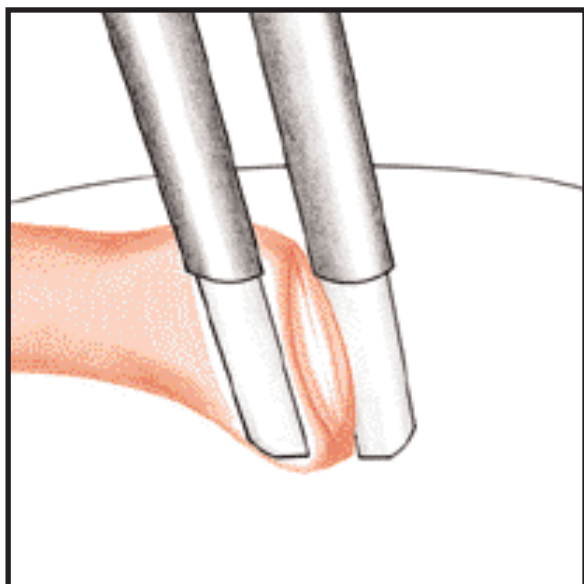
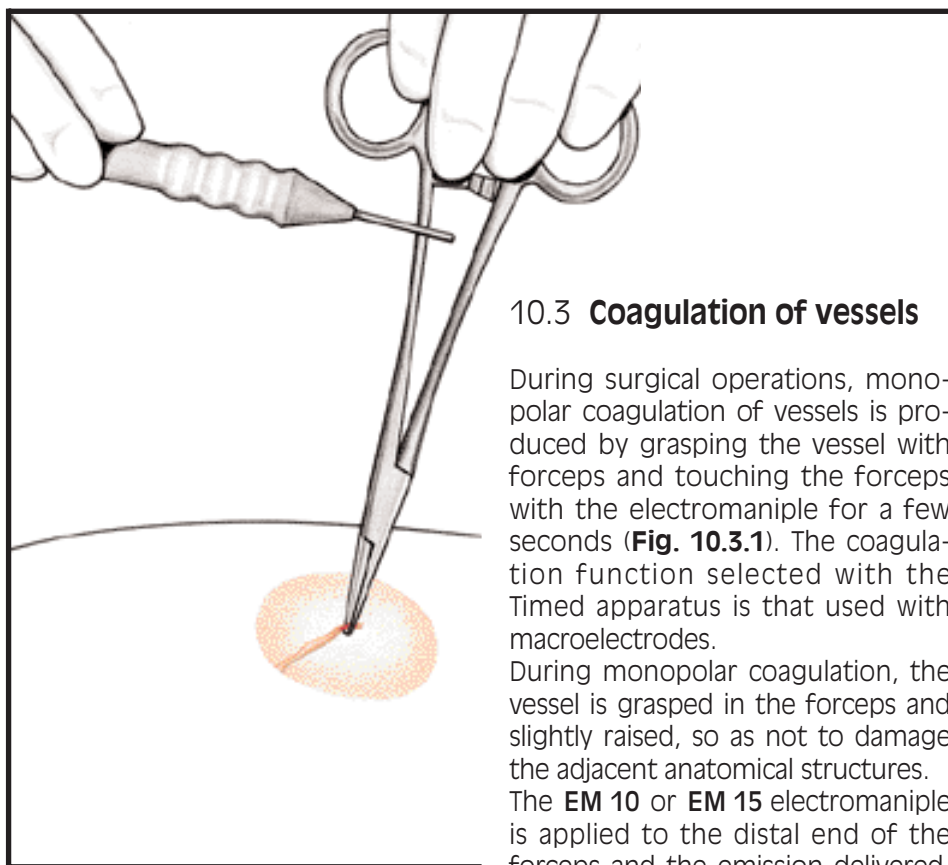


Fig. 10.2.1 Electrocoaptation. The walls of medium-sized vessels are held together and fused by an emission.



10.3 Coagulation of vessels

During surgical operations, monopolar coagulation of vessels is produced by grasping the vessel with forceps and touching the forceps with the electromaniple for a few seconds (**Fig. 10.3.1**). The coagulation function selected with the Timed apparatus is that used with macroelectrodes.

During monopolar coagulation, the vessel is grasped in the forceps and slightly raised, so as not to damage the adjacent anatomical structures.

The **EM 10** or **EM 15** electromaniple is applied to the distal end of the forceps and the emission delivered. Before coagulation, it is necessary to dry the area with a gauze or suction equipment so as to avoid unwanted current dispersion, which would impede the coagulating effect. The power required for such coagulation during normal procedures is **50** or **72 Watts** according to the size of the forceps: the smaller they are, the less power is required. The power must not be too high or contact time too long; otherwise, extensive tissue necrosis will be caused, which increases the risk of infection. Furthermore, carbonised and necrotic tissue is crumbly and subject to postoperative bleeding. Too high a power results not in coagulation but in the immediate vaporisation of the liquid contained in the tissue; even greater powers may trigger an arc,

Fig. 10.3.1 Intraoperative haemostasis. The electromaniple transmits current to the haemostatic forceps and produce coagulation of the vessel (electrocoaptation). The function selected is **coagulation with macroelectrodes**.

causing carbonisation. In order to avoid retarding skin healing, care must be taken to ensure that the skin is not touched with the forceps during emission of high-frequency current. If this does happen, the burned skin must be cut away prior to closing the wound.

Another mode used often in dermatological procedures consists of touching the bleeding vessel with an **EM 15** electromaniple maintaining a power of **20 or 27 Watts**, using **coagulation with microelectrodes**. Again, it is necessary to keep the field of operation dry.

11

PRACTISING TIMEDSURGICAL TECHNIQUES

For most common procedures, timed surgery programme data will allow the operator to immediately implement standardised methods on the patient. Electrical conductivity varies very little from patient to patient and this fact guarantees optimum results by using programme data given in the description of each procedure.

Those who have no experience may practise on vegetables or a piece of meat at room temperature (Tab. 11.1). Those who are already familiar with most aspects of electrosurgery need only practise timed and pulsed cutting, which requires a little practice in order to achieve proper control of the electromaniple. Timedsurgical resurfacing and de-epithelialisation of large surfaces of the skin are performed with the **EM 15** electromaniple.

11.1 Coagulation exercises

Start with coagulation with micro-electrodes, in the direct mode with emission time controlled directly by operating the pedal. Using an **EM 15** electromaniple and a high power (**38 Watts**) coagulate the surface of a piece of meat.

Reduce the power (**20 Watts**) and experiment on the surface of an aubergine, simulating the cutaneous de-epithelialisation which is used for

removing large tattoos (see section 27).

If the **EM 15** electromaniple is replaced by an **EM 10 Yellow** electromaniple and the power is reduced to **10 Watts** by setting an emission time of **10 hundredths of a second**, micro-coagulation can be carried out on the fasciae of tendons and muscles.

In this mode it is possible to practise the synchronisation of hand movements with the emission; this is important in numerous applications, such as the treatment of microtelangiectasias. The operator places the electromaniple on the meat, keeping it perpendicular to the surface; he then presses the pedal and, at the same time, rapidly jabs the electromaniple a few millimetres into the meat.

The emission facilitates penetration of the tip of the electromaniple into the tissue.

Increasing the emission time increases penetration, which ceases when the emission ceases.

The required depth is reached by regulating the emission time.

At the extreme tip of the **EM 10** electromaniple the energy density is sufficiently concentrated to produce vaporisation. If power is increased, the zone of high-energy density is expanded and the point is able to cut laterally as well as penetrate (see section 7.4).

With a small electromaniple (**EM 10 White**) and adequate power (**14 Watts**), cutting is obtained even if the Timed apparatus is set to the **coagulation with microelectrodes** mode; this phenomenon fades out as the electromaniple size increases and current density diminishes.

Applying a low power for a prolonged time produces more extensive, less circumscribed coagulation than a high power for a short time.

11.2 Micro-arc exercises

In the direct mode, an **EM 15** electro-maniple is fitted, the function is set to **coagulation with microelectrodes** and the power to **50 Watts**.

Passing the tip of the electromaniple very closely over a piece of meat generates the micro-arc used for the cleansing of cutaneous ulcers (see section 52).

Having set the resurfacing pulsed function (**0.3/5.3 hundredths of a second**) and the cutting fuction (**Cut**), the surface of an orange is smoothed (**Fig. 11.2.1**).

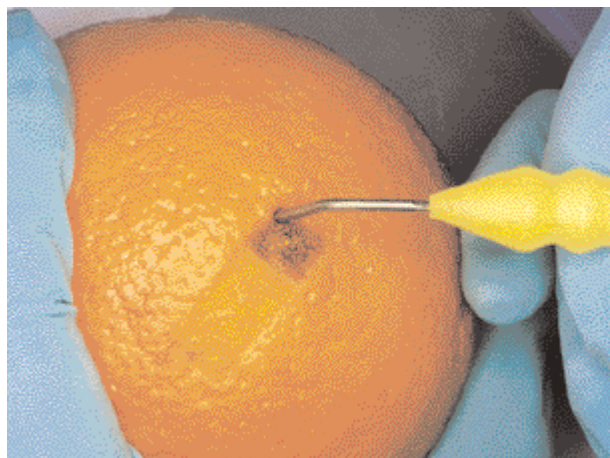


Fig. 11.2.1 Resurfacing exercises.

11.3 Cutting exercises

A cut can be produced in a piece of meat in the direct mode (see section 8.7) by using an **EM 10 Green** electromaniple and high power (**38 Watts**). As the power is reduced, a point is reached when it is no longer able to cut. In this way, the complex nature of the relationship between the electrode, tissue and applied power can be explored. A timed cut (see section 8.10) can be made with emission times of **3 hundredths of a second** or less while maintaining the same power (**38 Watts**) used for non-timed cutting. On comparing the edges of the two cuts, it will be seen that the timed mode does not have as great a lesional effect as the traditional mode (see Fig. 8.8.2). If a series of cuts is produced with **EM 10** electromaniples of different diameters, it will be seen that small variations in diameter (see Tab. 7.3) alter the effect of the timed surgical emission. The smaller the diameter of the electromaniple, the finer the cut will be.

Exercises in timed and pulsed cutting are best carried out on the skin of a banana. To avoid triggering the safety circuit, the banana must be held firmly in contact with the neutral electrode, with the hand.

The Timed apparatus is then set to the direct mode, the emission time control to **00** and the function to slow pulsed cutting, **pulsed 0.5/24.5 hundredths of a second**, or to rapid pulsed cutting, **pulsed 0.3/5.3 hundredths of a second** (Fig. 11.3.1).

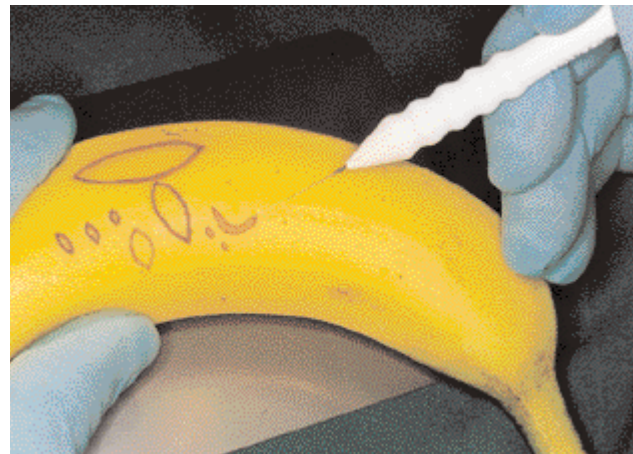






Fig. 11.3.1 Exercises in timed and pulsed cutting.

Tab. 11.1 PRACTICE EXERCISES ⁽¹⁾

	PROGRAMME DATA ¹	COMMENT
 orange	Direct pulsed 0.3/5.3 hundredths of a second - Cut - 50 Watts - EM 15	Practises timed surgical resurfacing used in levelling the skin surface and hypertrophic scars. The tip of the EM 15 electromanipule should pass very closely over the surface of the orange. (In the coag microelectrodes function at 27 or 38 Watts, the technique is used to remove tattoos).
 aubergine	Direct - Coag Microelectrodes - 20 Watts - EM 15	Practises timed surgical de-epithelialisation of large areas. The EM 15 electromanipule must keep moving as it skims the surface. The portion of the point from the tip to the corner is used.
 banana	Timed 2 hundredths of a second or direct pulsed 0.3/5.3 or 0.5/24.5 hundredths of a second - 38 Watts - EM 10 Green	Cutting is carried out at values similar to those used on human skin. This exercise is particularly useful for practising the manual skills required for timed or rapid and slow pulsed timed surgical cutting.
 raw steak	Direct - Coag microelectrodes - 50 Watts - EM 15	The micro-arc technique used in cleansing skin ulcers can be practised on muscle tissue.

1) Fruit and vegetable are whole and at room temperature and must be held firmly onto the neutral electrode.

12 ANAESTHESIA IN TIMEDSURGERY

During the application of timed surgery, an arc may be produced between the electromanipule and the tissues; care must therefore be taken to avoid using inflammable anaesthetic agents, such as ethyl chloride. Local or topical anaesthesia is required in many dermatological and cosmetic treatments.

12.1 Anaesthetic solutions

A 2% lidocaine anaesthetic solution, with or without adrenaline, is most commonly used; adrenaline reduces bleeding and reduces the absorption of the local anaesthetic, prolonging the duration of anaesthesia. Field blocks, ring blocks and nerve blocks are also valuable techniques and are frequently used for procedures on the lower limbs, toes and hand (**Fig. 12.1.1**).

The mild burning sensation felt during injection can be relieved by adding a small amount of sodium bicarbonate to the solution.

Large areas of skin can be anaesthetised by means of the tumescent technique using a dilute anaesthetic solution (Klein 1987).

Guidelines for the administration of local anaesthesia are shown in Tab. 12.1.

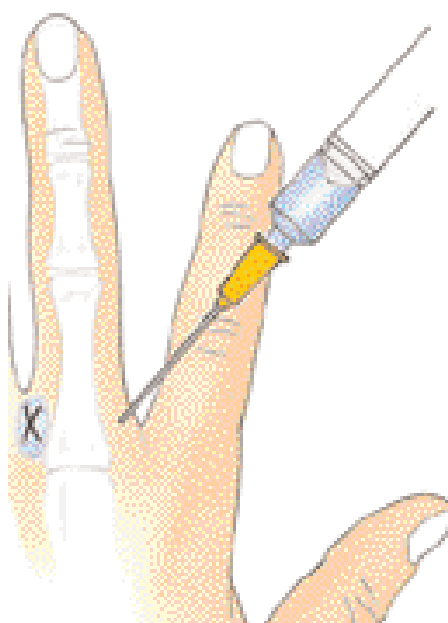

Fig. 12.1.1 Ring block anaesthesia of the finger. 2 ml of 2% lidocaine, without adrenaline, is injected into the base of the proximal phalanx. Anaesthesia occurs within a few minutes.

Tab. 12.1 Rules for loco-regional anaesthesia

- 1) Ask the patient if he has even received a local anaesthetic and whether any adverse reactions occurred.
- 2) Avoid anaesthetic solution containing vasoconstrictive agents if the patient is hypertensive, hyperthyroid or has ventricular arrhythmia.
- 3) Do not inject anaesthetics containing vasoconstrictors into the toes, hand, ear lobe, or foreskin.
- 4) Always operate with the patient lying down.
- 5) Aspirate with the syringe before injection to avoid intravascular injections.
- 6) Inject slowly.
- 7) Do not exceed the doses indicated by the manufacturer.
- 8) Stop administering the agent immediately if there is any toxic reaction.
- 9) Always be prepared for an emergency.

12.2 Topical anaesthetics

Topical anaesthetics such as 4% lidocaine may be use on the mucosa of the nose, mouth, bronchial tree and oesophagus and in the genitourinary tract. Skin may be anaesthetised by applying a mixture of lidocaine and prilocaine (EMLA ®) as a cream under occlusion (**Fig. 12.2.1**). The anaesthesia so produced is relatively superficial but sufficiently long-lasting to be used in several dermatological and cosmetic treatments (Tab. 12.2)

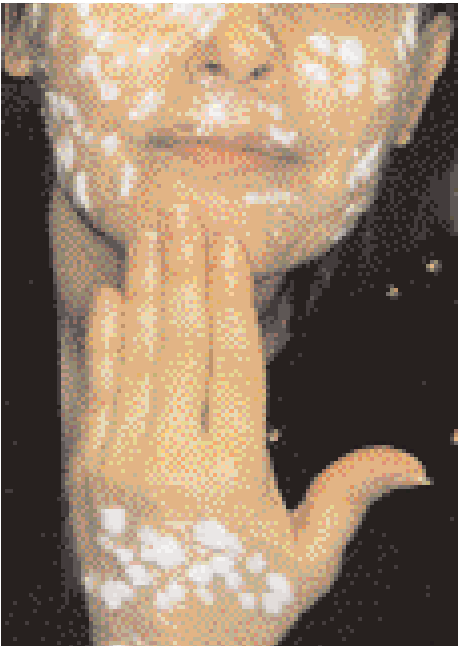

Fig. 12.2.1 Application of anaesthetic cream prior to elimination of hyperpigmentation of the face and hands.

Tab. 12.2 The most common applications of the anaesthetic cream (Emla®)

Epilation
Treatment of facial telangiectasias
Superficial timedsurgical coagulation
Timedsurgical peeling
Timedsurgical de-epithelialisation
Timedsurgical resurfacing

13

GENERAL RULES

13.1 Technical rules

- 1) Keep the Timed unit in a dry ventilated environment.
- 2) Connect the apparatus to an adequate power supply with a proper earth.
- 3) Do not allow active electrode and return electrode leads to become entangled.
- 4) Do not allow the electromanipule cable to come into contact with the patient's skin or metallic objects.
- 5) Position the return electrode securely in contact with the patient's skin.

13.2 Clinical rules

- 1) Do not use inflammable disinfectants or anaesthetics.
- 2) If an anaesthetic solution is used, observe the precautions indicated.
- 3) Do not use timed surgery on patients with an implanted pacemaker. If necessary, consult the patient's cardiologist and use bipolar coagulation.
- 4) Use a bed which will provide support for the back and limbs, on which the patient can lie comfortably, a stool of adjustable height (Fig. 13.2.1) and a variable-position lamp with magnification (Fig. 13.2.2). A comfortable position for the operator and patient will contribute to the correct execution of procedures.



Fig. 13.2.1 A stool of adjustable height allows the operator to choose the most comfortable position.

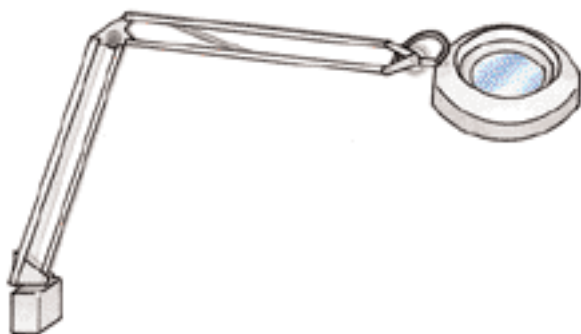

Fig. 13.2.2 An adjustable cold light with magnification. This is indispensable for correct execution of the majority of timed surgical procedures.

5) Disinfect the skin prior to the procedure.

6) Before starting the procedure with timed surgery, it is advisable to operate the equipment so as to check the emission.

7) Stretching the skin with the fingers helps the operator to see the area clearly.

8) Post-operative pain lasts only a few minutes and does not require analgesics.

9) After coagulation of the skin, a crust forms and falls off spontaneously.

10) Prolonged wetting of the treated area must be avoided. The new skin must be protected from the sun.

11) Application of a cold compress reduces inflammation and is especially useful in cosmetic treatments of the face. After the procedure, a specific medication may sometimes need to be applied.

12) After every procedure the electromaniple must be cleaned and sterilised (**Fig. 13.2.3**).

13) In all procedures gloves must be worn.

14) Any blood must be mopped from the field of operation to prevent current dispersion. If, in the presence of blood, the emission is sufficiently powerful to cause boiling and vaporisation, the environment may be contaminated by minute droplets of blood. A mask, goggles and air filter suction device offer protection against fumes.

15) To avoid interruptions during a procedure and maintain sterile conditions, always have a spare active-electrode cable ready, and replace electromaniples when necessary.



Fig. 13.2.3 Ultrasonic bath. Clean cables and electromaniples in a detergent for 15 minutes.

14

ADAPTABILITY OF PROGRAMME DATA

For most timesurgery procedures, the programme data provided in this book are not variable and are applicable to all patients. In a few procedures, however, the operator may need to fine-tune the power and emission time to achieve the desired result.

It is advisable, especially in the first months of use of timesurgery, for the user to keep a record of the data used in the first sitting with each patient for future reference. This saves time in regulating the equipment to the optimum settings. In this way, the operator records the correct programme data and produces a personal case file, which may include photographic documentation of significant cases, obtained with a macro-lens and ring flash (**Fig. 14.0.1**).



Fig. 14.0.1 Documentation of clinical cases should be based on consistent parameters and photographs taken with a macro-lens and ring flash.

In a few cases, such as epilation of the upper lip, it is good practice to operate at the minimum values which allow the hairs to be extracted without resistance. In other cases, such as epilation of the body, it is better to use more power in order to speed up the procedure.

The small programme variations are due to the factors which influence the electrical characteristics of the patient / generator circuit.

Variations in ambient conditions (e.g. temperature, humidity, ionisation of the air) and the physiological or pathological condition of the patient have only a minor effect.

Which electromaniple is used is of great importance. Programme data are not reproducible unless an electromaniple of the same size is used.

This problem has been solved by the use of colour coding of electromaniples (see Tab. 7.3).

Electrical conductivity is very similar among individuals and this has allowed efficacious programme data within a very small range of values to be worked out for every procedure.

At the beginning of each of the following sections describing timed surgical procedures, power values, emission times, function and the colours of the electromaniple are given.

The last pages contain quick-reference tables of programme data for the most common operations.

15 TREATMENT FOR FACIAL TELANGIECTASIA

Facial telangiectasia is a frequent and sometimes serious disfigurement. It is caused by permanent and irreversible dilatation of small veins and capillaries, and may involve the entire cheek, producing a characteristic diffuse red colour; several causes are given in table 15.1.

Traditional methods of treating telangiectasias, such as thermo-coagulation, electrolysis and electro-coagulation, are best avoided because of the risk of producing achromic and atrophic scars.

The fear of creating visible residual scars may prompt the operator to use low power, which is of little efficacy and does not give results.

Laser techniques also have limitations. The colour and texture of the surrounding skin affect the absorption of light energy; the destructive action cannot be achieved in depth, and these techniques are costly.

Moreover, it is very difficult to avoid causing skin depigmentation. Indeed, laser techniques may produce visible scars and often yield varying results from one patient to another, even when the same generator settings are used.

Today, the treatment of choice consists of three-dimensional sclerotherapy with 8% Bisclero followed by timed or pulsed timed surgical treatment.

Tab. 15.1 Causes of facial telangiectasia

-
- A) Family history
 - B) Prolonged exposure to U.V. light
 - C) Trauma and infection of facial skin
 - D) Surgery - e.g. rhinoplasty
 - E) Long-term local treatment with corticosteroids
 - F) High levels of oestrogen
 - G) Emotional
 - H) Rosacea
-

15.1 8% bisclerotherapy

If facial telangiectasias can be injected, two or more sessions of three-dimensional sclerotherapy with 8% Bisclero are undertaken at weekly intervals (**Fig. 15.1.1**). Residual telangiectasias are micro-coagulated by means of timed surgery (**Fig. 15.1.2**). Bisclerotherapy accelerates and stabilises aesthetic results. From 2 to 6 ml of the solution is injected per cheek. This three-dimensional treatment can be undertaken because the solution has only a mild inflammatory effect and may therefore be injected in large doses; if traditional sclerosing solutions were used, necrosis, oedema and pigmentation might ensue. The injection of large amounts of Bisclero involves the vessels that are not visible and considerably reduces the haemodynamic pressure of the superficial telangiectasias.

Highly inflammatory sclerosing solutions must be avoided on account of the anatomical connections between the vasculature of the cheek and the sinuses of the dura mater.

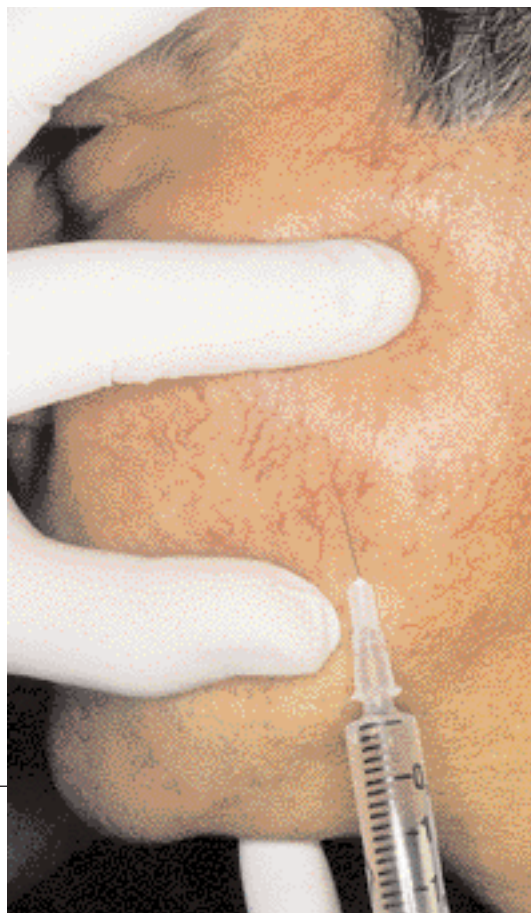
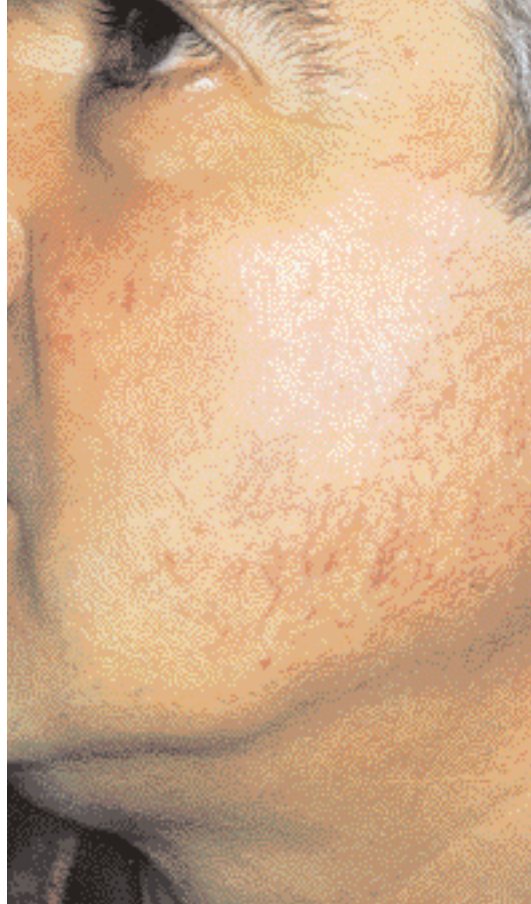
Fig. 15.1.1 Evident telangiectasias of the face (top). During injection of 8% Bisclero, 6 mm of solution is injected (bottom). A very small amount of lidocaine is added to the Bisclero.

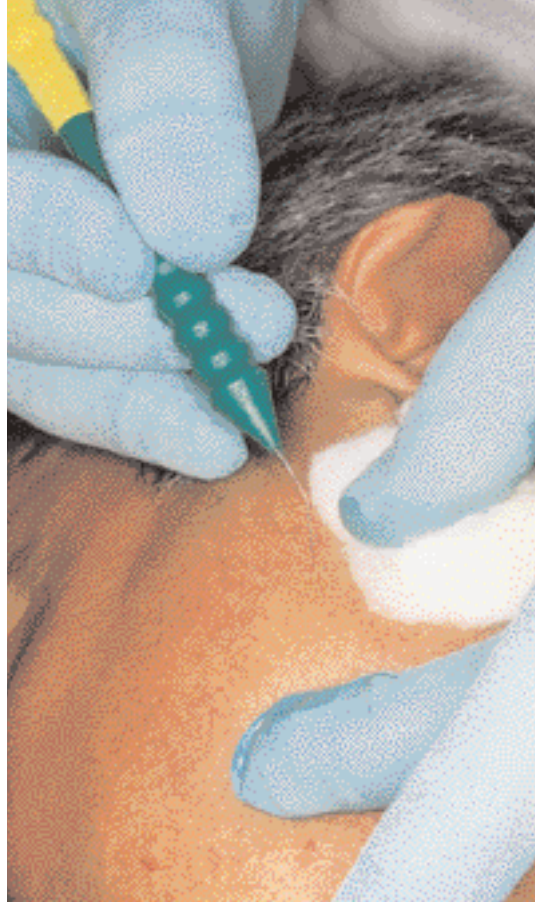
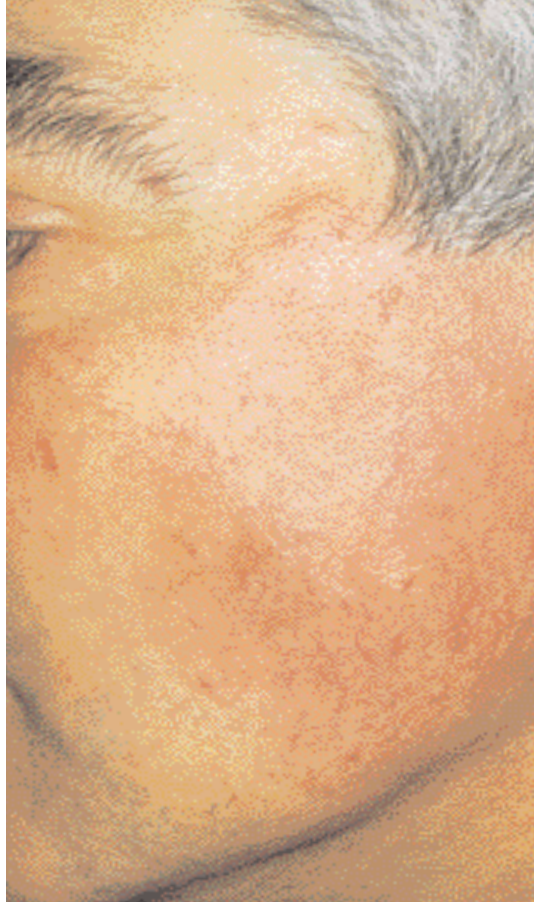
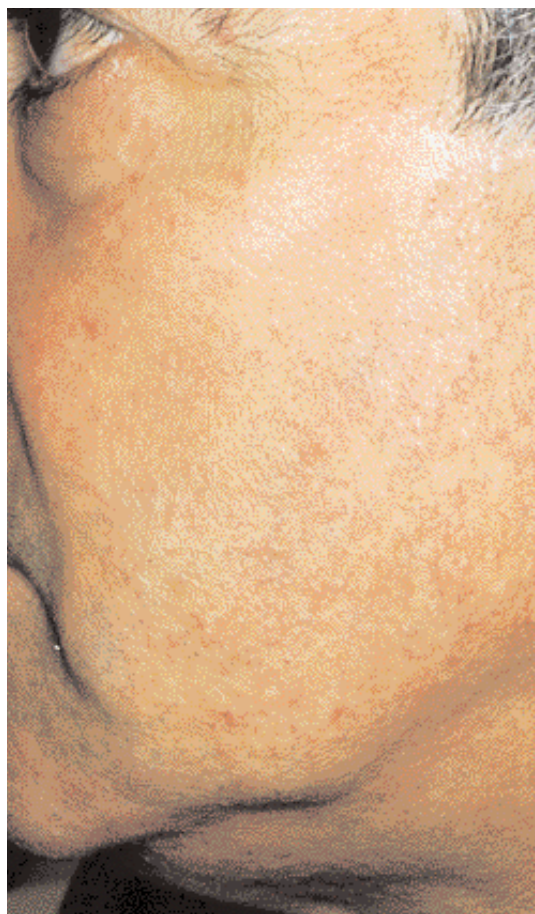Fig. 15.1.2 The residual telangiectasias are eliminated by means of timed surgical treatment. Programme data: **coagulation with microelectrodes, 7 Watts, pulsed 5/29 hundredths of a second, EM 10 Green** electromaniple.



15.2 **Timedsurgical treatment**

Programme data

Timed 5 hundredths of a second or Direct pulsed 5/29 hundredths of a second - Coag microelectrodes - 7 Watts - EM 10 Green

Timedsurgical treatment is simple and economical, and allows telangiectatic capillaries to be eliminated without scarring (Capurro 1979). The treatment is well tolerated without anaesthesia but a topical preparation of local anaesthetic (Emla®) can be applied to the skin 60 minutes before coagulation; alternatively, local anaesthesia can be administered.

15.3 **Technique**

After placing the neutral electrode in contact with the patient's skin, either on the chest or under a belt, the operator, working at the head of the bed (**Fig. 15.3.1**) cleanses the skin with a non-flammable antiseptic solution and sets the Timed

apparatus to the timed mode, with an emission time of **5 hundredths of a second**. For children, or for very fine telangiectasias (usually only visible with a lens) an emission time of **3 hundredths of a second** is more suitable, while for larger diameter veins and older patients it may be increased to **9 hundredths of a second**. The operator then sets the apparatus to **coagulation with microelectrodes** and regulates the power to **7 Watts**. An **EM 10** electromaniple with a diameter proportional to the telangiectasia is then inserted (Tab. 15.2).

The ectatic capillaries are eliminated by means of multiple microcoagulations 1 or 2 millimetres apart along the course of the capillary (**Fig. 15.3.2-9**).

The duration of the emission is adjusted for optimal effect during the initial treatment, and the same settings are re-used in subsequent sittings.

The pulsed function can also be used: **pulsed 4/9 hundredths of a second**. Having programmed the Timed apparatus, the operator can concentrate fully on the position of the electromaniple.

Tab. 15.2 Choice of electromaniple

Fine microtelangiectasias	EM 10 White
Microtelangiectasias	EM 10 Green
Telangiectasias	EM 10 Grey, EM 10 Yellow

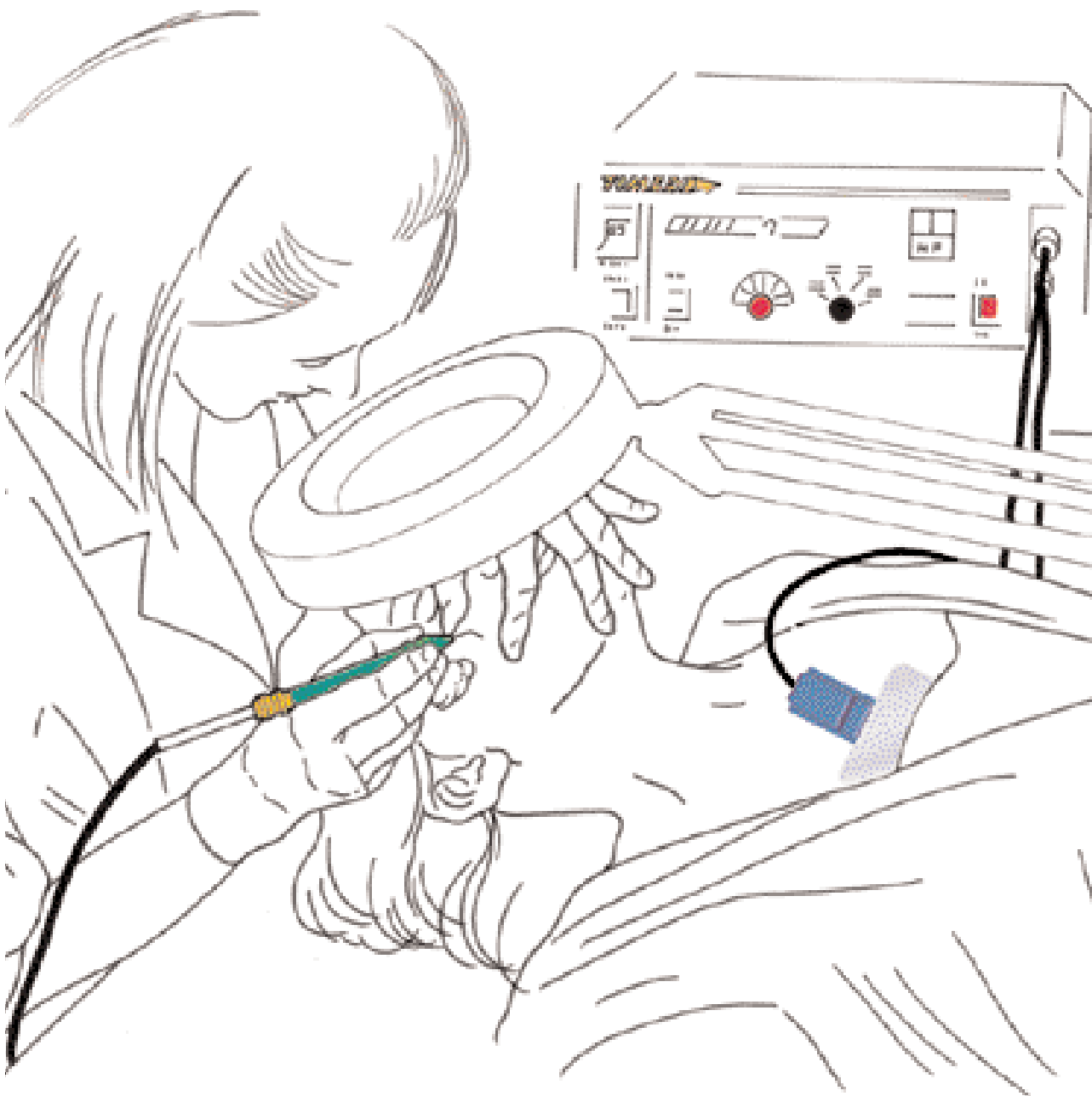


Fig. 15.3.1 Position of operator and patient during elimination of telangiectasias of the face.

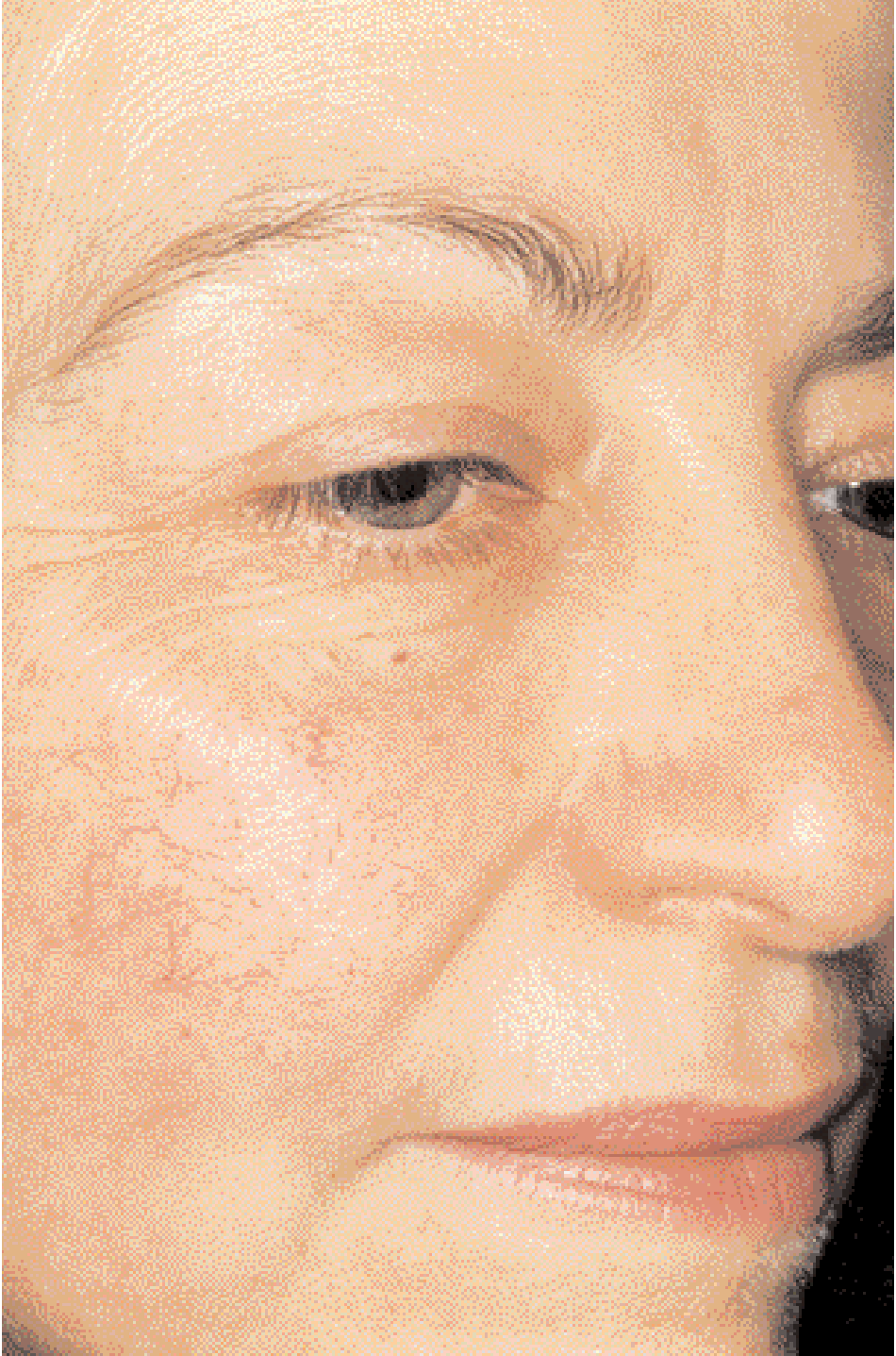


Fig. 15.3.2 Microtelangiectasias of the face.

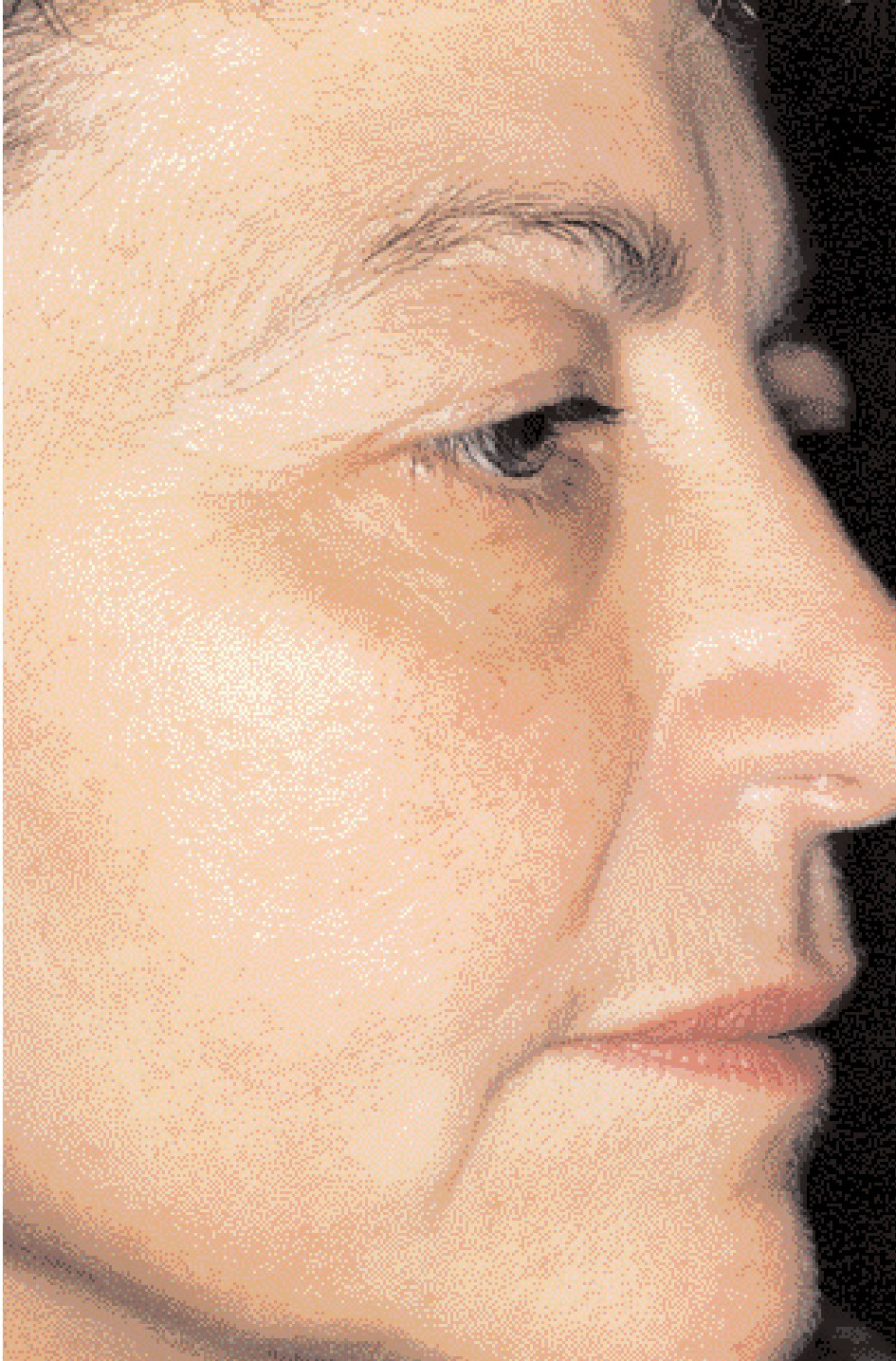

Fig. 15.3.3 Results after eight sittings. Programme data: coagulation with microelectrodes, 7 Watts, 5 hundredths of a second, EM 10 Green electromaniple.

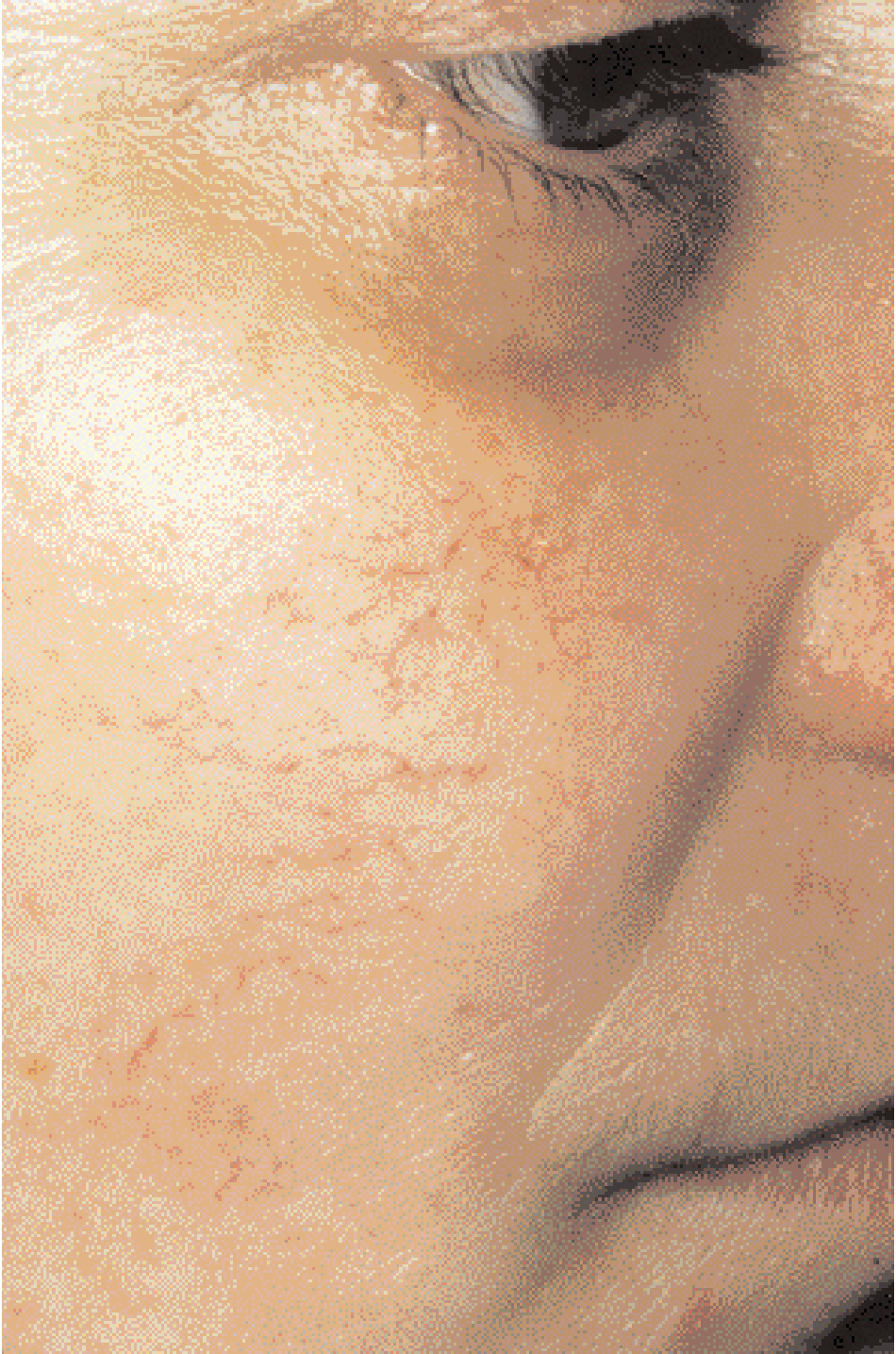

Fig. 15.3.4 Microtelangiectasias of the face.

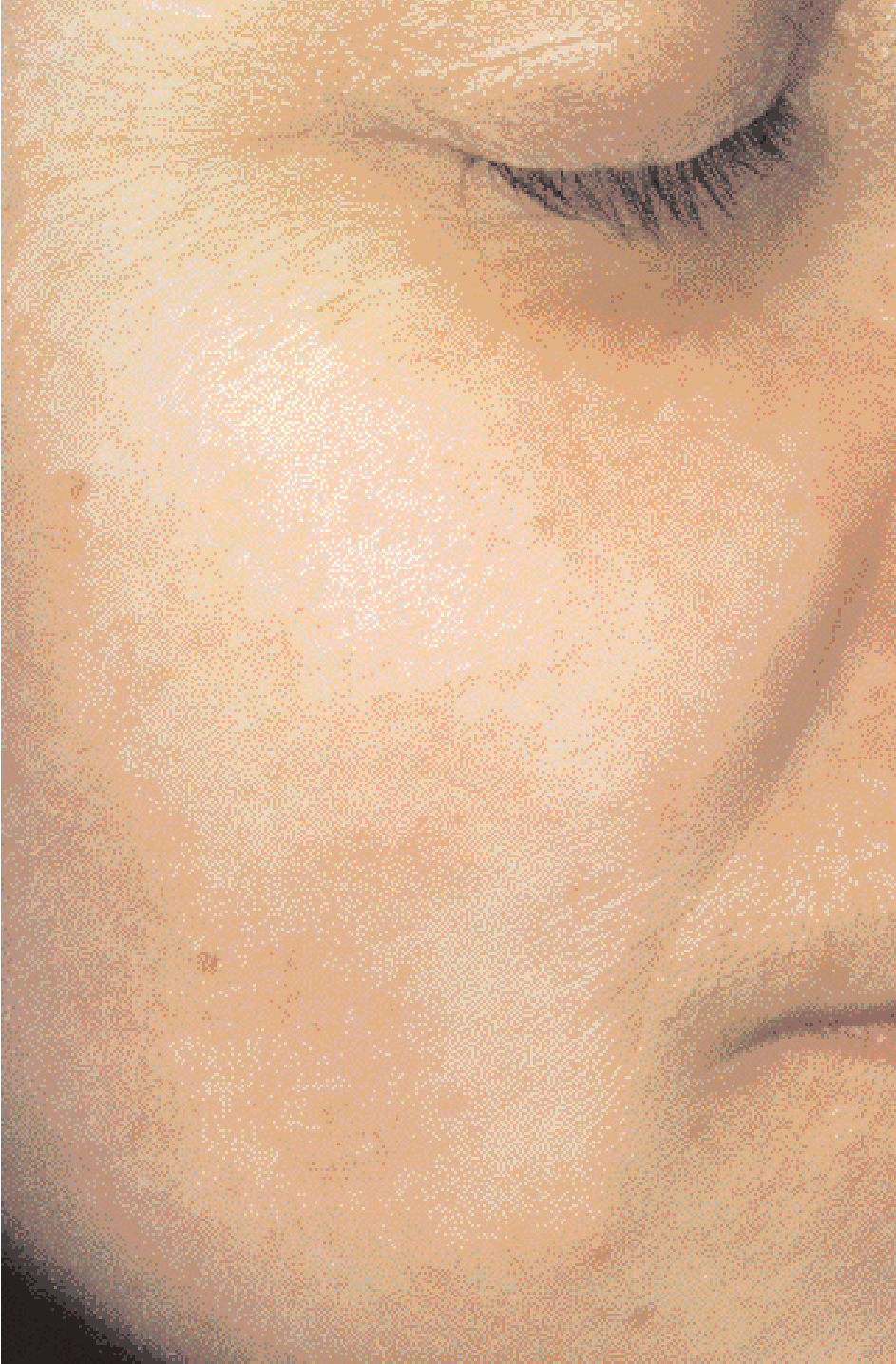

Fig. 15.3.5 Results after five sittings. Programme data: coagulation with microelectrodes, 7 Watts, 5 hundredths of a second, EM 10 Green electromaniple.

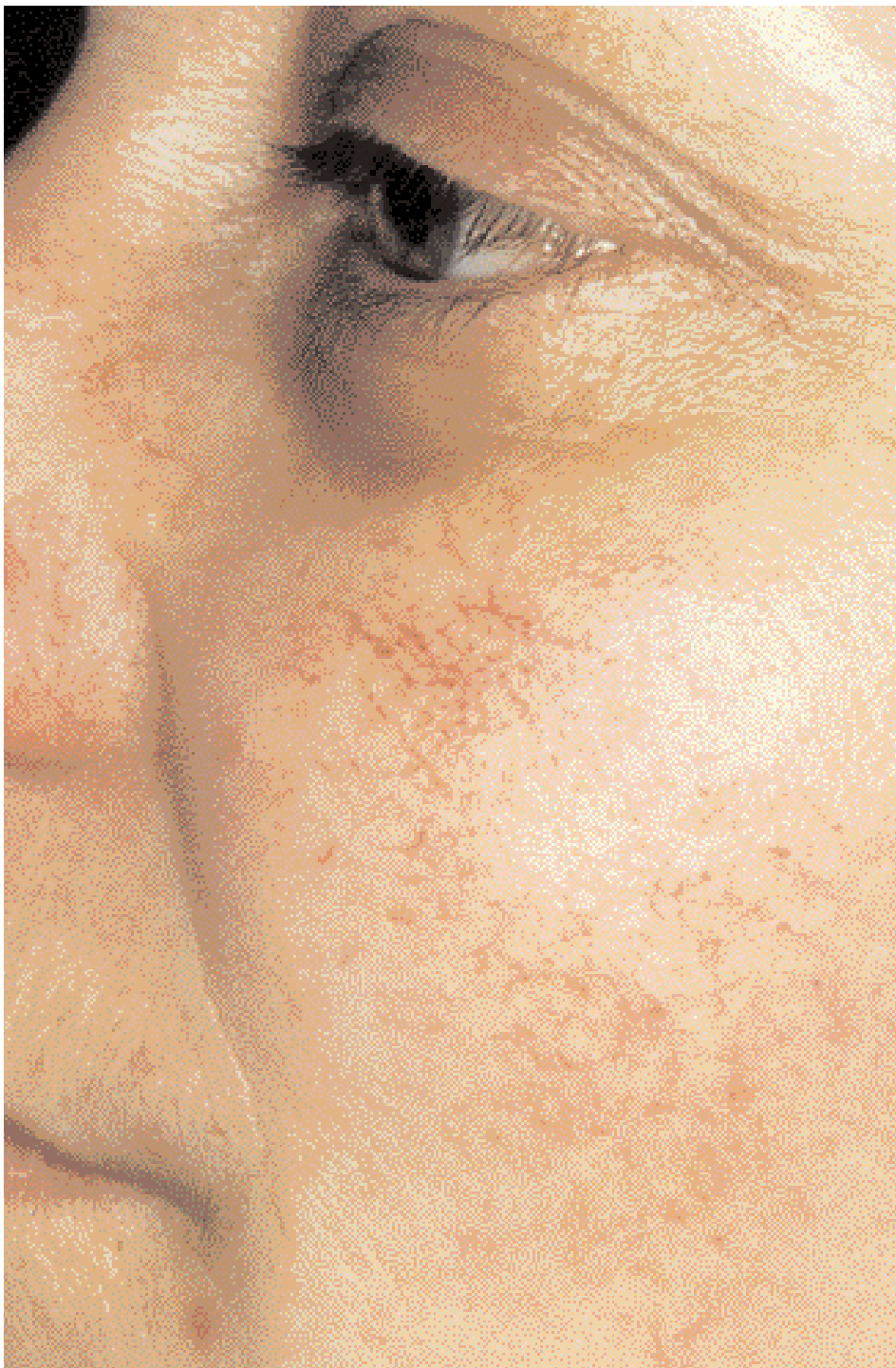

Fig. 15.3.6 Microtelangiectasias of the face.

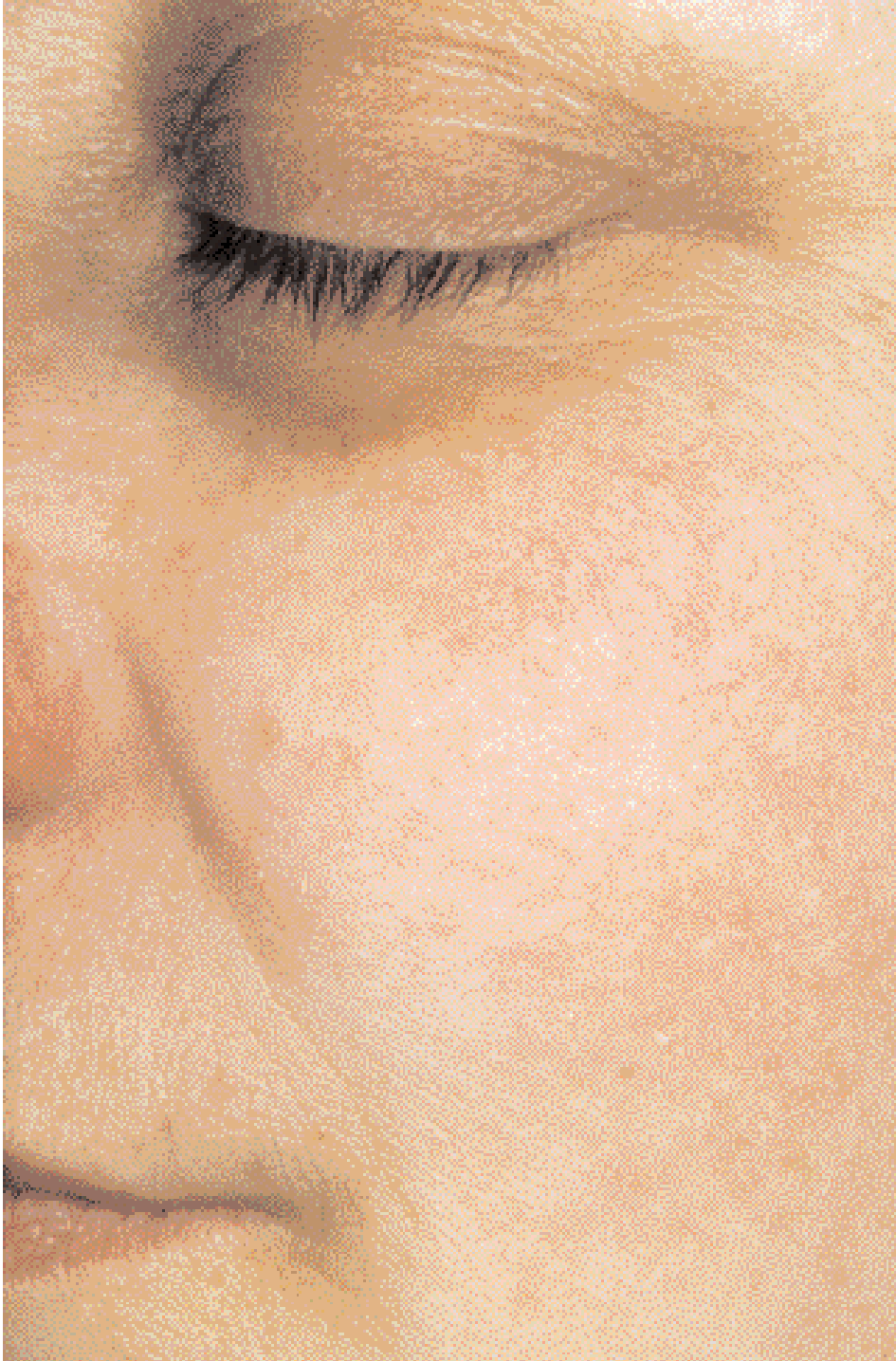

Fig. 15.3.7 Results after five sittings. Programme data: coagulation with microelectrodes, 7 Watts, 5 hundredths of a second, EM 10 Green electromaniple.

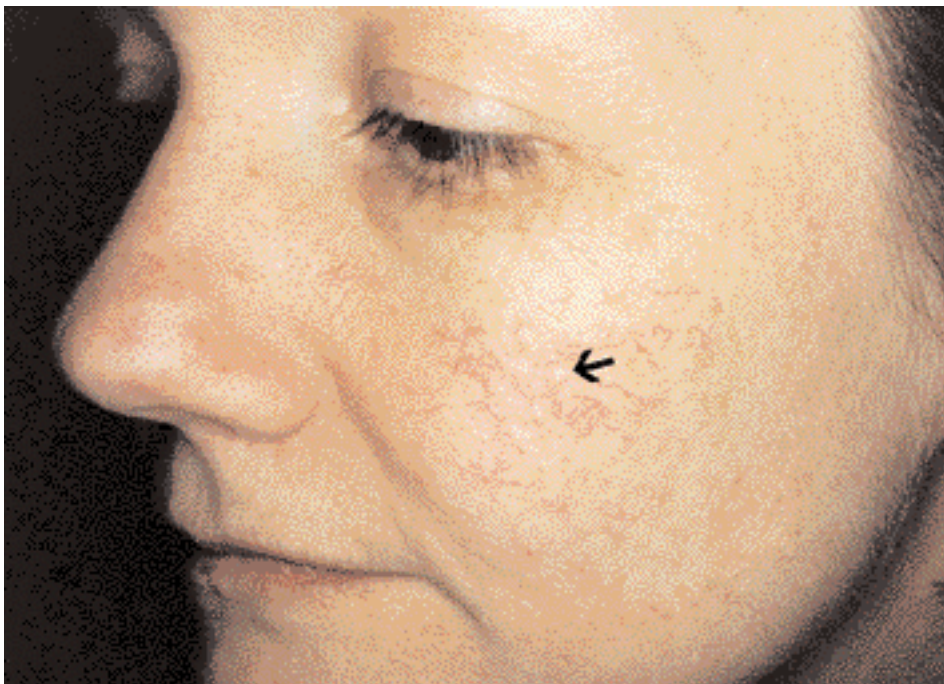

Fig. 15.3.8 Telangiectasias of the face. Scars after treatment with traditional electrosurgery.

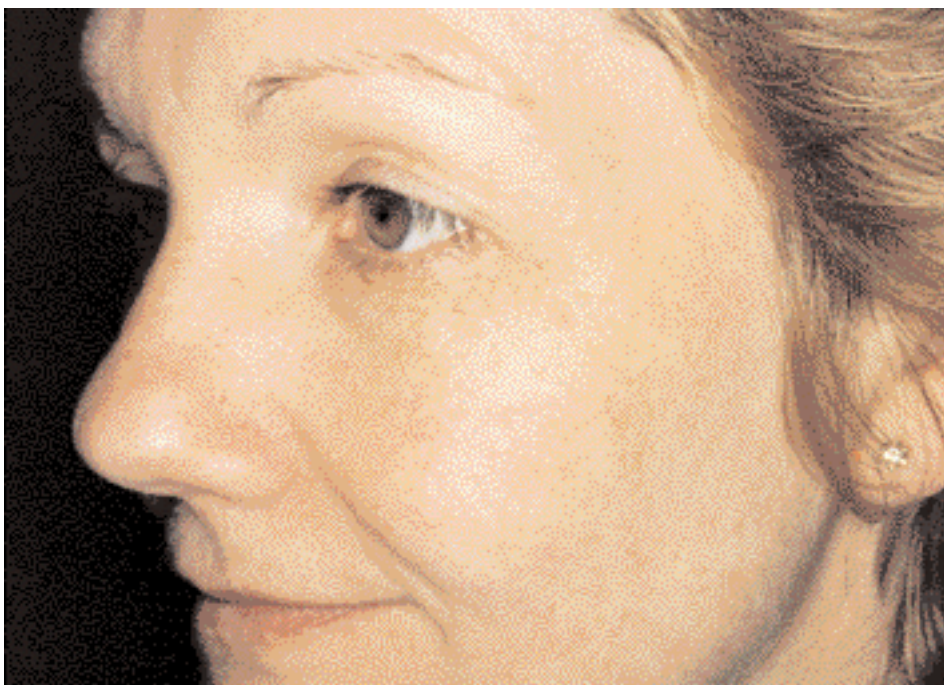

Fig. 15.3.9 Results after three sittings. Programme data: coagulation with microelectrodes, 7 Watts, 6 hundredths of a second, EM 10 Grey electromaniple.

The tip is placed under the epidermis above the telangiectasia, thus obtaining an adequate electrical contact.

The conical point is perpendicular to the skin surface.

Positioning the **EM 10** electromaniple exactly above the capillary, the operator pushes the pedal, which generates the timed or pulsed emission, allowing the point to cross the ectatic vessel (**Fig. 15.3.10-12**).

Perfect synchronization is required between initiation of emission and hand movement to insert the electromaniple, although penetration of

the point is facilitated by the simultaneous emission of energy.

The electromaniple should not be forced into the skin, but allowed to penetrate owing to the heat generated by the emission.

In larger telangiectasias, the operator may reinforce the effect by delivering a second emission while in contact with the vessel, without moving the electromaniple further (**Fig. 15.3.13-14**).

A second emission also facilitates deeper penetration of the electromaniple if the capillary is not transected on the first emission.

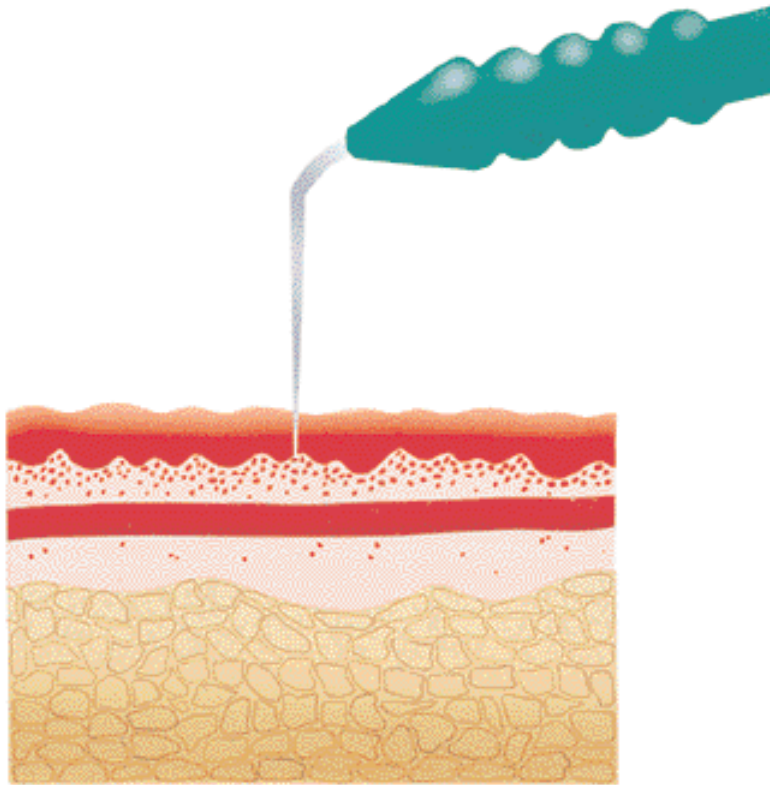


Fig. 15.3.10 The operator carefully positions the electromaniple on the telangiectasia. The point is perpendicular to the surface and penetrates the epidermis as far as is necessary to obtain electrical contact.

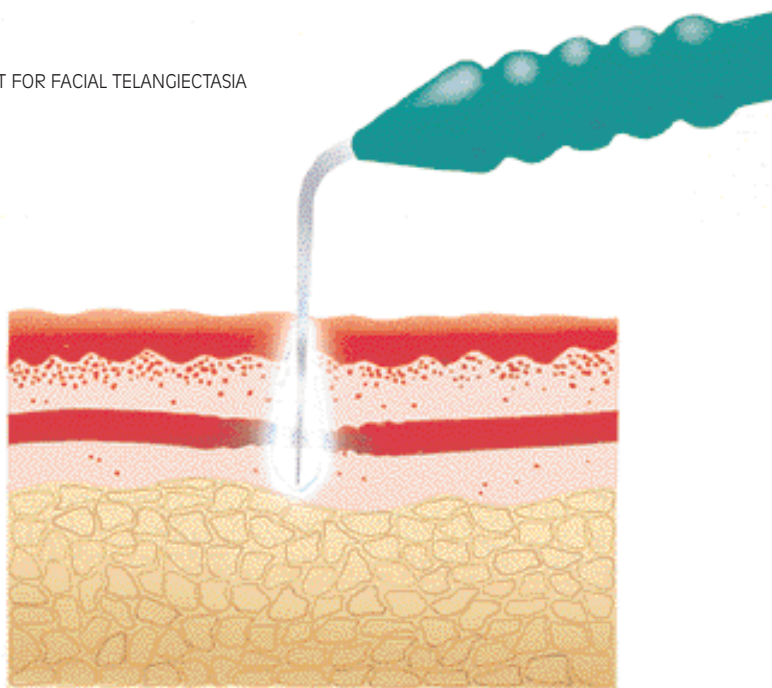


Fig. 15.3.11 The operator generates the programmed emission by pushing the pedal and simultaneously lowers the electromaniple until it has crossed the telangiectasia. The point penetrates the dermis during the emission.

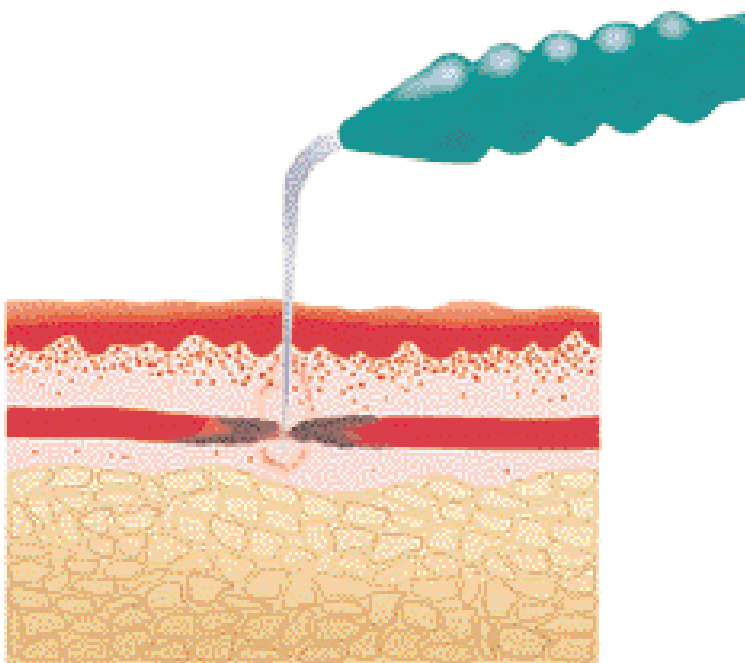


Fig. 15.3.12 The electromaniple is repositioned approximately every 1 mm and the process repeated to coagulate the telangiectatic vessel along its entire length.

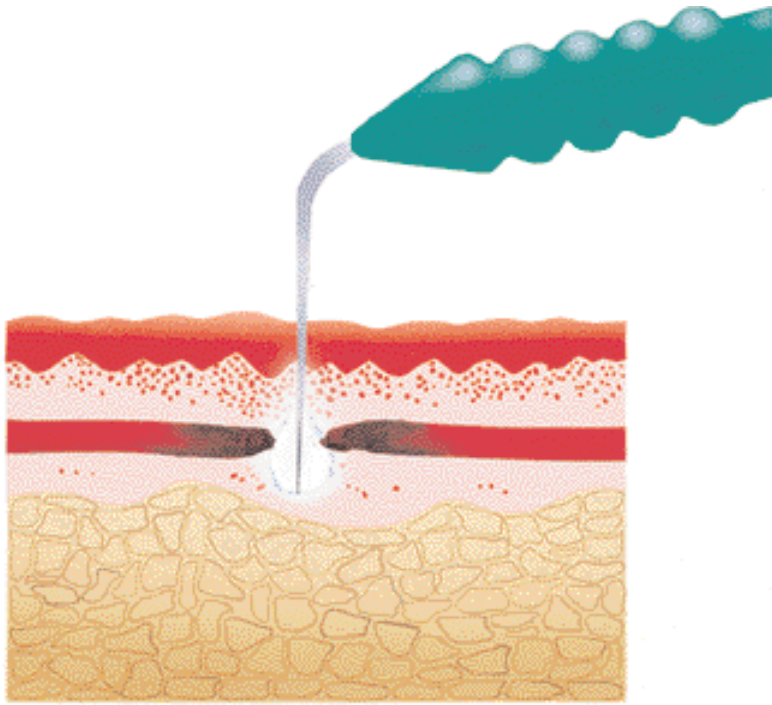


Fig. 15.3.13 With larger capillaries, a second emission is delivered with the point in contact with the vessel.

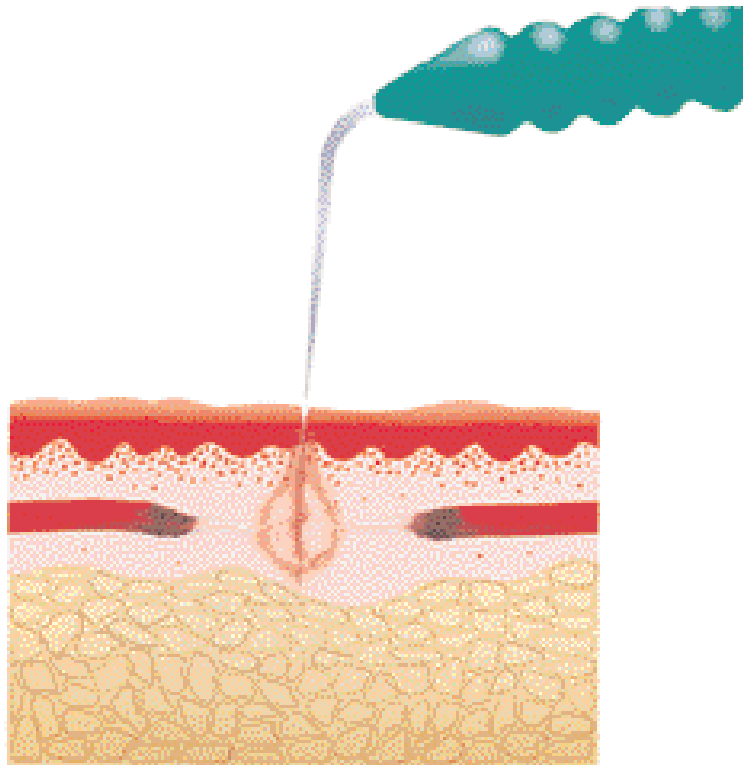

Fig. 15.3.14 The second emission is particularly effective because all the energy is used to coagulate the telangiectasia. (During the first emission, part of the energy is used to aid penetration of the skin by the electromanipule).

This is more frequent in the treatment of telangiectasias of the lower limbs. If the telangiectasias are superficial, the point of the electromaniple crosses them on entering the skin to a depth of about 1 mm. If they are deep they may be crossed by increasing the emission time or inserting the electromaniple more quickly. The possibility of varying the depth of action is one of the advantages of using electromaniples.

Where the micro-coagulation is carried out, a small section of capillary disappears from view.

A series of coagulations carried out along the length of the vessel completes its elimination.

For correct conduction of the current, the electromaniple must be kept clean. As already shown, the point of the electromaniple must cross the capillary; if penetration is too superficial, although a section of capillary may disappear owing to the immediate oedema that follows the micro-coagulation, permanent results are not obtained.

The effect extends only a little way from the electromaniple tip (see Figs 7.4.3 - 4); the point must therefore be in direct contact with the tissues to be coagulated.

The telangiectasias are eliminated starting from the periphery and moving towards the midline of the face (**Fig. 15.3.15**).

It is desirable to work rapidly as the reflex erythema which develops within a few minutes may obscure the finer telangiectasias.

The sitting should not be interrupted for any reason as, on resumption, the smaller diameter telangiectasias will no longer be visible.

However, further sittings can be

repeated at weekly intervals.

The intensity of pinkening of the skin depends upon the individual patient and the density of micro-coagulations carried out.

Bleeding may occur in a few patients, especially during the first sittings. Although this is not serious, it can be resolved by simple pressure with cotton wool soaked in benzalkonium chloride antiseptic solution (**Fig. 15.3.16**).

If bleeding seems excessive, the patient may be hypertense or may have a high conductivity. In such cases the electromaniple point may be cutting. The operator increases the emission time by **2 or 3 hundredths of a second**, and uses an electromaniple of greater diameter in order to give a slightly lower energy density.

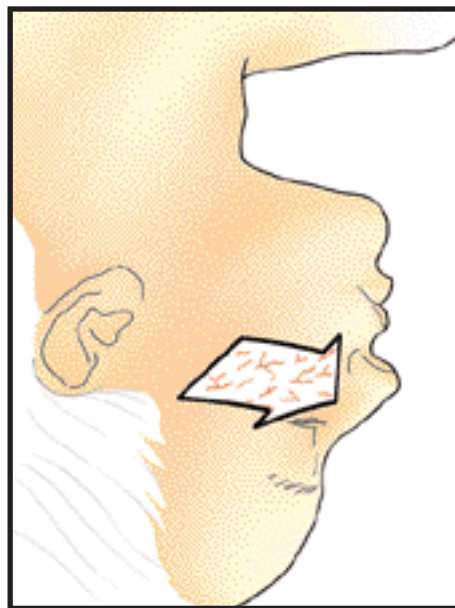


Fig. 15.3.15 The patient is positioned as shown and the telangiectatic capillaries are treated, starting with those on the lateral cheek and working medially.

Widespread facial telangiectasia is eliminated in 4 - 8 sittings of around 15 minutes each, at weekly intervals. At each sitting, 250 to 500 micro-coagulations may be performed, up to an absolute maximum of 1000. The recent introduction of bis-clerotherapy has accelerated the cure of couperose by reducing haemodynamic pressure, thus visibly reducing the diameter of the blood vessels.

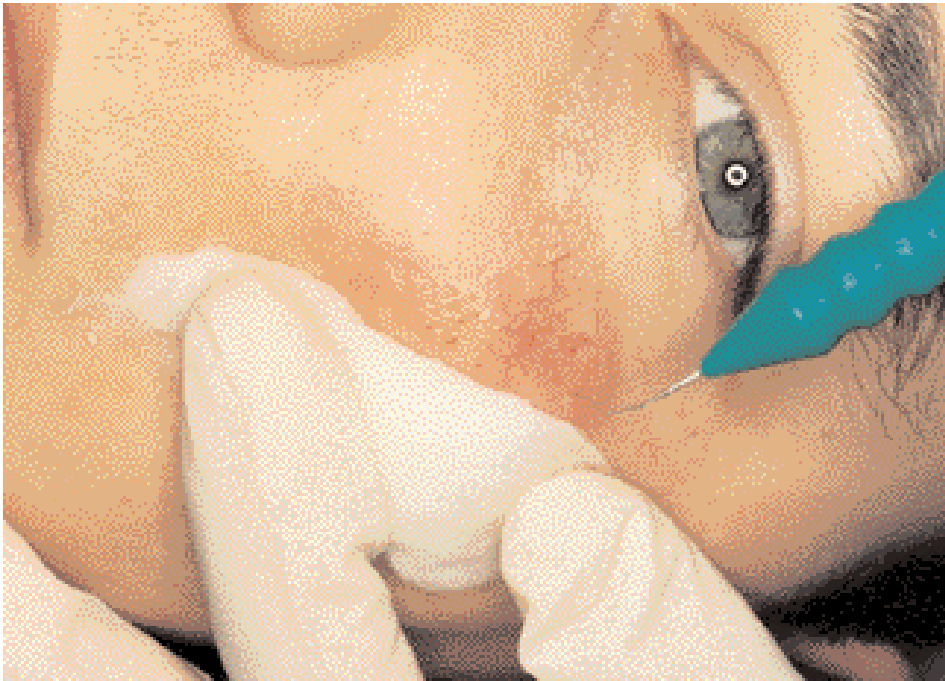


Fig. 15.3.16 During the procedure, the treated area is protected with cotton wool soaked in non-alcoholic antiseptic (benzalkonium chloride).

15.4 Post-operative treatment

At the end of the procedure, the operator cleans the treated zone and applies a lotion containing steroidal agents.

If bleeding occurs, the operator may coagulate the points which are bleeding, or cover them with small pieces of soft paper tissue before applying lotion.

The soft paper tissues are removed after a few minutes, leaving the patient's face clean (**Fig. 15.4.1**).

The patient may then return to normal activities.

The tiny crusts on the treated areas are scarcely visible (**Fig. 15.4.2**) and fall off after a few days, leaving the skin intact, without any sign of the coagulation.

After elimination of the telangiectasias, a slight reddening persists for a few weeks, and the final effect may not be seen for several months.

The erythema which may follow treatment can be reduced by applying a cream containing anti-inflammatory agents for a few days.

If more than 250 micro-coagulations are performed, the immediate application of a cold thermal mask for about 10 minutes will eliminate the slight sensation of burning and reduce inflammation (**Fig. 15.4.3**).

The patient's face must be protected from the sun by the application of a suitable cream (total UV block).

If the microtelangiectasias are accompanied by rosacea or by symptoms which precede rosacea, medical treatment will be required both before and during timed surgical treatment.

Table 15.3 lists possible complications.

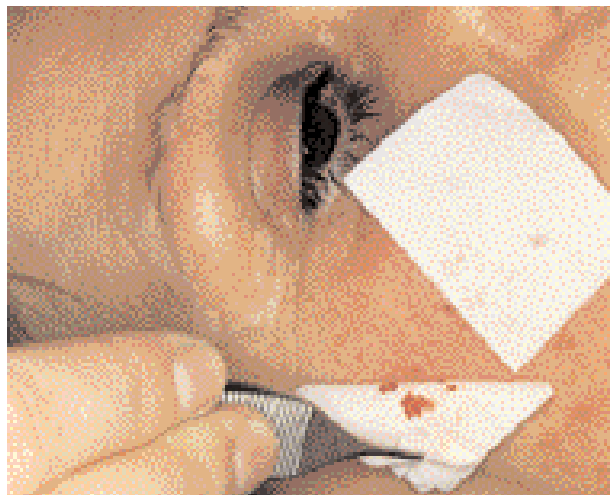

Fig. 15.4.1 At the end of the procedure, if some micro-coagulations are bleeding, the operator applies a small square of soft paper tissue, which is removed after a few minutes.

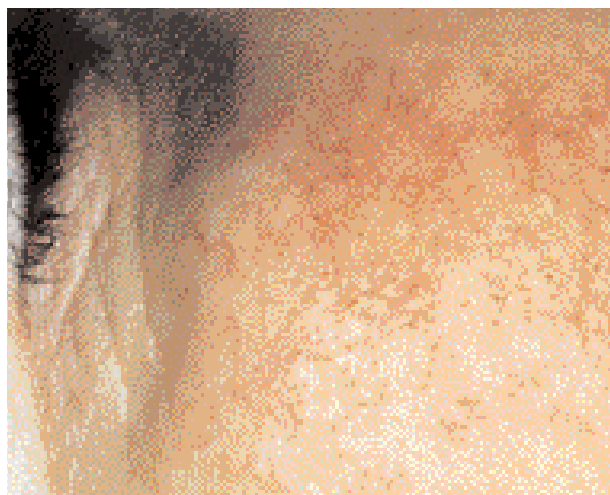


Fig. 15.4.2 After 2 days, tiny crusts form, which spontaneously fall off within a week.

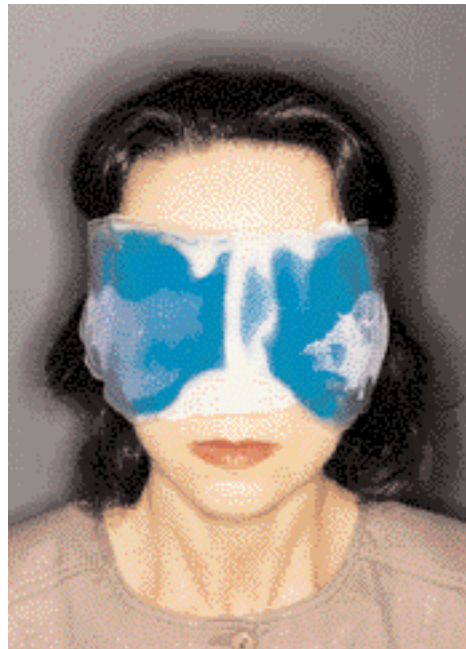


Fig. 15.4.3 Application of a cold thermal mask.

Tab. 15.3 Complications of timed surgical treatment of facial telangiectasia

REDDENING OF THE SKIN

(Sensitive patient, excessive number of micro-coagulations)
Apply decongestant lotion containing anti-inflammatory agents.
Reduce the number of micro-coagulations per sitting.
Medical treatment, 8% bisclerotherapy

HYPERPIGMENTATION

(Exposure to UV rays. Oral contraceptive therapy. Pregnancy).
Avoid exposure to UV radiation until normal skin colour returns.
Protect the treated zones with a total sun screen cream.
Apply de-pigmenting creams.

SLIGHT SUPERFICIAL DAMAGE

(Patient with fine skin texture. Use of too large an electromaniple or a dirty electromaniple. Emission time too long. Emission too superficial. Infection).
Use a smaller diameter electromaniple.
Make sure that the electromaniple is clean.
Ensure that emission time is correct.
Ensure deeper penetration of the electromaniple into the skin.
Disinfection and antibiotic therapy.

HAEMATOMA

(A rare complication of treatment of telangiectasias of the lower eyelid)
At the first sign of this, apply pressure to the area for a few minutes.

RECURRENCE

(High blood pressure. Exposure to sun).
Inject 2-6 ml of 8% Bisclero into the ectatic capillaries at weekly intervals until the calibre of the vessels is reduced.
Avoid exposure to UV radiation.

16

TREATMENT OF “RED NOSE”

Telangiectasias and microtelangiectasias of the nose have the same aetiology as telangiectasias of the cheeks. They may begin after a trauma or rhinoplasty (**Fig. 16.0.1**).

16.1 8% bisclerotherapy

In cases of evident telangiectasias, a small amount of 8% Bisclero to which a little lidocaine has been added is slowly injected before timed surgery is performed.

Trapping the sclerosing solution yields more rapid results.

As the solution is injected, the operator keeps the angular vein compressed with a finger.

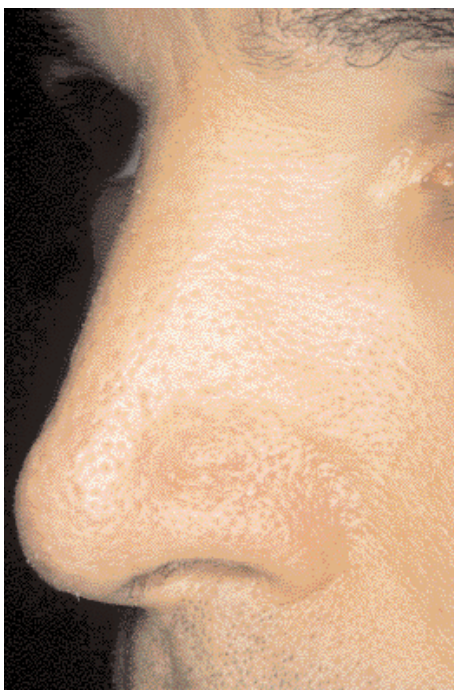
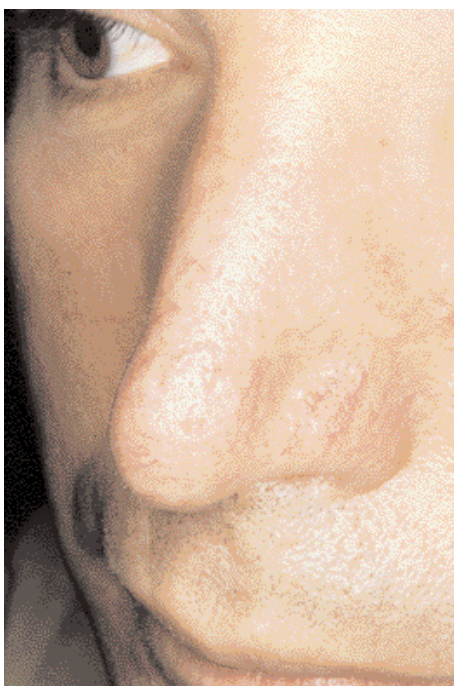
Fig. 16.0.1 Microtelangiectasias arising after cosmetic rhinoplasty (top), eliminated in three sittings (bottom). Programme data: coagulation with microelectrodes, 7 Watts, 5 hundredths of a second, EM 10 Green electromaniple.

16.2 Timedsurgical treatment

Programme data

Timed 5 hundredths of a second or Direct pulsed 5/29 hundredths of a second - Coag microelectrodes - 7 Watts - EM 10 Green

The elimination of telangiectasias of the nose is achieved with the same method and the same programme as described for the cheeks.

Telangiectasias of the tip of the nose are sometimes large and require a larger diameter electroma-

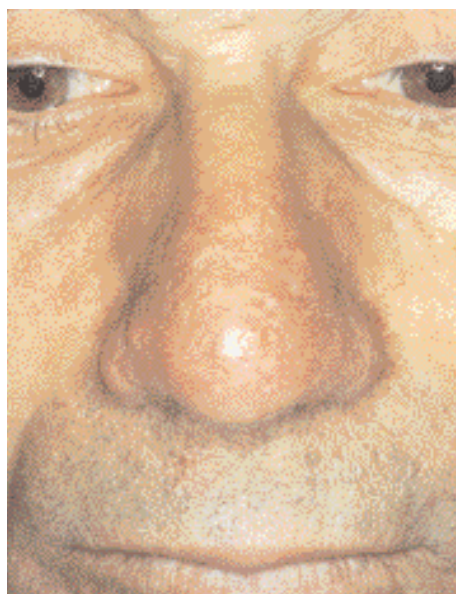
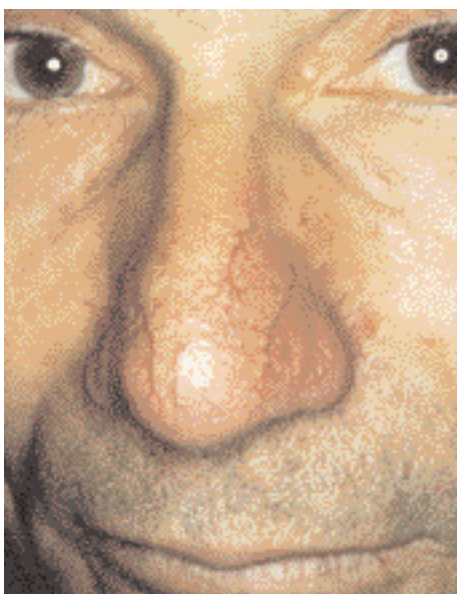
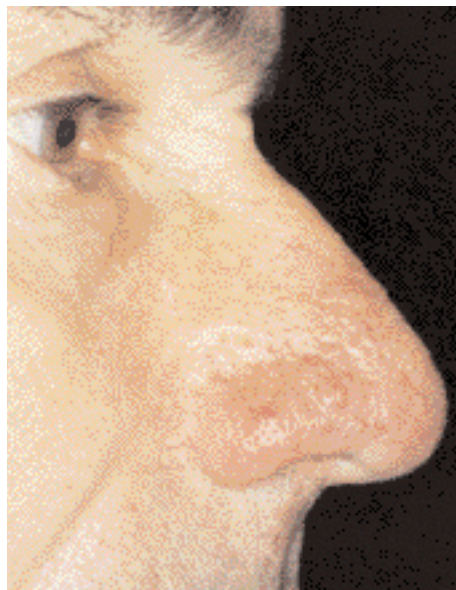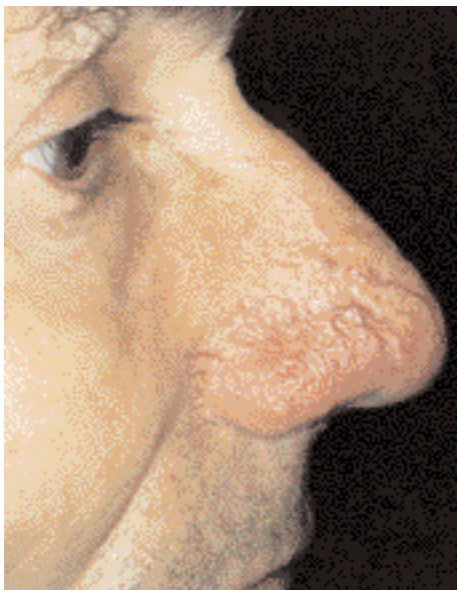Fig. 16.2.1 Telangiectasias on the tip of the nose, eliminated in three sessions. Programme data: coagulation with microelectrodes, 7 Watts, 9 hundredths of a second, EM 10 Yellow electromaniple.

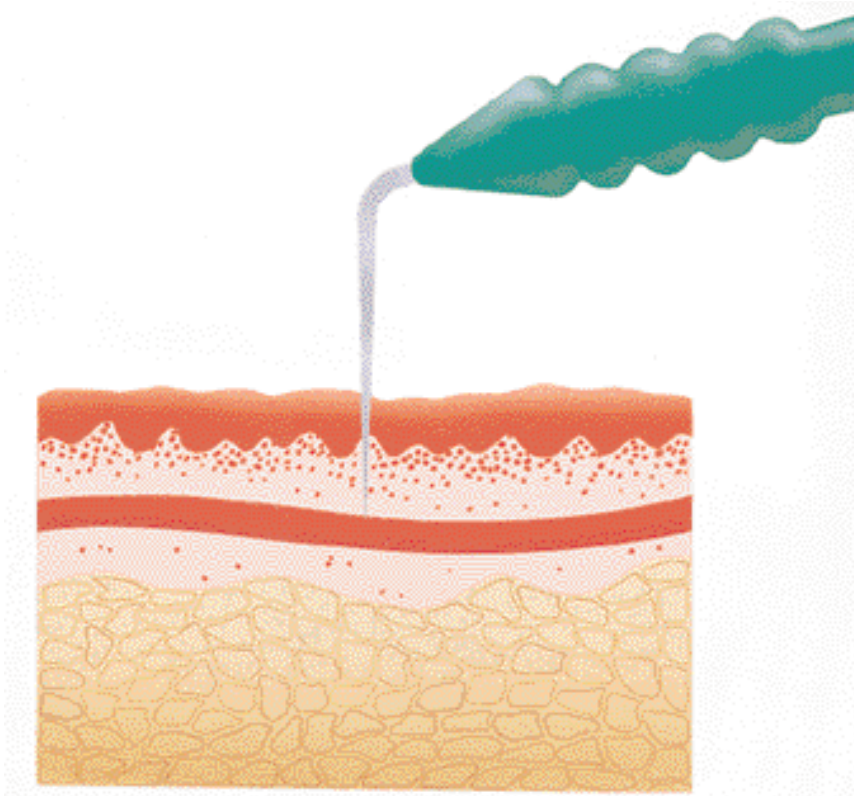


Fig. 16.2.2 To eliminate telangiectasias of the nasal ala, the operator inserts the **EM 10** electro-manipule into the dermis before generating the emission.

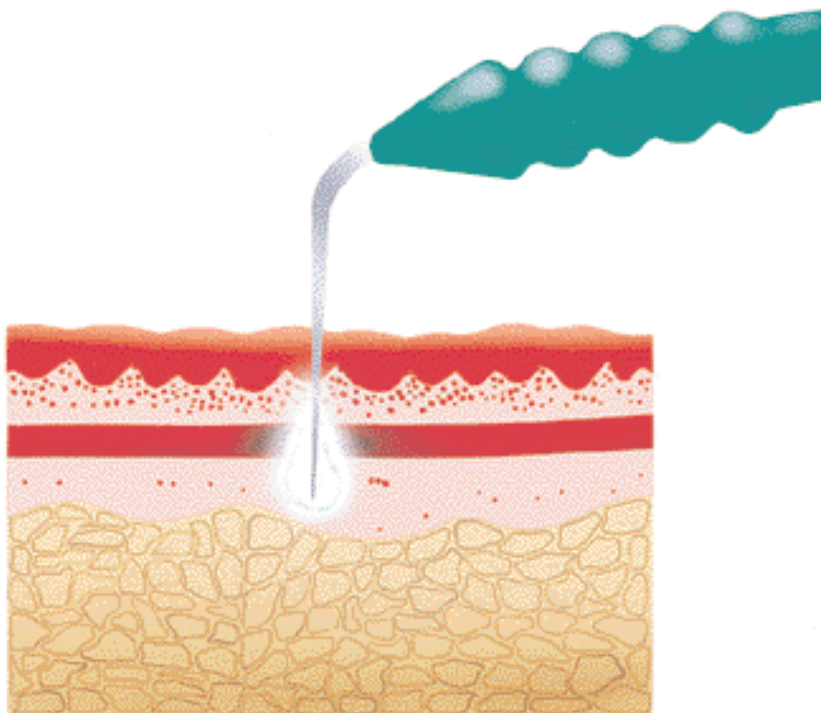
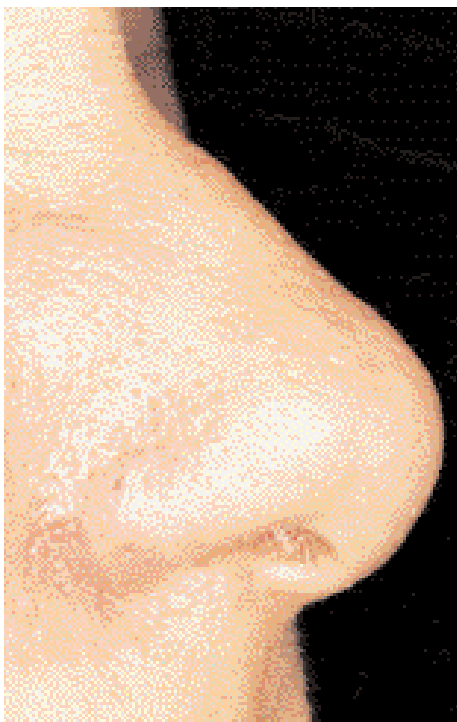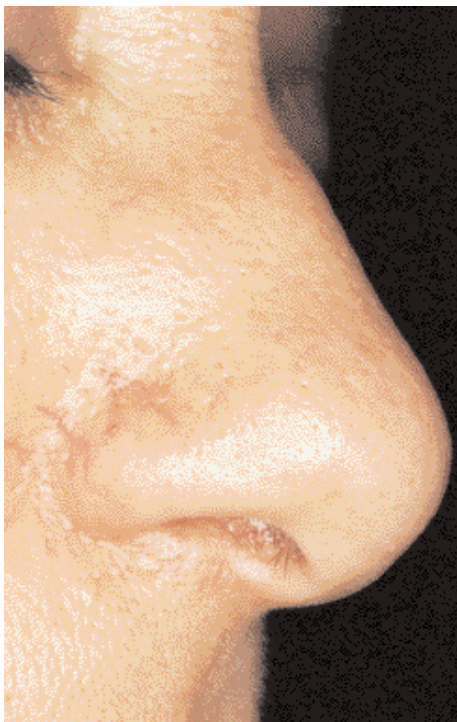


Fig. 16.2.3 The timed emission generated at this depth does not produce a visible surface change even though the tissues, which are rich in sebaceous glands in this region, are particularly sensitive to heat.



niple such as an **EM 10 Grey** electro-maniple and longer emission time, up to but not exceeding **9 hundredths of a second (Fig. 16.2.1)**. The ectatic capillaries situated on the nasal ala are deeper than in other areas of the face.

In this region it is advisable to generate a timed emission after the electromaniple has penetrated deep into the vessel (**Fig. 16.2.2-3**), or to carry out a very rapid penetrating movement of the electromaniple.

In this way the surface changes which may be evident after superficial coagulation (owing to the particularly sebaceous skin in this region) are reduced to a minimum (**Fig. 16.2.4**). The microcoagulations must be spaced as far apart as possible in order to avoid visible marks.

Small pitted scars frequently result when using techniques which generate a dermal-epidermal lesion. However, small depressed scars resulting from this may be levelled by timed surgical resurfacing.

Fig. 16.2.4 Telangiectasias of the nasal ala (top) and immediately after microcoagulation (bottom).

17

TREATMENT OF RHINOPHYMA

Rhinophyma (from the Greek «*rhis*» = nose - «*phyma*» = growth) is a hypertrophy of the soft tissue of the nose, characterised by chronic inflammation, hyperplasia of the sebaceous glands and vascular dilatation.

17.1 Decortication of low-grade Rhinophyma

Programme data

Cutting

Direct - Cut - 20 Watts - EM10 Yellow

Programme data

Peeling

Direct - Coag microelectrodes - 20 Watts - EM 15

Low-grade rhinophymas are eliminated, utilising the cut or blend function, with which most of the hypertrophic tissue is removed, followed by timed surgical peeling, with which the surface of the nose is "sculpted" and imperfections are levelled.

This technique allows precise treatment of the lesion and preservation of the concavity of the nasal ala. The decorticated area is left to heal spontaneously. Re-epithelialisation develops from the epidermis of the fundus of the sebaceous glands.

The procedure is rapid.

Slight irregularities of the skin surface can be levelled after six months by means of timed surgical resurfacing carried out at **50 Watts** in the cutting function.

17.2 Technique

After positioning the return electrode in contact with the patient's skin and administering, under local anaesthesia (**Fig. 17.2.1**), the operator sets the Timed apparatus to the direct mode, with the duration of emission controlled directly by means of the pedal the pedal. Either **cut or blend** is used with a power of **20 Watts**. An **EM 10 Grey** electromanipule or an **EM 10 Yellow** electromanipule is used.

The larger diameter electromanipule produces a more marked haemostatic effect.

The operator gently bends the end of the electromanipule into the shape of a hockey stick (Albom M., 1976) and removes hypertrophic tissue in fine strips parallel to the surface of the skin (**Fig. 17.2.2**).

This technique allows a gradual, and therefore safer, removal of tissue.

The effect on the tip of the nose is controlled by placing a finger in each nostril to ensure adequate amounts of tissue remain and to prevent damage to the alar cartilages.

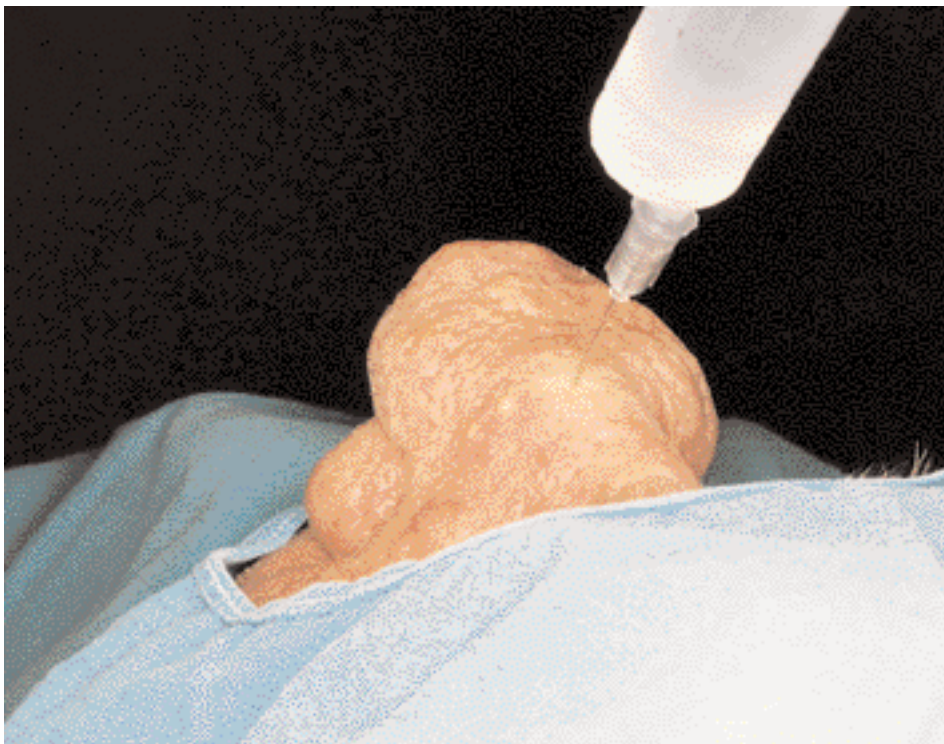

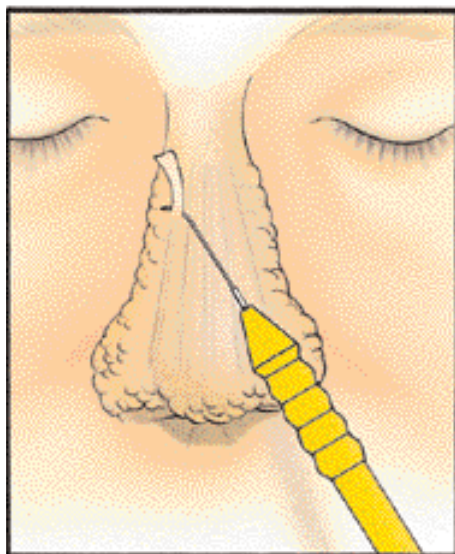
Fig. 17.2.1 The infiltration of local anaesthetic containing adrenaline reduces bleeding.

The use of the blend function greatly reduces bleeding, which may be further controlled by coagulating individual blood vessels with the tip of **EM 15** electromaniple.

The surface of the nose is then levelled and finely sculpted by means of timed surgical peeling, which eliminates imperfections and completes haemostasis.

The levelling of superficial imperfections is performed with rapid movements of the **EM 15** electromaniple; as with all cases of timed surgical peeling, it is necessary to ensure that the electromaniple does not stop while in contact, because this will cause deep damage.

The tissues covering the osteo-carti-



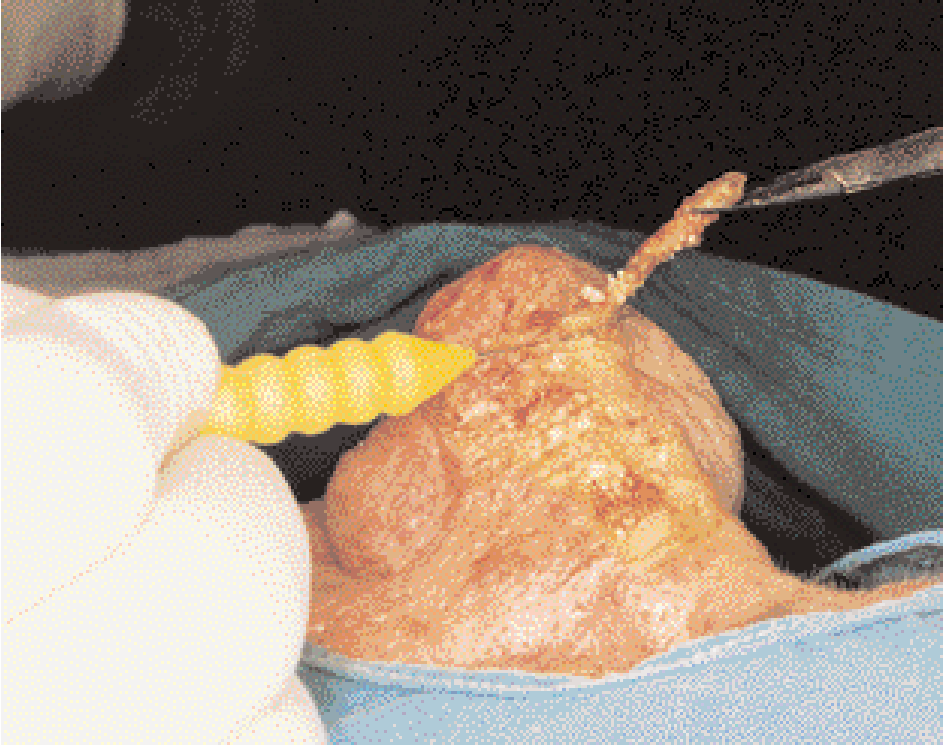


Fig. 17.2.2 Decortication. Programme data: **cut, 20 Watts, EM 10 Yellow** electromaniple. The nasal shape is sculpted with progressive removal of thin slices of hypertrophic tissue using an electromaniple which has been slightly bent near its tip. Local anaesthesia. To prevent delayed healing and scarring, 2 mm of undamaged tissue must be preserved over the cartilage.

laminous skeleton are reduced until the correct thickness is reached.

A non-adherent dressing is applied after the operation.

The treated surface is kept dry. Applications of povidone-iodine solution are useful.

The dressing detaches spontaneously when the surface of the nose is re-epithelialised, in around four weeks (**Fig. 17.2.3**).



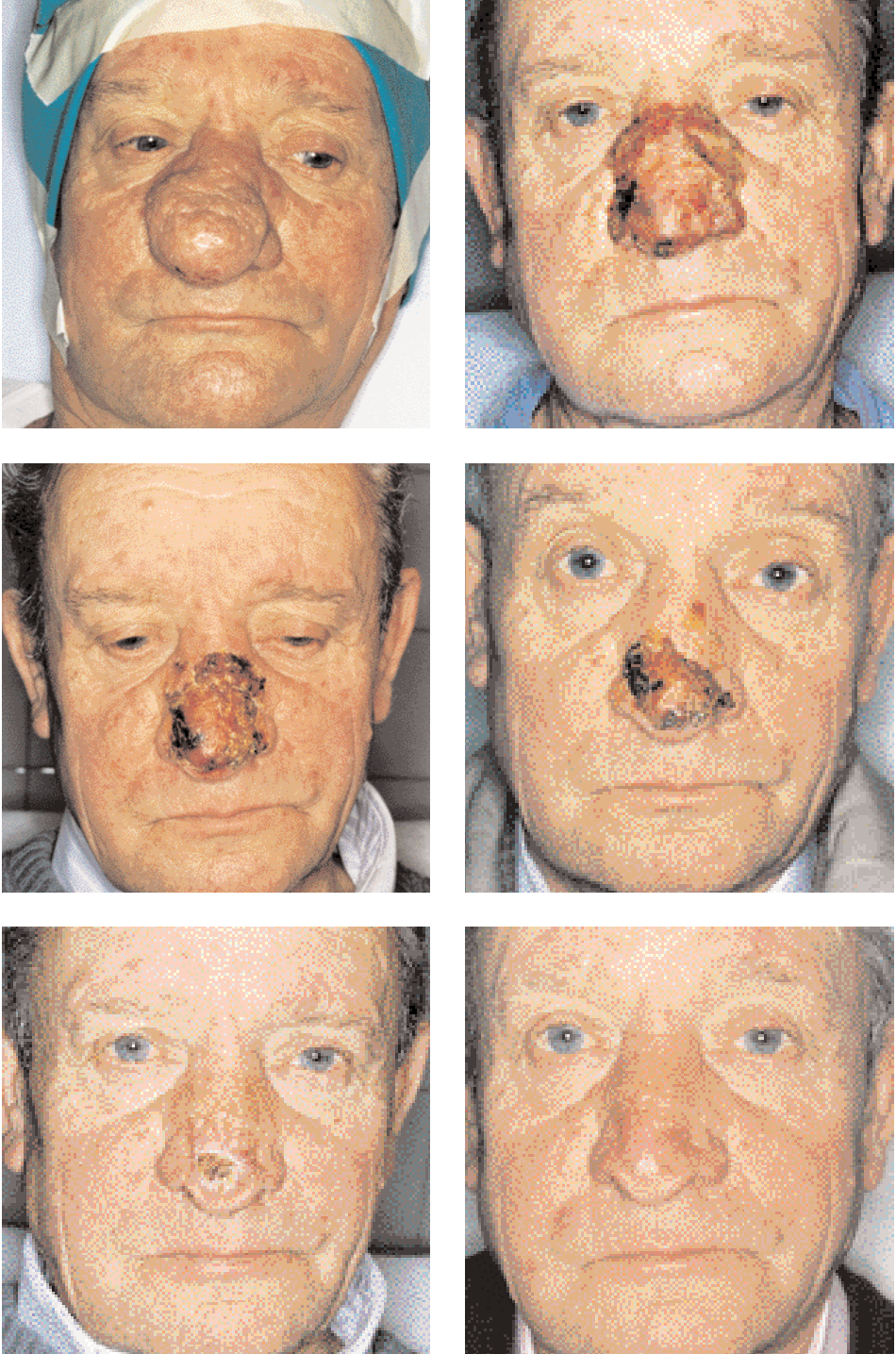

Fig. 17.2.3 A dressing is applied postoperatively and the wound allowed to heal.

17.3 Treatment of high-grade rhinophyma in two sessions

While low-grade rhinophyma can be corrected easily by gradually removing fine strips of hypertrophic tissue, in high-grade rhinophyma it is difficult to determine which tissue should be removed. If too many sebaceous glands are left, recurrences are often encountered within a few years. If, on the other hand, tissue removal is too deep and damages the cartilaginous skeleton, skin grafts of appropriately thinned excised tissue will be required. (Crickelair 1972).

In any case, scarring is frequent in high-grade rhinophyma, especially since re-epithelialisation from the deep tissues close to the cartilages is difficult. To solve this problem, a high-grade rhinophyma must first be reduced to a low-grade rhinophyma (Capurro 1997).

To achieve this, a rectangular 5 mm thick flap of skin is lifted and the underlying tissue is removed to expose the cartilages, by means of **cut or blend** at **20 Watts** with an **EM10 Yellow** electromaniple (**Fig. 17.3.1**). After being suitably trimmed, the flap is sutured back in place under slight tension, and the nose becomes shorter (**Fig. 17.3.2**).

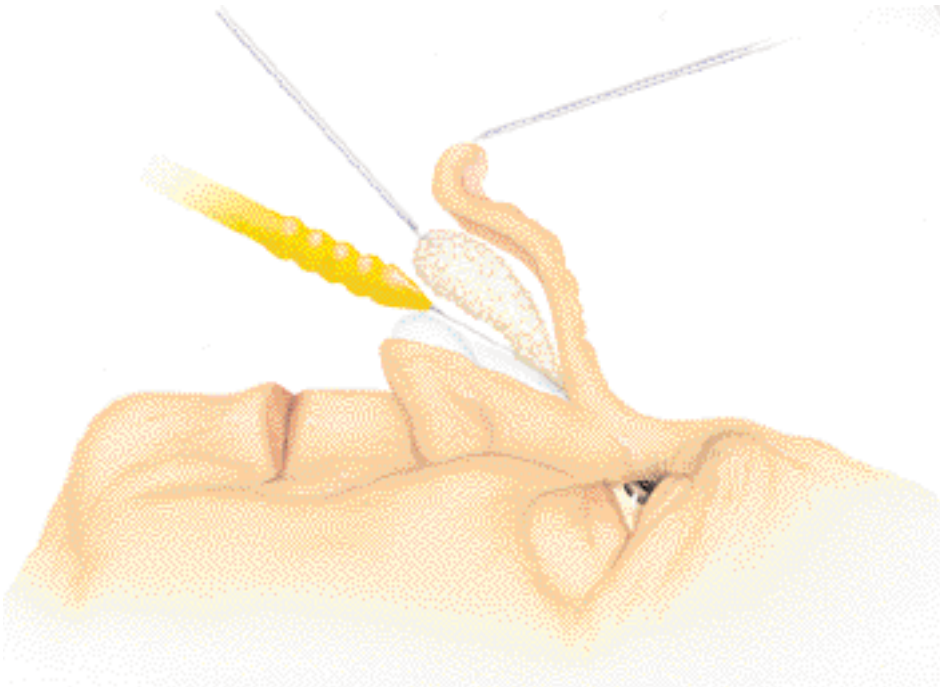


Fig. 17.3.1 High grade rhinophyma. In the first session a 5 mm thick rectangular flap is lifted and the underlying tissue removed down to the cartilage. Programme data: **cut, 20 Watts, EM 10 Yellow** electromaniple. Local anaesthesia.

A month later, superficial decortication is carried out, followed by timed surgical peeling, again under local anaesthesia. This operation is fairly simple, especially since the thickness of the flap is known.

Healing is optimal as the most superficial layer of the skin, which has been preserved, re-epithelialises more rapidly than the deep tissues (**Fig. 17.3.3**). Scarring is rare and recurrences unlikely on account of the appropriate thickness of the residual tissue and the reduced vascularisation determined by sculpting the flap.

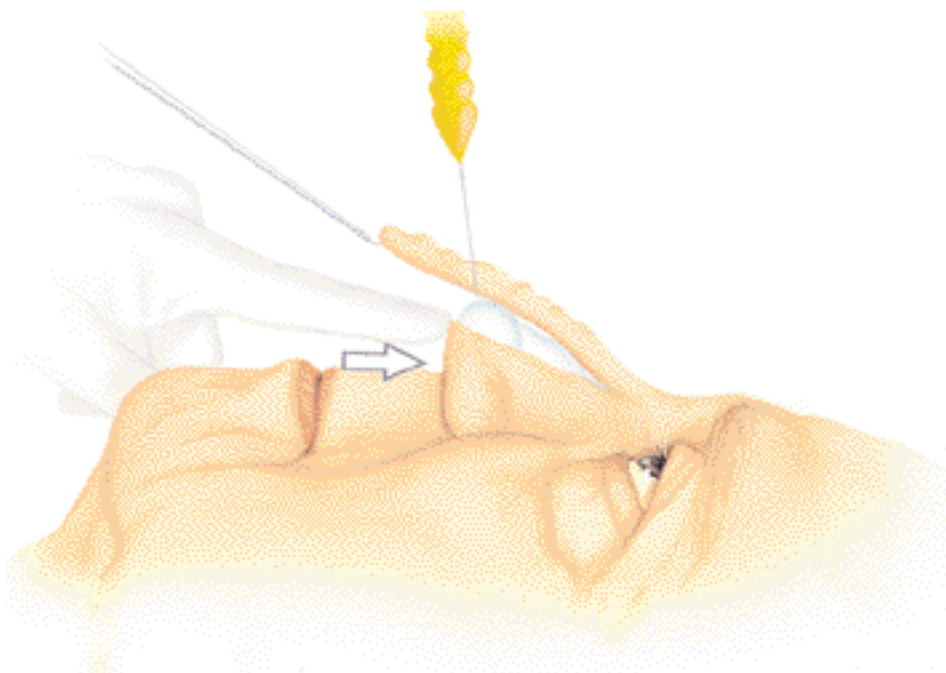


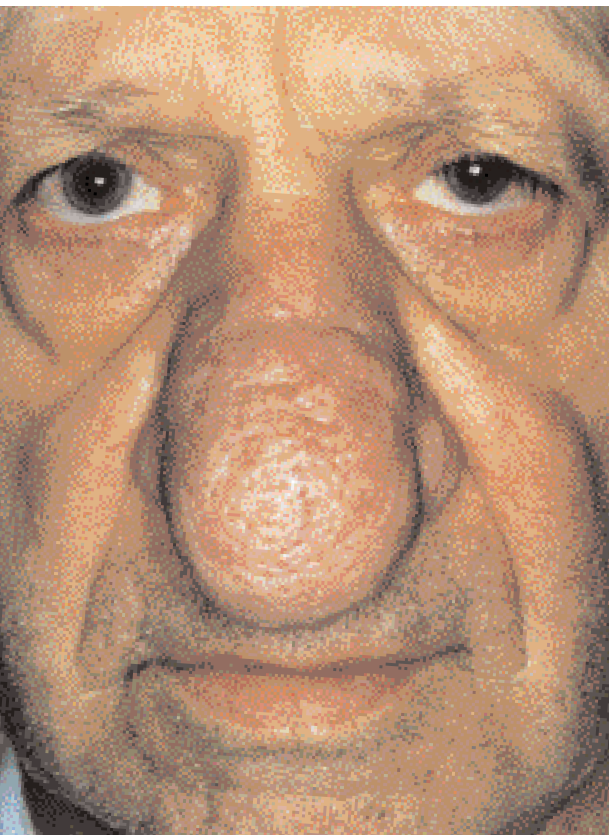
Fig. 17.3.2 The flap is trimmed and sutured back in place. In the second session, a month later, the surface of the skin is smoothed.

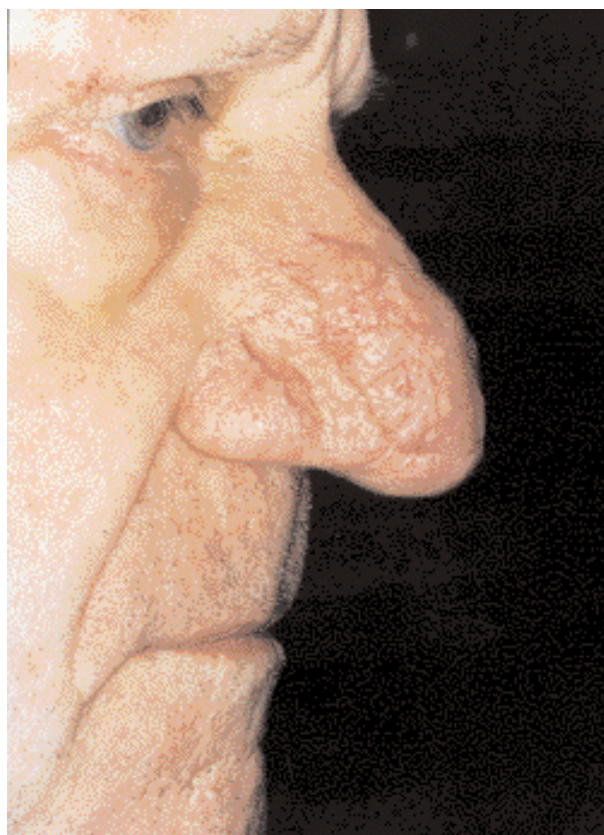
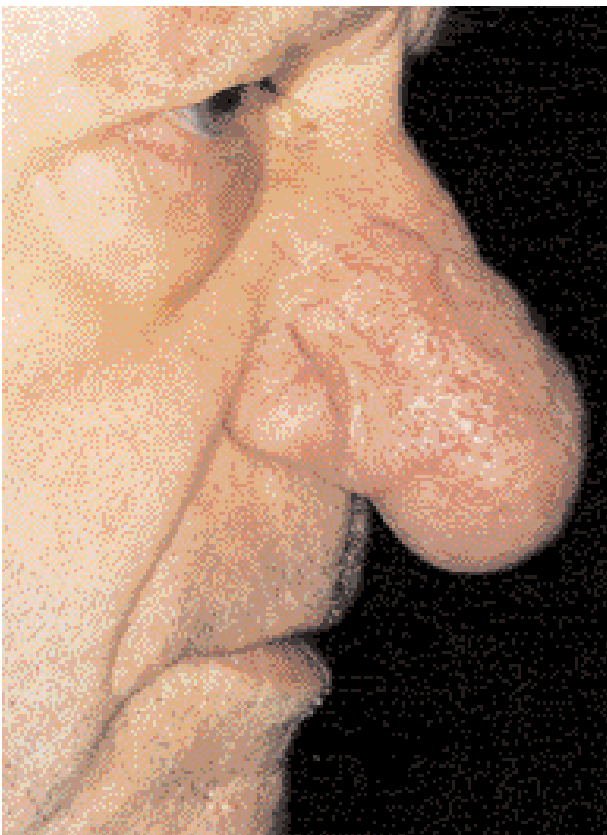
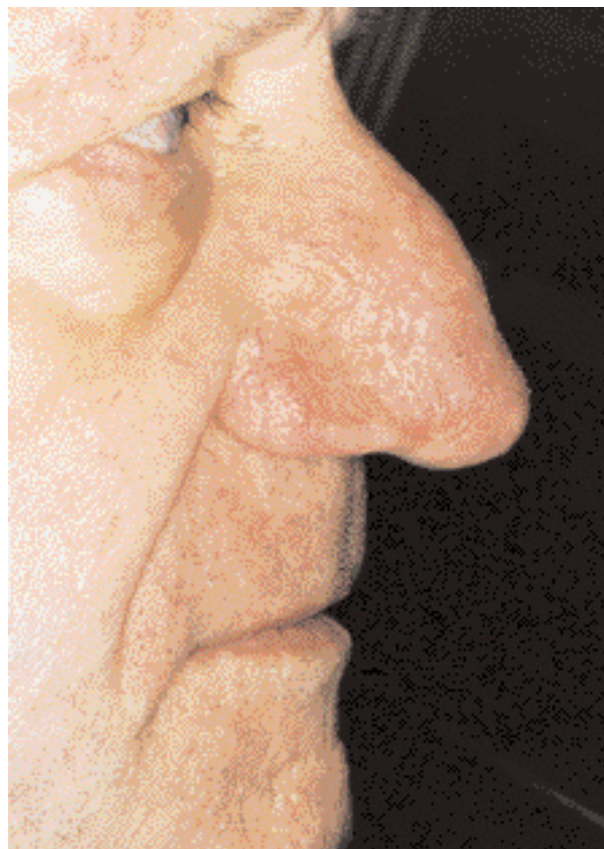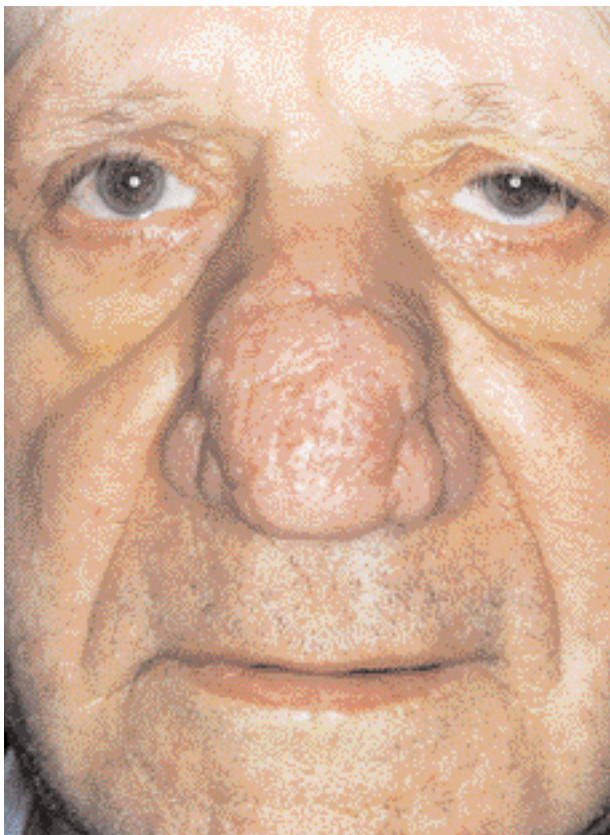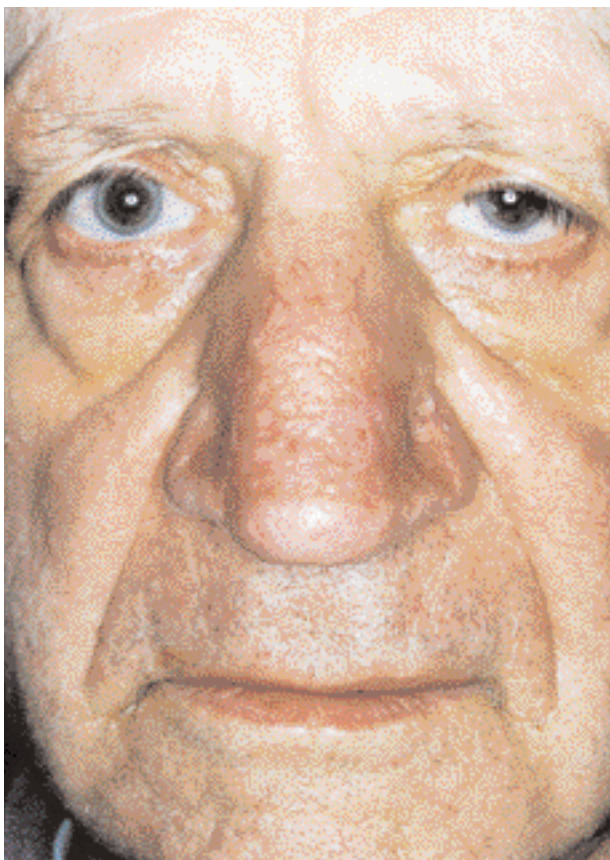Fig. 17.3.3 High-grade rhinophyma. The procedure is carried out in two sessions. In the first stage, the high-grade rhinophyma is transformed into a low-grade rhinophyma. A rectangular flap is sculpted and the underlying hyperplastic tissue is removed to uncover the cartilage. The flap is shortened and then sutured back in place. Programme data: **cut, 20 Watts, EM 10 Yellow** electro-manipule. Local anaesthesia.

(see over)





A month later, the nose is smoothed by progressive removal of hyperplastic tissue. This levelling is completed by means of timed surgical peeling. Programme data: **coagulation with microelectrodes, 20 Watts, EM 15** electromaniple. Local anaesthesia.



18 BIPOLAR COAGULATION OF SPIDER NAEVI

Programme data

Peripheral microtelangiectasias

Timed 5 hundredths of a second - or Direct pulsed 5/29 hundredths of a second - Coag microelectrodes - 7 Watts - EM 10 Green.

Programme data

Central vessel

Timed from 25 to 50 hundredths of a second - Coag microelectrodes - 7 Watts - Bipolar - 2 EM 10 Green (partially-sleeved).

Spider naevi are often seen on the face. They consist of a central dilated subepidermal vessel, sometimes slightly raised, which blanches with pressure and gives rise to numerous radiating microtelangiectasias (**Fig. 18.0.1**). The central vessel is connected to an artery ascending perpendicularly to the skin surface, and originates in the subcutaneous tissues (Ymayama 1980).

The treatment consists of eliminating the peripheral microtelangiectasias and coagulating the central vessel in depth, with several prolonged bipolar emissions.

Larger spider naevi, and those with a high-pressure central vessel (recognised by the rapidity with which the lesion refills after blanching by pressure), frequently recur after direct monopolar coagulation of the central vessel. This results from insufficient or too superficial coagu-

lation (the artery originates in the subcutaneous tissue), or is due to necrosis of the tissue caused by the coagulation of the central vessel. It may be hypothesised that during the healing process, owing to elevated haemodynamic pressure, the endothelium of the ascending artery covers the adjacent cavity created by the elimination of necrotic tissue, making a central vessel more superficial and visible. The recurrence may prompt more aggressive treatment, which leads to depressed and atrophic scars. Central vessels, require bipolar timed surgical treatment using two partially-sleeved **EM 10** electromanipules with approximately 2 mm of the tip exposed. The artery, which originates in the subcutaneous tissue, may be coagulated at this depth without producing visible residual scars.

The skin surface remains intact (Capurro 1984). In the case of incomplete response, further treatment can be carried out after a few days. This technique normally requires local anaesthetics.

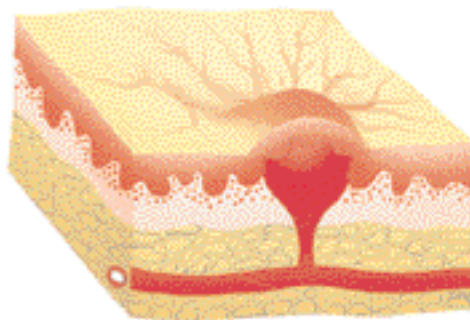
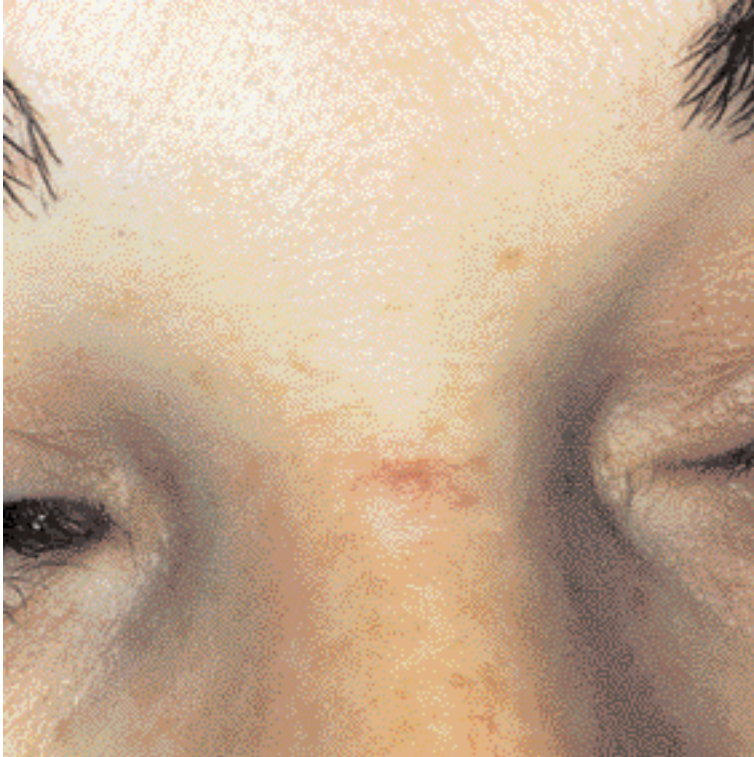

Fig. 18.0.1 Spider naevi are channels from an ascending artery which originates in the sub-cutaneous tissue.

18.1 Technique

Positioning the neutral electrode in contact with the patient's skin, the operator sets the Timed apparatus to the timed mode with an emission time from **3 to 5 hundredths of a second**, the function to coagulation with microelectrodes and the power to **7 Watts**. An **EM 10 Green** electromaniple is used, or, in the case of a very large spider naevus, an **EM 10 Grey**. The peripheral capillaries are eliminated with micro-coagulations spaced about one millimetre apart. (**Fig. 18.1.1**). The operator proceeds from the periphery toward the central vessel, which is not coagulated and therefore remains visible, even if the area becomes oedematous. The central vessel indicates the site of the ascending artery and the exact point at which the deep bipolar coagulation is needed. At the end of this first phase of treatment, the operator inserts the bipolar cable, which automatically deactivates the return electrode, attaches the two partially-sleeved **EM 10 Green** electromaniples and sets the emission time to between **25 and 40 hundredths of a second**. The points of the electromaniples must converge at a depth corresponding to the origin of the ascending artery: the operator should check the treatment effects visually after delivering one or two emissions (**Fig. 18.1.2**). The first emission produces local oedema, which brings the walls of the artery into contact with each other; the electromaniples are then repositioned cross-wise from six to ten times to complete the electro-coaptation of the vessel (**Fig. 18.1.3**).

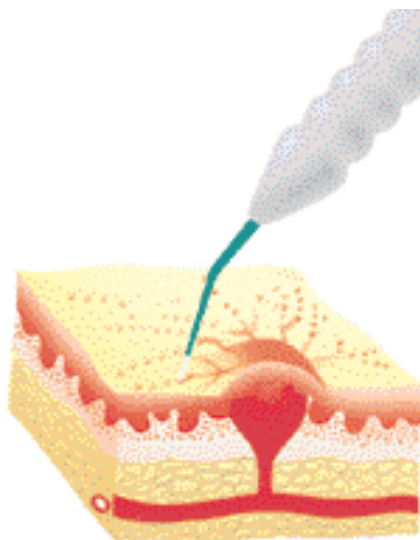
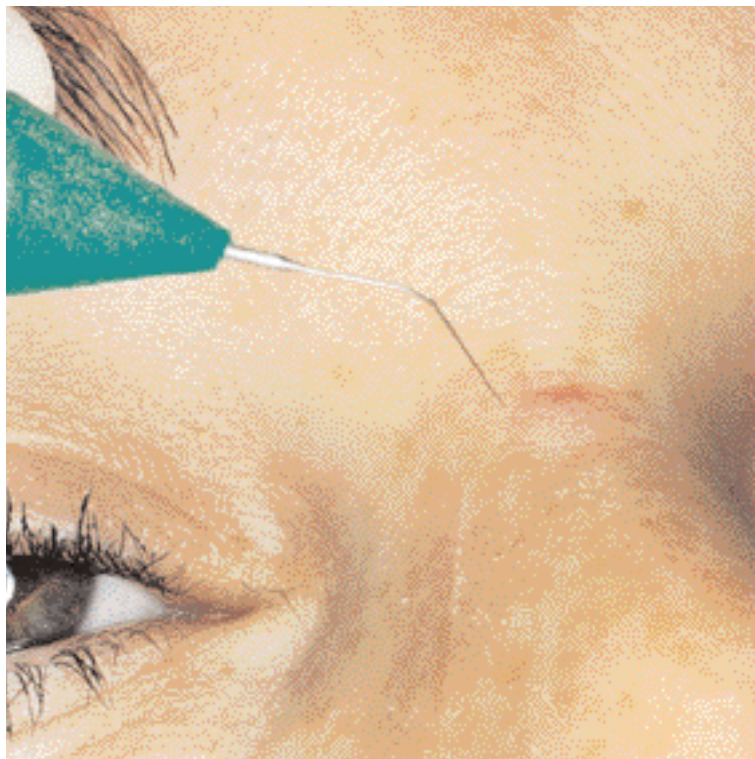


Fig. 18.1.1 The fine capillaries that radiate from the central vessel are eliminated with micro-coagulations, working from the periphery toward the centre. Programme data: **coagulation with microelectrodes, 7 Watts, 5 hundredths of a second, EM 10 Green** electromaniple. Local anaesthesia.

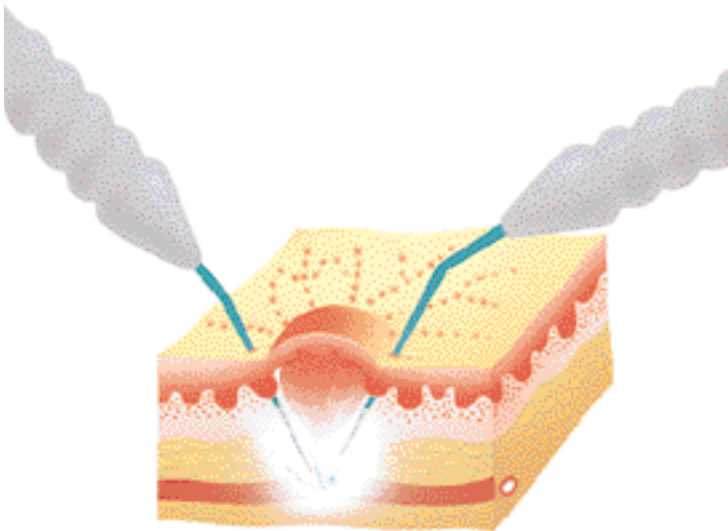
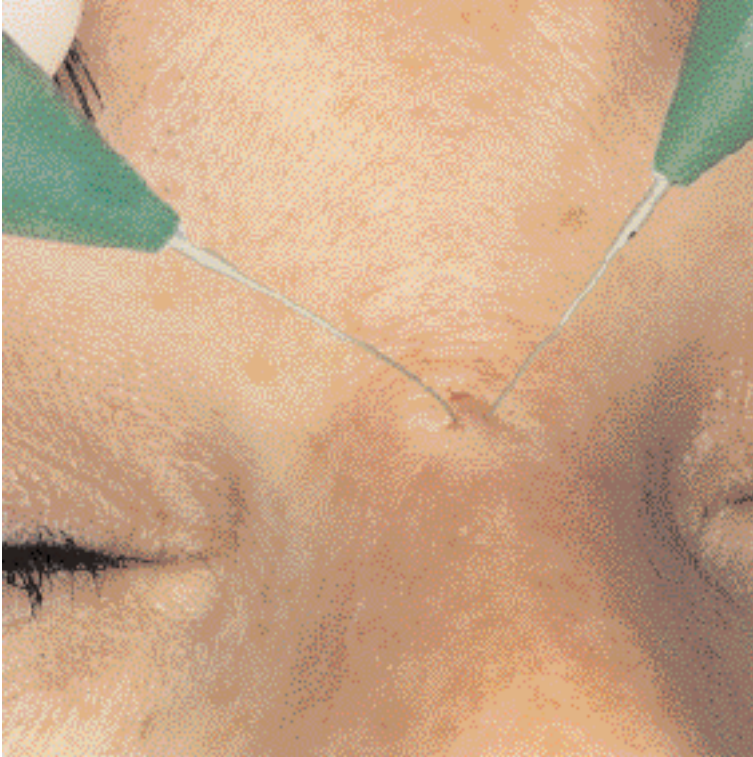

Fig. 18.1.2 The ascending artery is coagulated with a timed bipolar emission. Programme data: coagulation with microelectrodes, 7 Watts, 35 hundredths of a second, 2 EM 10 Green electromaniples (partially-sleeved).

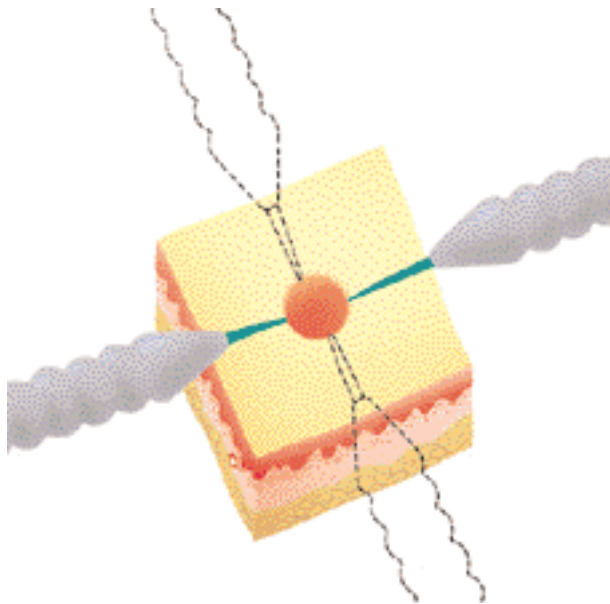
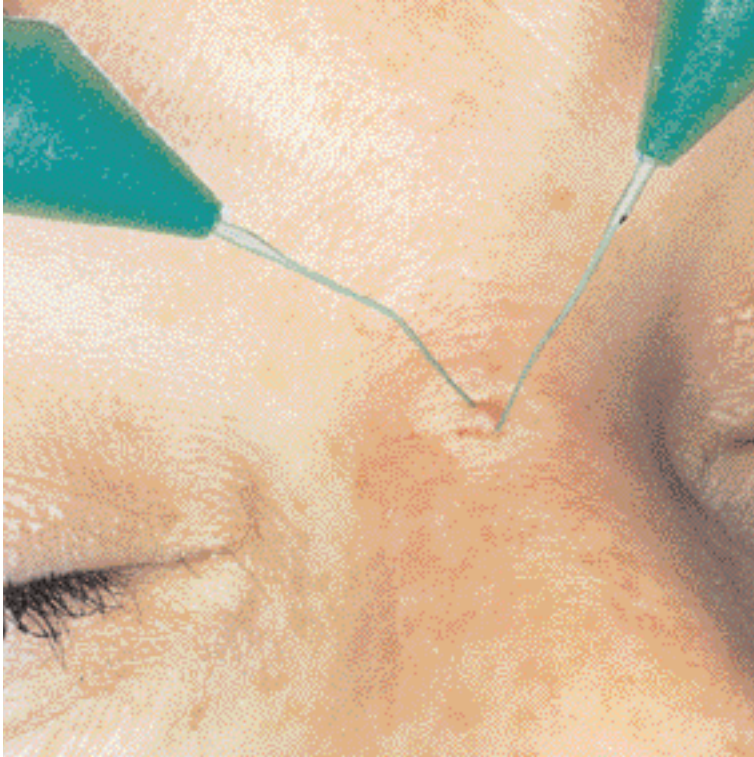


Fig. 18.1.3 A series of bipolar coagulations across the ascending artery completes its electro-coaptation.

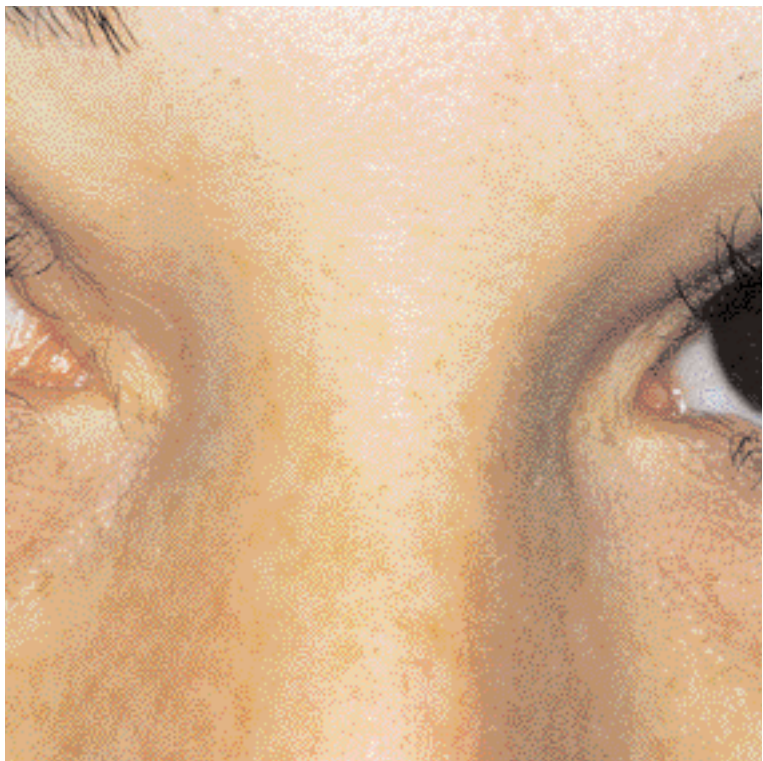

Fig. 18.1.4 Result. The timed bipolar coagulation allows the central artery to be attacked in depth, where it originates, without damage to the skin surface.

Tab. 18.1 Advantages of the timed surgical bipolar technique

Absence of scars on skin surface
Localised precise coagulation of vessel in subcutaneous tissues.
Electrocoaptation of vessel.
Possibility of repeating procedure after a few days if the initial treatment proves incomplete.

During emission, the points are very close together; they must be positioned on either side of the vessel to be coagulated but must not touch each other. Should the electromaniples touch, the circuit will close and no coagulation of the tissues will be obtained. The programming is correct when bipolar emission is followed by an immediate oedema, accompanied by the characteristic sound, in the area between the two electromaniples. The procedure requires both the right power and emission time. The values indicated are usually sufficient to obtain the desired results (**Fig. 18.1.4-5**).

When the epidermis is thick, insertion of the electromaniples is facilitated if an emission is generated simultaneously. During repositioning of the electromaniples, one of these remains in the tissue while the other is extracted and re-inserted, until coagulation of the ascending artery is complete. The tip of the electromaniples must be perfectly clean to ensure good conduction of current. If the conducting surface is small, it may be necessary to increase the emission time.

After the procedure, compression is applied.

The timed surgical bipolar technique (Tab. 18.1) allows aesthetic results to be obtained even with spider naevi of large dimensions.

Following elimination of high pressure spider naevi of the face, a few fine telangiectatic capillaries may appear at a distance of a few centimetres. These are easily eliminated.

The patient should be seen after two weeks. By using finger pressure, the operator must check that the ascending artery is closed and look for any residual microtelangiec-

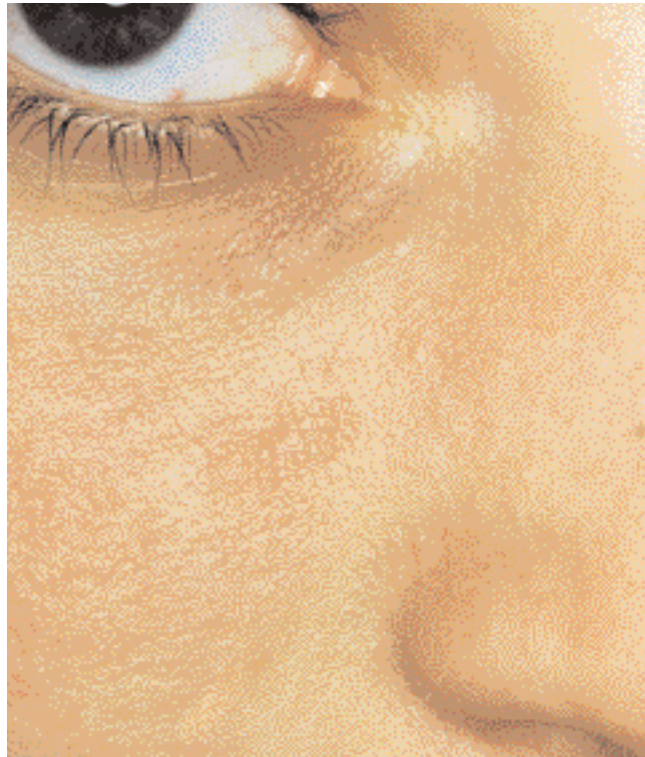
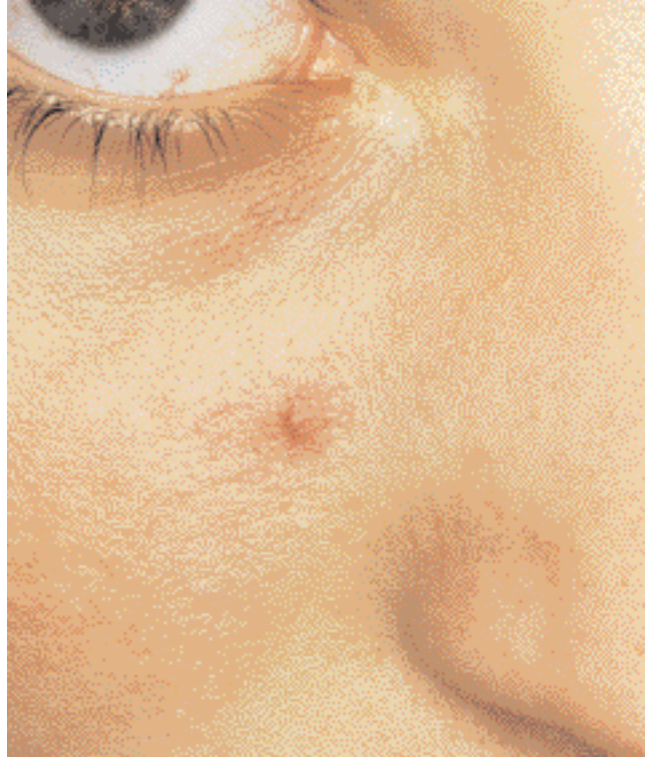
Fig. 18.1.5 Timesurgical treatment of spider naevus. Programme data monopolar session: coagulation with microelectrodes, 7 Watts, 5 hundredths of a second, EM10 Grey electromaniple. Programme data bipolar session: coagulation with microelectrodes, 7 Watts, 25 hundredths of a second, 2 EM 10 Grey electromaniple (partially-sleeved).

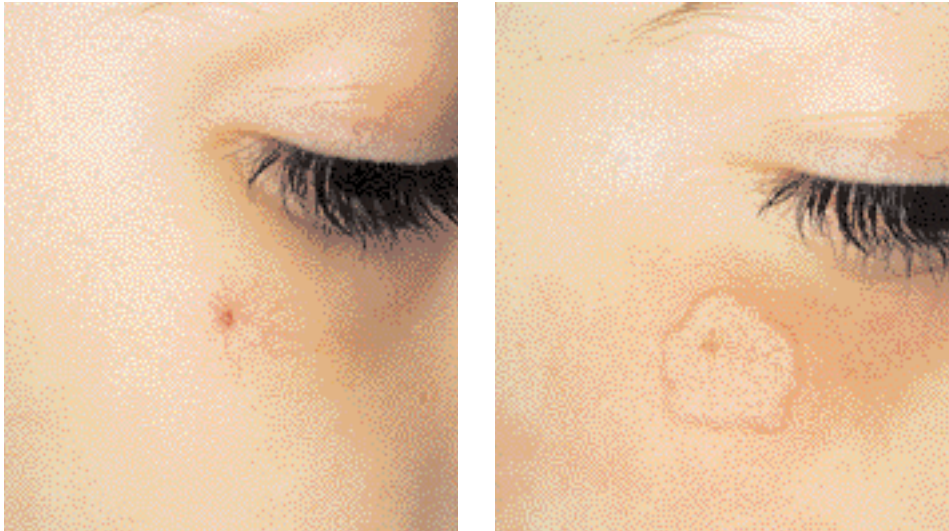

Fig. 18.1.6 After micro-coagulation a slight cutaneous oedema appears. This resolves in a few hours.

tasias with a magnifying glass. The efficacy of the treatment cannot be determined immediately, owing to the occurrence of oedema (**Fig. 18.1.6**). If a central artery is still present, it should be retreated with monopolar or bipolar microcoagula-

tion. Only by eliminating this, is it possible to obtain permanent results. After bipolar coagulation, a slight subcutaneous swelling may occur, which disappears in a few weeks. Complications are rare (Tab. 18.2).

Tab. 18.2 Complications after timesurgical treatment of spider naevus

Problem	Cause	Solution
Recurrence	Insufficient lysisive action	Further intervention
Hyperpigmentation	Exposure to UV rays	Protect area with anti-sun cream; superficial timesurgical coagulation
Formation of new telangiectasias at a distance	Elevated haemodynamic pressure	Eliminate capillaries with monopolar timed emissions
Scar	Infection; incorrect position of electromaniples	Excision; timesurgical resurfacing to complete healing

19

TREATMENT OF VENOUS LAKES, VARICES AND MUCOUS CYSTS

Programme data

Direct - Coag microelectrodes - 10 Watts - EM 10 Yellow

Timedsurgery is able to rapidly eliminate venous lakes (**Fig. 19.0.1**), mucus retention cysts and varicose formations of the oral cavity.

The Timed apparatus is set to the direct mode, the function to **coagulation with microelectrodes** and the power to **10 Watts**. An **EM10 Yellow** electromaniple is used. Having administered local anaesthesia, the operator inserts the point of the electromaniple into the centre of the formation to be coagulated.

The electromaniple must be held still, as lateral movements could cause laceration.

The emission lasts until the liquid inside the cyst starts to boil, thus conveying the heat to the walls. If the formation is raised, the operator carries out a series of suitably-spaced coagulations (**Fig. 19.0.2**).

The coagulated mucosa has a bluish-white appearance, with blackening due to carbonisation at the point of entry of the electromaniple.

Varices of the oral cavity are frequent in the elderly, and may require treatment to prevent haemorrhage or relieve interference with dental prostheses.

Mucus retention cysts may also be treated by means of this technique.

These occur on all parts of the buccal mucosa but are most frequently seen on the lower lip, where they have a blue colour. Unlike angiomas, mucus retention cysts do not reduce on pressure.

Postoperative healing is rapid.

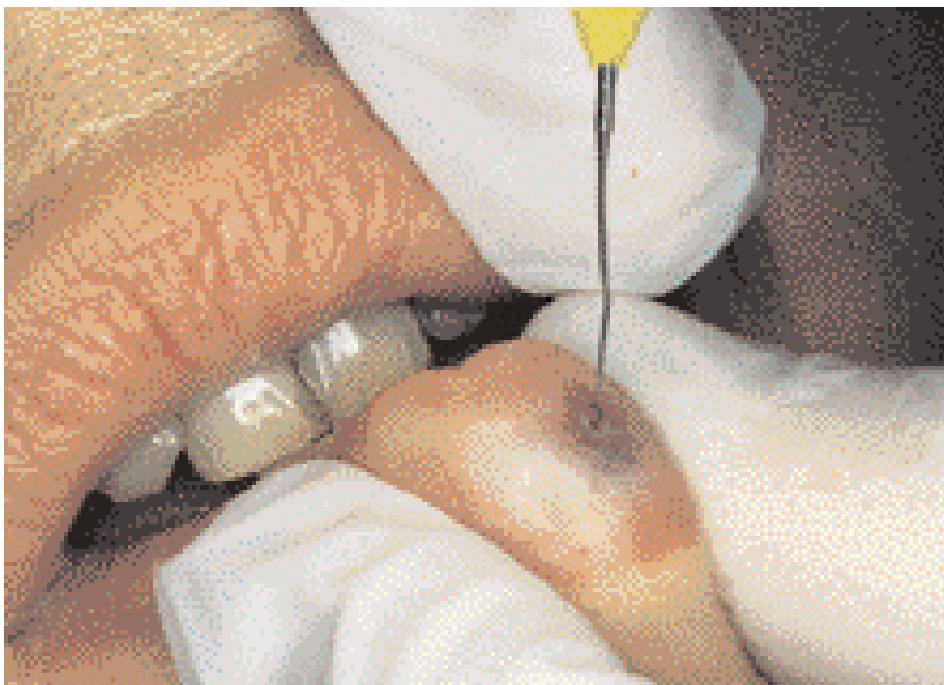
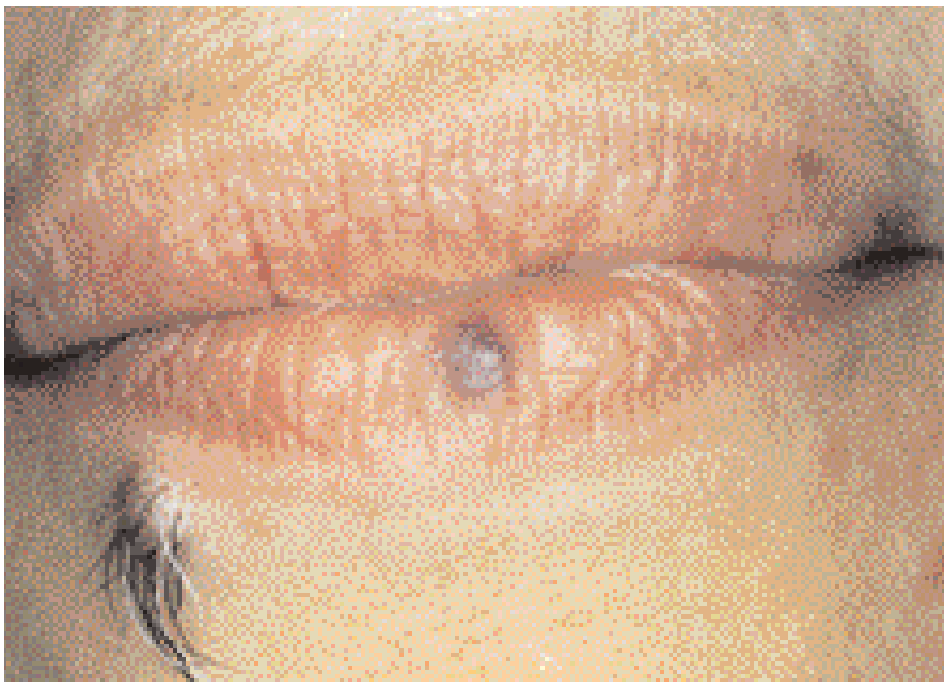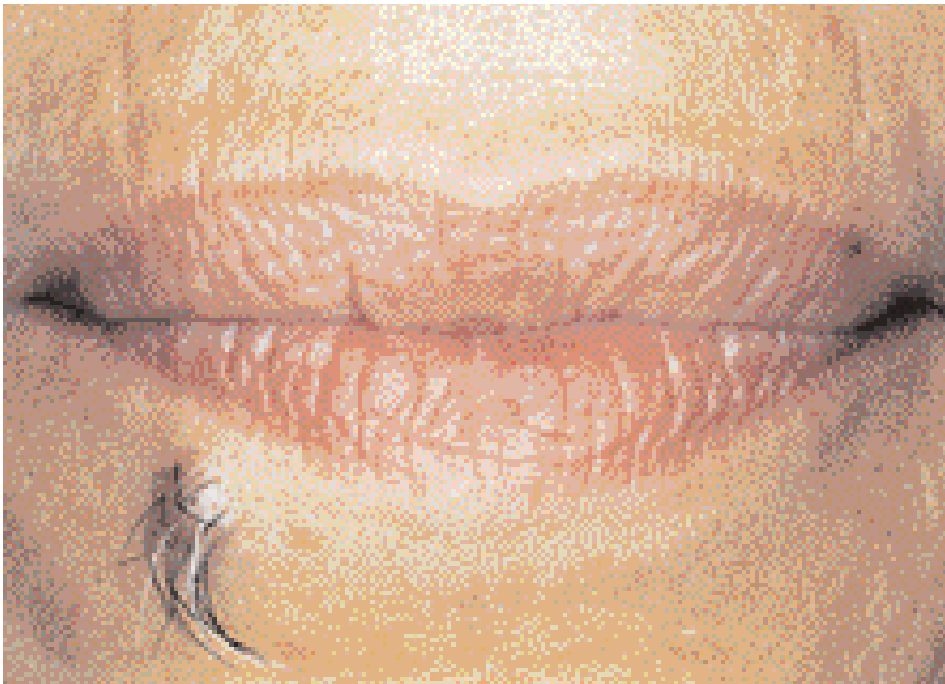
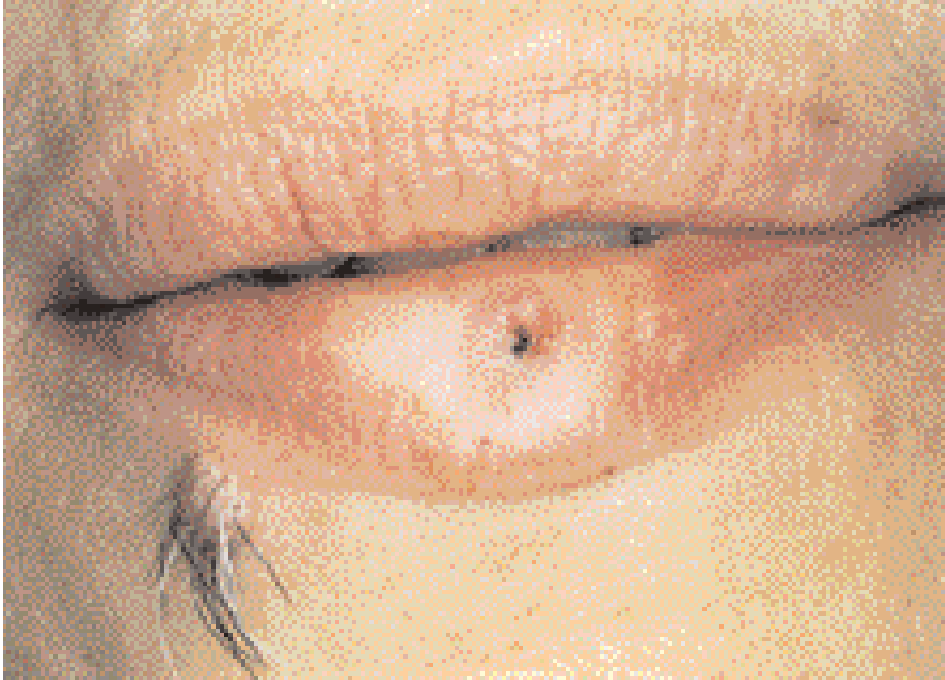


Fig. 19.0.1 Venous lake. The tip of the electromaniple is inserted into the lesion and a prolonged emission is generated. Programme data: **coagulation with microelectrodes, 10 Watts, EM 10 Yellow** electromaniple. Local anaesthesia. *(see over)*



Immediately after coagulation of the venous lake (top). Result after one month (bottom) .

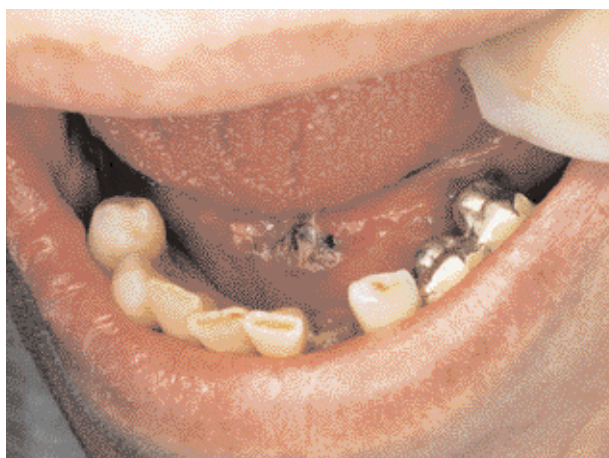
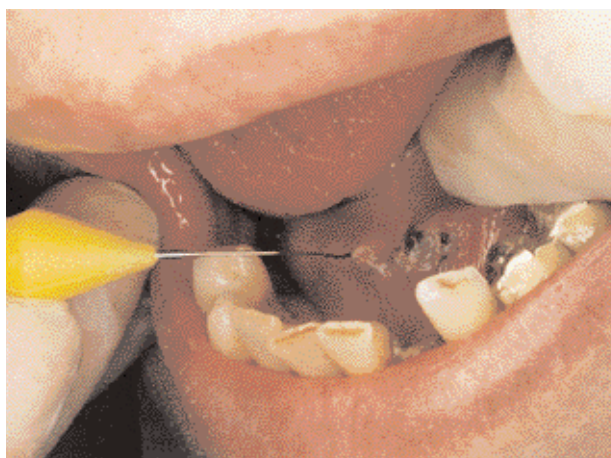
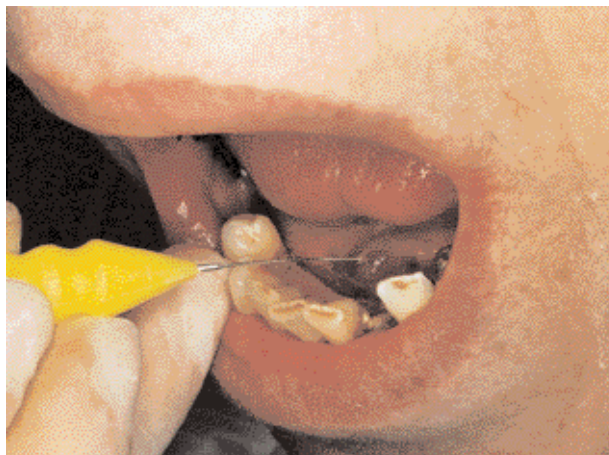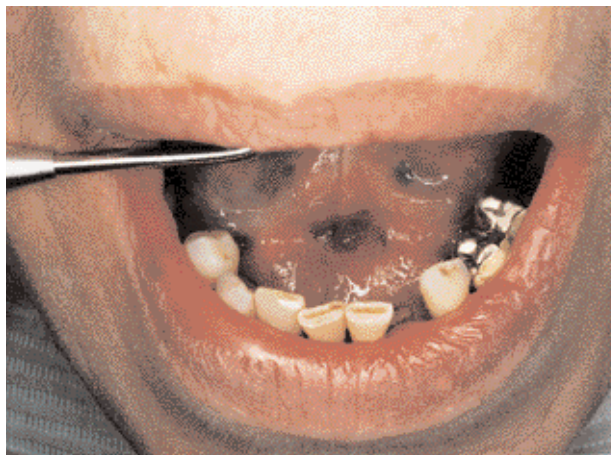

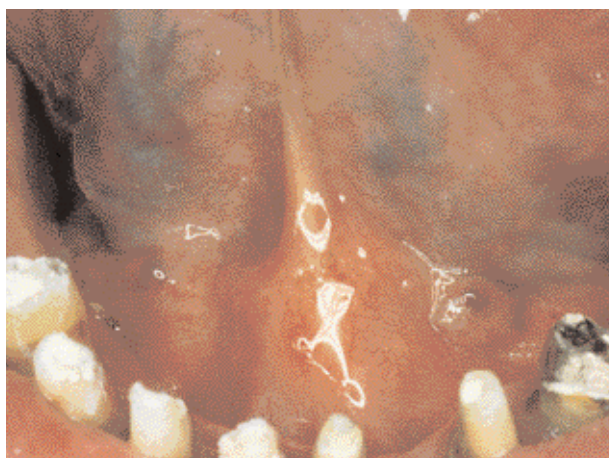
Fig. 19.0.2 Varices of the floor of the mouth. Emission is generated after the operator has inserted the point of the electromaniple into the varix. Emission continues for a few seconds, until coagulation of the varix is complete. Local anaesthesia. Programme data: **coagulation with microelectrodes, 10 Watts, EM 10 Yellow** electromaniple.



20

TREATMENT OF ECTATIC VESSELS OF THE LOWER EXTREMITIES

Varicose veins and telangiectasias of the lower limbs are a frequent disfigurement (**Fig. 20.0.1**) and may be due to constitutional, hormonal or traumatic causes (Tab. 20.1).

To achieve good aesthetic and functional results there is only one realistic treatment: three-dimensional regional sclerotherapy.

Physical methods are unsatisfactory. Galvanic current is slow and its action too limited. Traditional electrosurgery carries a risk of residual scarring,

and laser treatment is inefficacious. With physical methods it is possible to treat small visible vessels, but not non-visible veins, which are ectatic and incompetent.

If the dilated vessel wall is subjected to an abnormal haemodynamic pressure, the problem will recur after some types of treatment including sclerotherapy if it is only two-dimensional, that is to say if its action is limited to the vessels that the operator can see.

Tab. 20.1 Causes of growth of ectatic vessels of the lower limbs

A) Hereditary
B) Oestrogen and progesterone
C) Gender, Weight, Height, Posture, Occupation, Aging
D) Dilation and elongation of veins
E) Valvular incompetence
F) Venous Hypertension
G) Venous insufficiency
H) Deep thrombosis
I) Trauma

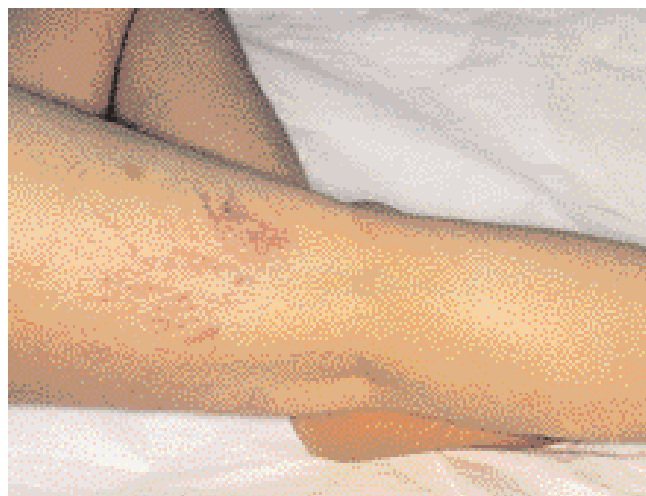

Fig. 20.0.1 Ectatic vessels of the lower limbs.

20.1 Sclerotherapy

Sclerotherapy consists of injecting a sclerosing solution into the ectatic veins until the vessel has completely disappeared, the chemical irritant producing an inflammatory reaction and subsequent fibrosis of the vessel.

A good technique and the use of very fine needles enable the solution to be injected into the small telangiectasias. All ectatic veins of the lower limbs may be treated in this way.

Sclerotherapy must not be used in patients at risk of thrombophlebitis or during pregnancy.

Sclerotherapy is repeated weekly until the ectatic veins disappear.

Equipment

The equipment consists of a 2.5 or 3 ml syringe with a short fine needle, 0.30 mm in diameter (30 gauge $1/2$), which the operator bends (**Fig. 20.1.1**), cotton wool, disinfectant, and sclerosing solution.

Sclerosing solutions

Numerous sclerosing solutions exist and each operator has his preference. In each case, the weakest effective concentration is preferred, as stronger preparations may lead to permanent post-sclerotherapy hyperpigmentation or matting, and may cause necrosis of the skin if accidental extravasation occurs.

In visible venous and capillary ectasia, a gentle, gradual constriction of the lumen must be produced, until it completely disappears.

Fibrotic degeneration of the walls of the varicose veins occurs and a cord of connective tissue forms, as a result of which the vessels are no longer visible.

The degree of endothelial damage caused by the sclerosing agent must be well controlled: in more superficial vessels (i.e. telangiectasia) too potent a solution blocks entry of the solution to the perforating veins and causes extensive damage, which can lead to thrombosis.

If thrombosis does occur, the coagulated blood should be removed through small needle punctures in the vessel walls (**Fig. 20.1.2**).

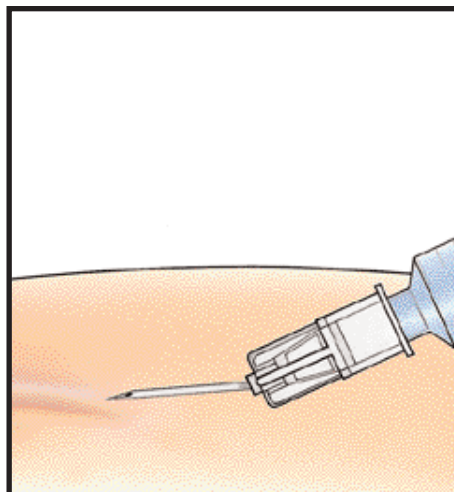


Fig. 20.1.1 The needle is bent for easier insertion into the ectatic vessels.

Thromboses are easily recognised, as the vein becomes dark blue and does not lighten under pressure from a finger. If the destructive action is more marked, micro-ulcers form and cracking of the walls occurs, resulting in leakage of blood; this problem and a severe inflammatory response are responsible for the hyperpigmented changes which may develop after sclerotherapy (Tab. 20.2).

Chromated glycerin (Scleremo) induces gradual sclerosis in the capillary vessels. It causes little tissue damage even if it seeps into the surrounding tissues as a result of incorrect injection.

Thromboses are rare and only occur in veins of larger diameter. Post-sclerotherapy hyperpigmentation is also rare.

Chromated glycerin is excreted through the kidneys and it is recommended that no more than 10 ml of solution per week be injected.

If this volume is exceeded, micro-haematuria may occur. Chromated glycerin solution must not be used

in patients who are allergic to chrome (Ramelet A.A. et al. 1995) and nickel, small amounts of which are contained in trivalent chrome salt.

Allergy to nickel is becoming increasingly common and affects 50% of the population (Capurro 1993).

Local reactions involving reddening and persistent oedema have been seen more frequently. Such complications do not normally appear during the first session, but during subsequent ones.

Hypertonic saline solution from 20% to 30% causes pain and muscle cramps on injection; these may be lessened by adding 0.5 ml of 1% lidocaine to every 3 ml of sclerosing solution.

Immediately after injection, blood returns to the vessels, but in a few seconds there is an inflammatory reddening followed by a perivascular oedema, which makes the telangiectasias lift slightly from the surface of the skin.

The erythema lasts for a few hours and the sclerosing action is very rapid, being completed in one or

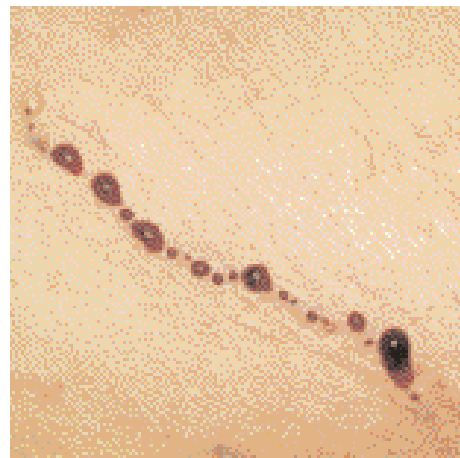
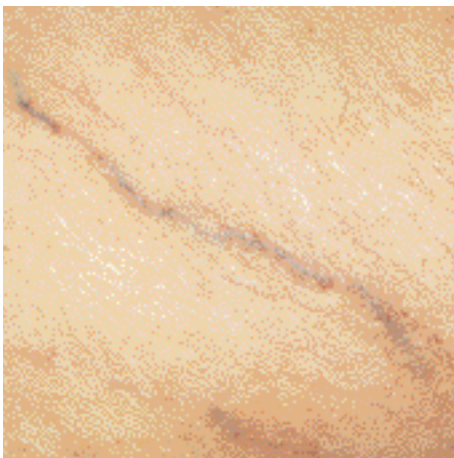
Fig. 20.1.2 Thrombosed vessels are repeatedly punctured with the same size needle as used for sclerotherapy and the blood is withdrawn manually.

Tab. 20.2 Complications of traditional sclerotherapy

Problem	Cause	Solution
Marked cutaneous reddening *	Local hypersensitivity	Change sclerosant. Anti-inflammatory gel.
Capillary thrombosis **	Strong irritant action.	Puncture the vein from side to side. Use a less aggressive solution .
Post-sclerotherapy hyperpigmentation	Solution too aggressive. Abnormal inflammatory process. Splitting of walls of endothelium and deposition of iron pigment.	Depigmentary agents. Use a less aggressive solution (e.g.: Bisclero 6% or 8%).
Matting	Haemodynamic causes. Abnormal inflammatory process.	Three-dimentional regional bisclerotherapy.
Necrosis	Extravascular injection of strong solution due to operator error or broken vessel.	Inject physiological saline immediately. Medication. Timedsurgical cleansing.
Phlebitis	Development of thrombi after sclerosis in predisposed patients.	Elastic compressive bandage. Avoid treatment of such patients.
Sclerotherapy-resistant telangiectasias	Small area of contact and high haemodynamic pressure.	Three-dimensional regional bisclerotherapy. Bisclero 10%. Timedsurgical treatment.

* Slight cutaneous reddening is normal * * The presence of a few venous thromboses is normal

two weeks. If the dosage is incorrect, there may be residual pigmentation. Hypertonic saline must always be injected into the vessel, as extravasation causes cutaneous necrosis. Often, even with correct injection, a small quantity of solution leaks from the injection site, causing localised necrosis. It is helpful, when removing the needle from the skin, to withdraw the plunger slightly in order to prevent the solution coming into contact with the tissue. If the hypertonic solution does extravasate, the effect can be lessened by injecting 0.5 ml of physiological saline into the area.

In elderly patients and those with fragile capillaries, the injection of physiological solution at the injection site is routine practice.

Hypertonic saline rarely produces intravascular thrombosis in telangiectatic capillaries, though this phenomenon is more frequent in veins. Injection of saline must be rapid, since the immediate development of perivascular oedema impedes progression of the liquid after a few seconds.

The saline has an immediate action but is rapidly diluted by the circulating blood, and loses its efficacy.

Sodium tetradecyl sulphate (Trombovar) has a very marked action and must be diluted (0.25% to 0.5%). Allergic reactions and anaphylactic shock have been reported.

It frequently causes thrombosis and pigmentation and, if extravasation occurs, cutaneous necrosis.

Polydocanol (0.5 to 3% - Aethoxysclerol) is the sclerosant most frequently used in Europe for venous sclerosis. With telangiectasias, especially in elderly patients, it often produces intravascular thrombosis and

pigmentation. It is preferable not to inject in perivascular sites, especially in the most distal areas of the lower limbs, where cutaneous necrosis may occur.

Sodium salicylate (12% to 20%) is painful and must be used with local anaesthetic. This solution must be injected into the vessel, as extravasation causes cutaneous necrosis.

In aesthetic sclerotherapy, it is essential to avoid causing necrosis, pigmentation or matting.

Since the most commonly used sclerosing agents were formulated before the demand for such aesthetic results arose, they do not guarantee a successful outcome.

Recently, we have used a small quantity of sodium salicylate in a hydroglyceric buffered solution (Bisclero), obtaining an efficacious sclerosing action with excellent tolerance both locally and generally (Capurro 1992).

There are two Bisclero (BS) solutions: 6% and 10%. By mixing equal amounts of 6% and 10% solution, the operator can obtain an 8% solution.

The scant inflammatory effects of Bisclero allow a greater quantity of solution to be delivered by each injection (up to 2 ml). The large amount of solution (from 12 to 21 ml BS 6% or BS 8%) that can be injected enables three-dimensional regional sclerotherapy to be performed. Very stable sclerosis is therefore achieved.

With Bisclero, the sclerosis is safe, reliable and reproducible. Bisclero rapidly resolves cases which traditional sclerotherapy cannot resolve. It also replaces out-patient phlebectomy and eliminates the venous ectasias that remain after surgical saphenectomy.

Thromboses are rare and no permanent pigmentation or matting takes place.

Owing to the above-mentioned properties, the Bisclero solutions are ideal for aesthetic and functional sclerotherapy.

20.2 **Three-dimensional regional bisclerotherapy**

The technique for using Bisclero solutions is different from that of other sclerosing drugs.

With the patient lying on a bed, the operator disinfects the skin and, concentrating on one anatomical region (e.g. lateral lower limb), injects in the same sitting all the vessels present, starting from the foot and working upward towards the thigh or viceversa (**Fig. 20.2.1**).

If no veins are visible in the foot, the Bisclero is injected into the first reticular vein visible and is squeezed towards the foot with the aid of a wet cotton swab.

The reticular veins often appear as a slight difference in colour on the surface of the skin and constitute a pathway for the solution to reach the perforating veins.

Compared with other solutions, a larger quantity of Bisclero must be injected (normally 12 or 15 ml). The injection of a large quantity of solution into the same region has a three-dimensional action and "tones up" the ectatic vascular network. The reduced pressure on the vessels makes for rapid stable results.

In conclusion, three-dimensional regional bisclerotherapy not only ensures the rapid and safe disappearance of the veins, venules and visible telangiectasias, but also ena-

bles incontinent perforating vessels to be "regenerated", thus making them continent once again. In addition to its curative and aesthetic effects on the full-blown disorder, three-dimensional regional bisclerotherapy has an efficacious preven-

tive effect in mild cases (**Fig. 20.2.2**). This is very important in a disorder which tends to evolve, such as varicose disease. These results are achieved without complications, without costly Doppler equipment, and without the inflammation and

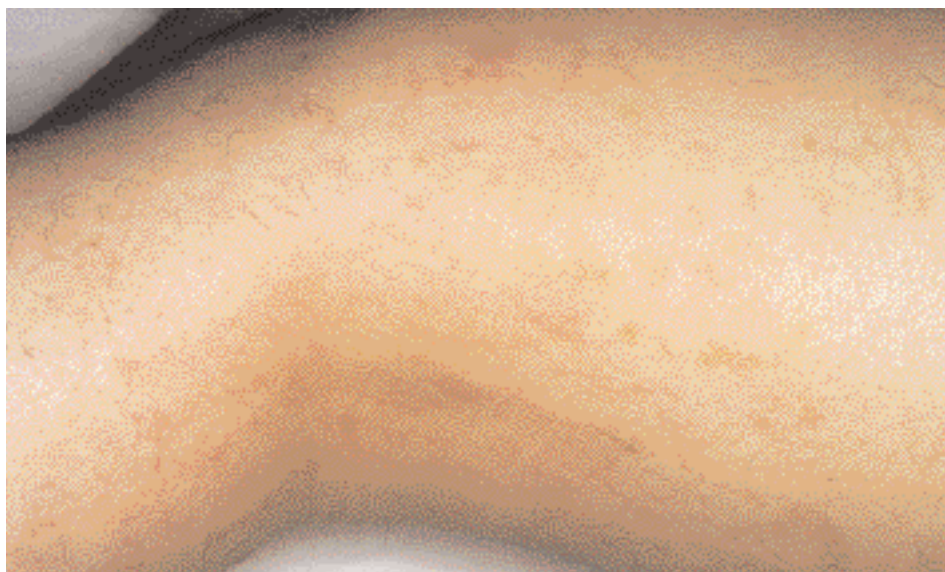
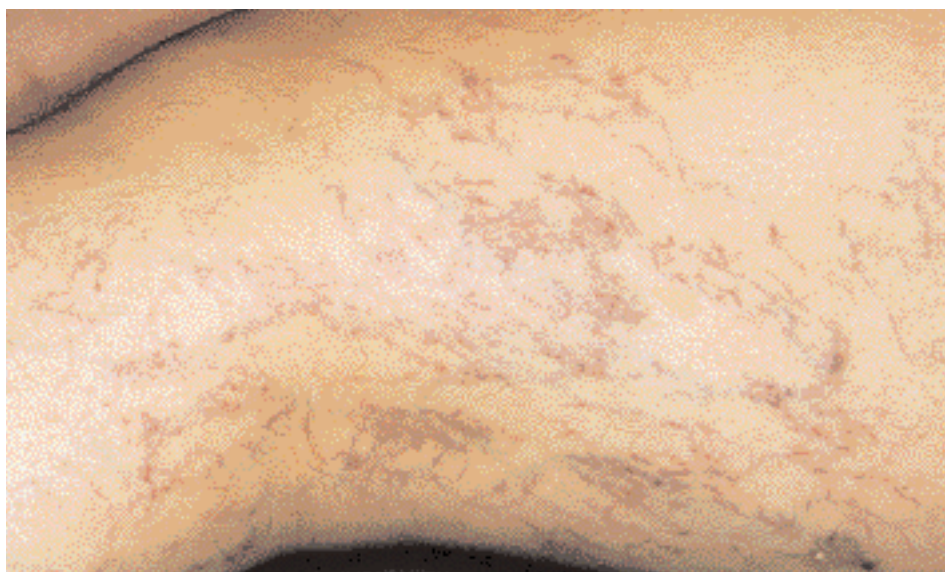


Fig. 20.2.1 Three-dimensional regional bisclerotherapy. In the first two sessions, 30 ml of 8% Bisclero was injected. In the third session, 5 ml of 10% Bisclero was injected.

pain that other sclerosing solutions cause even when injected in extremely small doses .

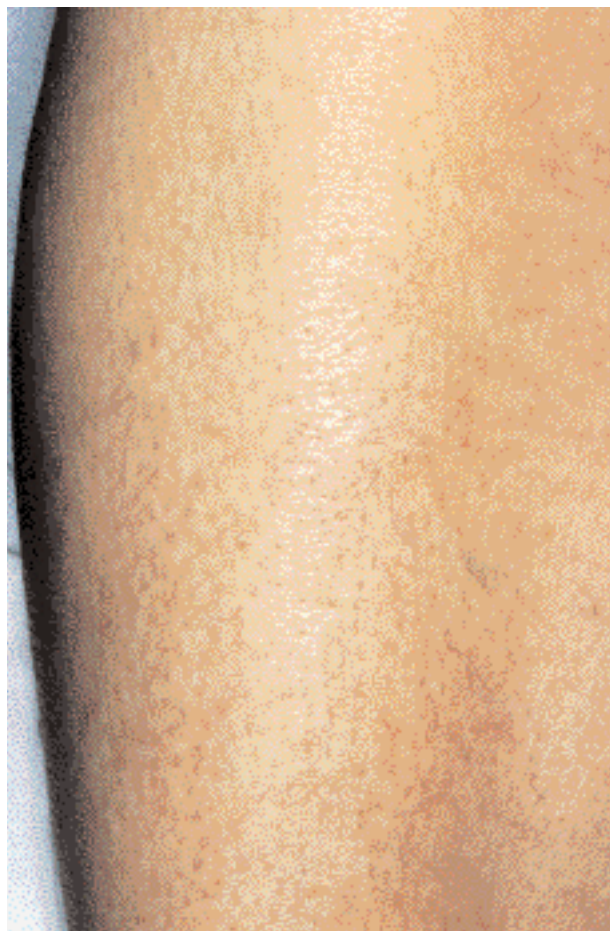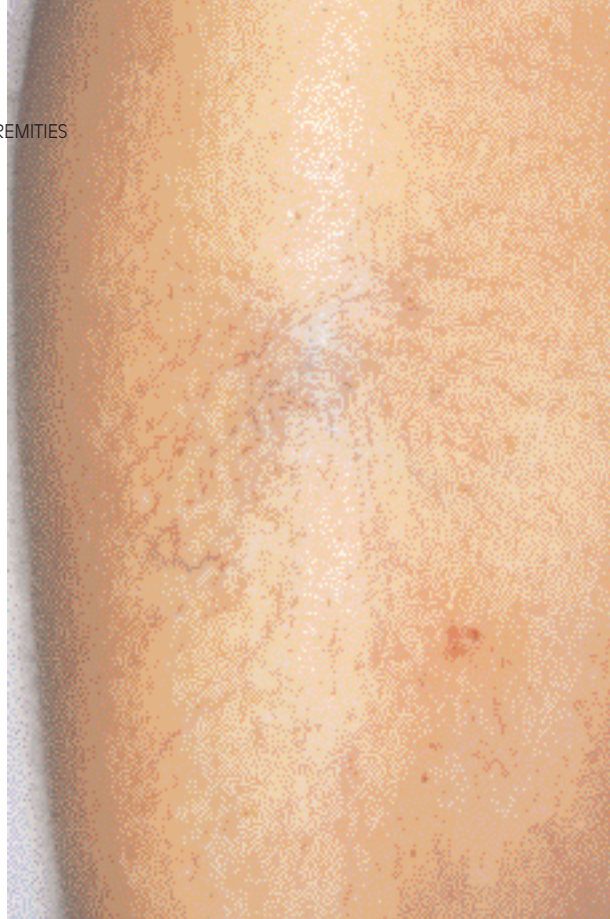
The three-dimensional nature of the sclerosing action will become clear when a telangiectasia a few millimetres in length "requires" 1 ml of solution.

In sclerosis of reticular veins, which are often difficult to see, the operator will detect a sensation of emptiness when the needle is inserted. Indeed, if the tip of the needle is not in the lumen of the vessel, the plunger of the (2.5 or 3 ml) syringe will encounter considerable resistance owing to the viscosity of the solution. By contrast, if the needle enters the reticular vein, the plunger will offer no resistance. The operator should always press the injected solution along the vessel, with the aid of a cotton swab soaked in benzalkonium chloride, so that it comes into contact with the maximum surface of the ectatic endothelium. Regeneration must involve the entire superficial and perforating network, and not only the clearly affected, individual segment.

In the treatment of telangiectasias, correct insertion of the needle is shown by a clearing of blood out of the vessel during injection. If the injection is not intravascular, a blob immediately forms and blood does not clear from the vessel.

The technique of inserting the needle is subtle and must be perfected through continual practice. The syringe is held in one hand (**Fig. 20.2.3**). The needle is positioned

Fig. 20.2.2 Three-dimensional regional biscalrotherapy. Result after two sessions. The large amount of 8% Bisclo injected eliminates the pressure exerted on the superficial vascular network by an incontinent perforating vein.



parallel to the skin surface, between 2 mm and 5 mm from the intended point of entry into the vessel.

Penetration of the lumen of the vessel is achieved with little movement, by increasing the angle of the syringe by a few degrees from the tangential position.

The needle lumen must be completely within the vessel in order to avoid leakage. Even very fine capillaries can be injected.

As a large area cannot be treated with a single injection, it is necessary to inject correct quantities of solution into many sites until the network of regional vascular ectasia is covered (**Fig. 20.2.4**).

If the pressure falls, the injection is continued up to 0.5-2 ml. This signifies that the liquid has reached an incompetent vein, which must be "sclerosed" because it supplies the visible telangiectasia and, if not "regenerated", may give rise to new ectatic capillaries or delay the sclerosis of those already treated. The larger amount of Bisclero injected and distributed within the superficial network reaches the perforating incompetent vessels, rendering them continent. No thrombosis of these vessels has ever been observed. As it does not give rise to thromboses, three-dimensional regional bisclerotherapy is safe.

If some microtelangiectasias are still visible after three or four sessions of three-dimensional bisclerotherapy performed in the same region, they can be obliterated with a small amount of 10% Bisclero.

These ectatic vessels will disappear from view immediately and permanently. This is due to the fact that the superficial venous network and the perforating veins have become continent again. In this phase of the treatment, there is no longer any reason to keep the ectatic capillaries patent; in the early sessions, they

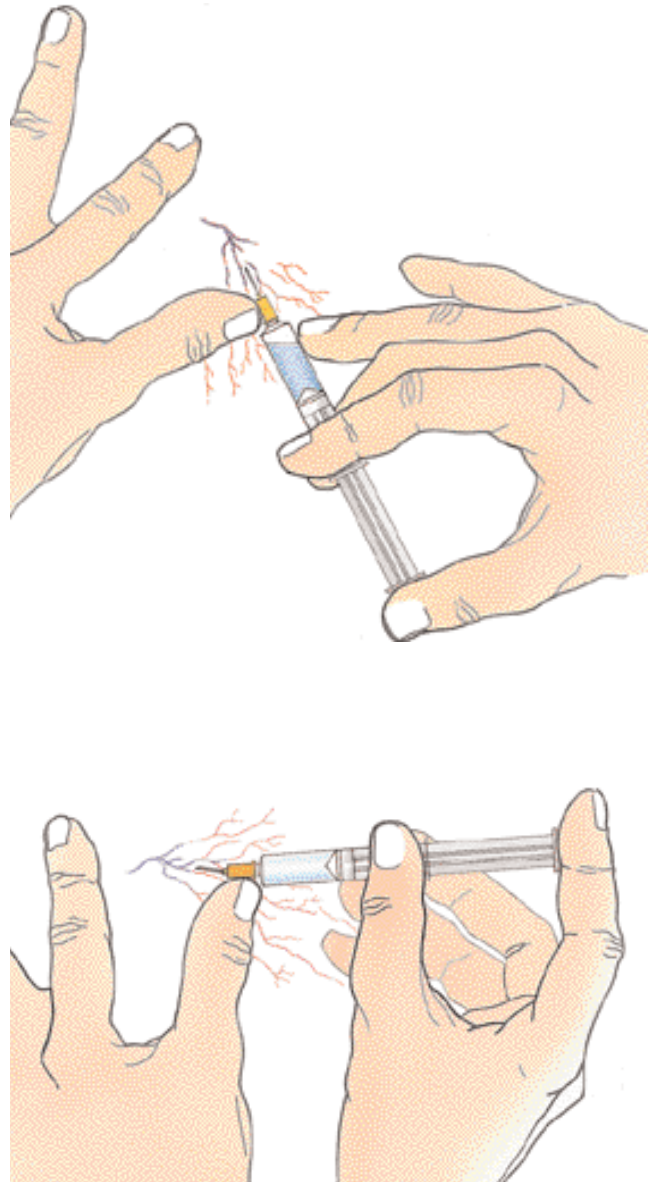


Fig. 20.2.3 The syringe should be held in one hand. To inject the telangiectasias, a concentrated beam of light and a magnifying lens are needed; for the reticular veins, diffuse light and no lens.

Tab. 20.3 Guidelines for three-dimensional regional bisclerotherapy

- 1) A single anatomical region is selected, and all the veins, venules and telangiectasias present are injected, starting from the foot and working up to the thigh joint (or viceversa). If no veins are visible in the lowest third of the leg, the solution is injected into the first reticular vein visible and squeezed towards the foot with the aid of a cotton swab soaked in benzalkonium chloride
- 2) An initial concentration of 6% Bisclero is used
- 3) If resistance to injection is high, the solution is injected slowly in small amounts; if the resistance is low, the solution is injected rapidly in large amounts
- 4) At each single injection, as much solution as the vessel with take (up to 2 ml) is injected
- 5) Normally 12 or 15 ml is injected (up to 21 ml)
- 6) A very small amount of lidocaine is added to the Bisclero
- 7) The needle must be substituted once or twice during the procedure
- 8) After sclerotherapy an anti-inflammatory agent is applied to the treated area. The patient remains immobile on the bed for 5 minutes
- 9) The patient puts on elastic stockings
- 10) In the following sessions, the occasional thromboses present are pierced
- 11) The medial region is injected first. A week later, the posterior region is injected, followed by the lateral region, again after one week. In the fourth week, the sequence begins again.
- 12) One limb is treated completely, followed by the other
- 13) If resistant microtelangiectasias remain, 10% Bisclero is injected

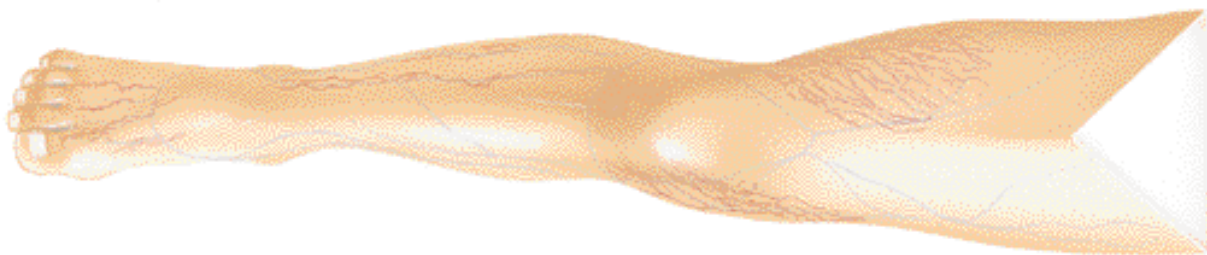

Fig. 20.2.4 The lower limb is divided into medial, lateral and posterior regions. In severe cases, each region is treated three times. The entire superficial and perforating circulation is regenerated. Unlike traditional obliterative sclerotherapy, three-dimensional regional sclerotherapy leaves valve function intact.

provide access to the underlying incontinent vessels. Thus, the telangiectasias are eliminated gradually as the entire superficial network is regenerated. Only when "regeneration" of the perforant network is complete, will 10% Bisclero be used to obliterate any remaining microtelangiectasias.

After several injections, the needle must be substituted.

In all patients, a small amount of lidocaine must be added to the solution (0.5 ml 2% lidocaine every 3 ml). The Bisclero solution can also be injected into the submalleolar vessel (**Fig. 20.2.5**).

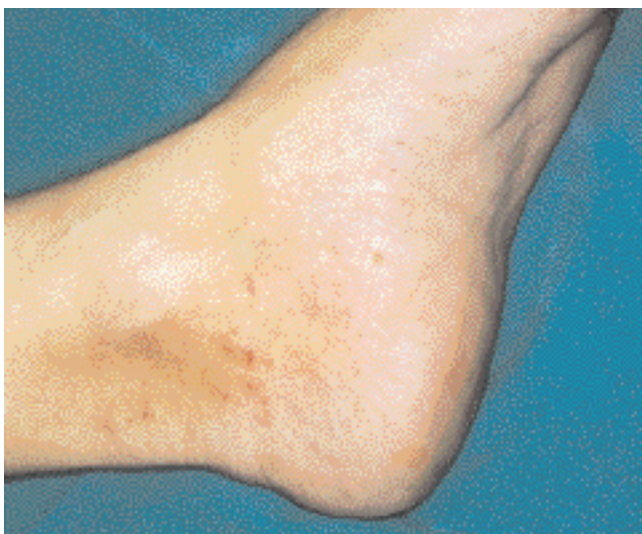
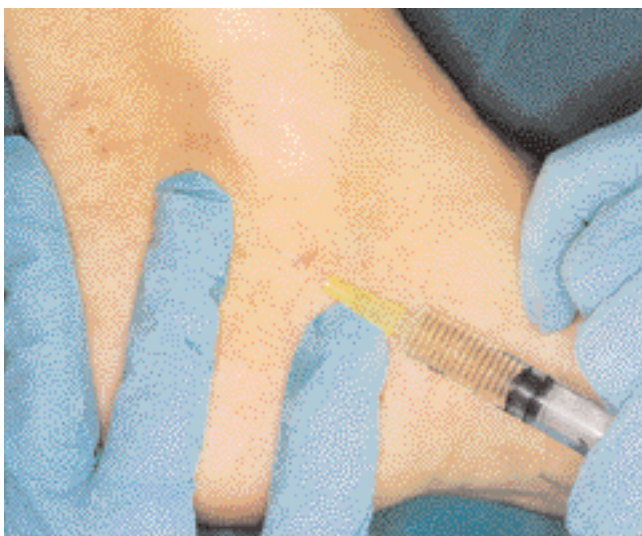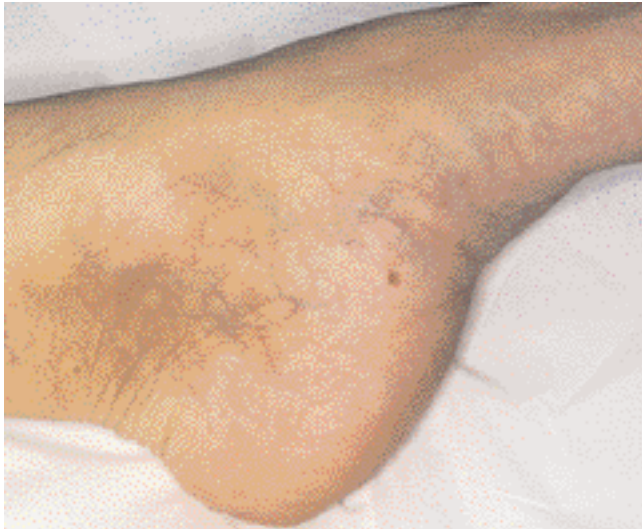Below the knee, the solution is pressed downwards; above the knee, it is pressed upwards.

Table 20.3 lists the guidelines for obtaining efficacious aesthetic and functional bisclerotherapy.

Medication

Small pieces of cotton-wool soaked in a non-alcoholic disinfectant (benzalkonium chloride) are applied to the injection sites; these are not fixed in place. When all ectatic vessels in the selected area have been treated, the cotton-wool is removed and an anti-inflammatory agent is applied. The patient remains motionless on the bed for a 5 minutes, then puts on differential-compression elastic stockings and resumes normal activity. The patient must not remain standing for long periods and should avoid sedentary activities. Daily massage of the treated area accelerates the disappearance of small ecchymoses.

Fig. 20.2.5 6% Bisclero is suitable for the sclerosis of submalleolar ectatic vessels.



20.3 Timedsurgical treatment

Programme data

Timed 9 hundredths of a second

- Coag microelectrodes - 7 or 10

Watts - EM 10 Yellow

Timedsurgical treatment is rarely used on the lower limbs, and only in very fine capillaries which are difficult to inject. (It should be remembered that, owing to its controlled viscosity, 10% Bisclero can be injected into microtelangiectasias with a diameter less than that of the needle itself by exerting slight pressure on the plunger of the syringe).

Timedsurgical microcoagulations should be carried out after the haemodynamic pressure has been reduced by means of a few sessions of three-dimensional regional bisclerotherapy.

When micro-coagulations are numerous, local or topical anaesthesia is required.

The operator should bear in mind that, if the visible telangiectasias maintain a high haemodynamic pressure, the three-dimensional concept may not be respected.





Fig. 20.3.1 The point of the electromaniple is carefully positioned on the telangiectasia. A rapid penetrating movement during timed emission allows the vessel to be punctured.

(see over)

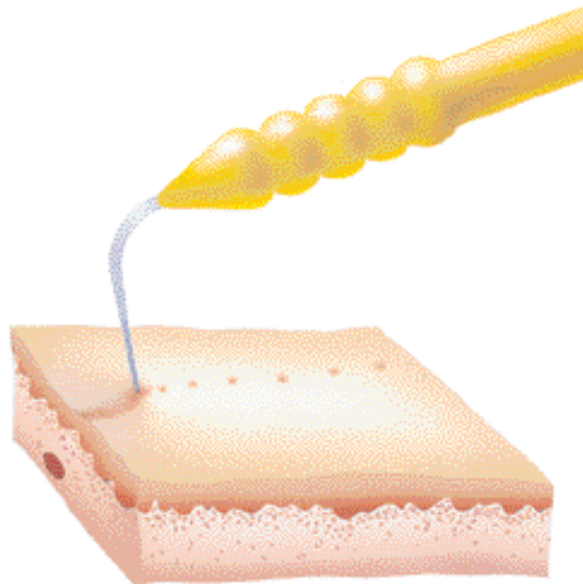

If the haemodynamic pressure remains high, the telangiectasias will reappear after a few months, or permanent matting will result. Contrary to common belief, matting that is amenable to treatment is maintained by high haemodynamic pressure, while purely inflammatory matting is that which is present below the post-sclerotherapy pigmentation and can be revealed by timed surgical de-epithelialisation of the area.

Technique

The patient return electrode is positioned homolaterally at the base of the thigh, and the area to be treated is disinfected.

The operator sets the Timed apparatus to the timed mode and adjusts the emission time to **7-9 hundredths of a second**, the function to **coagulation with microelectrodes** and the power to **7 or 10 Watts**.

The procedure is carried out with an **EM 10 Yellow** electromaniple. The ectatic capillaries are eliminated by means of a series of closely-spaced



The obliteration is completed by a series of micro-coagulations, spaced sufficiently closely to ensure disappearance of the entire telangiectasia.

microcoagulations executed with precision along the course of each vessel, normally at the level of the deep dermis (**Fig. 20.3.1**).

The micro-coagulations must be separated by only a few millimetres and must involve the whole diameter of the dilated vessel (**Fig. 20.3.2**). With the first timed emission, fine adjustments to the power and emission time are made.

These values are recorded for use at subsequent sittings for the same patient.

The operator concentrates exclusively on positioning the electromanipule and on penetration of the conical point into the epidermis above the telangiectasia, to obtain the required electrical contact. Then, by operating the pedal, the point is inserted rapidly, perpendicularly to the dermis to pass precisely through the ectatic capillaries; the electromanipule must not be forced, but must penetrate easily and without bending, by using the heat generated by the current; hand movements must therefore be synchronised with the emission. The electromanipule must not move laterally as this may produce a cut.

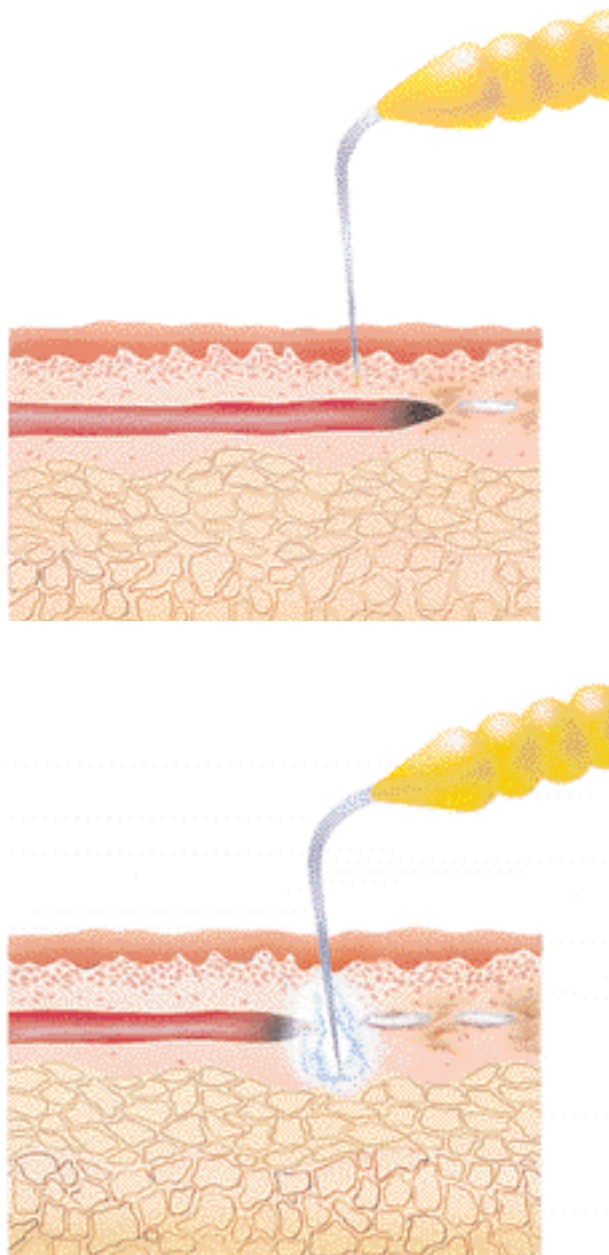


Fig. 20.3.2 The tip of the electromanipule must pass through the ectatic capillary. Only in this way is the micro-coagulation effective. The conical shape of the point allows a concentration of energy at the tip.

Bleeding may be caused if the energy density at the tip of the electromaniple is too high; in this case, power should be reduced to 7 Watts.

It is necessary to use a magnifying lens to pinpoint precisely and visually check the efficacy of the timed emission.

Where telangiectasias are more evident, a second discharge, with the electromaniple still positioned at the depth of the capillary, is required (see Fig. 15.2.4). As always, the electromaniple is not moved during the second emission and must not be subjected to further pressure; the skin is therefore not deformed but always perfectly horizontal.

An anomalous pressure may increase conductivity where the point has a large diameter, thus tending to favour superficial dispersion and hence failing to concentrate the emission where it is required (**Fig. 20.3.3**).

The second emission also serves to help the electromaniple penetrate more deeply if the operator is not sure that it has passed through the vessel on the first emission.

If the electromaniple tip does not

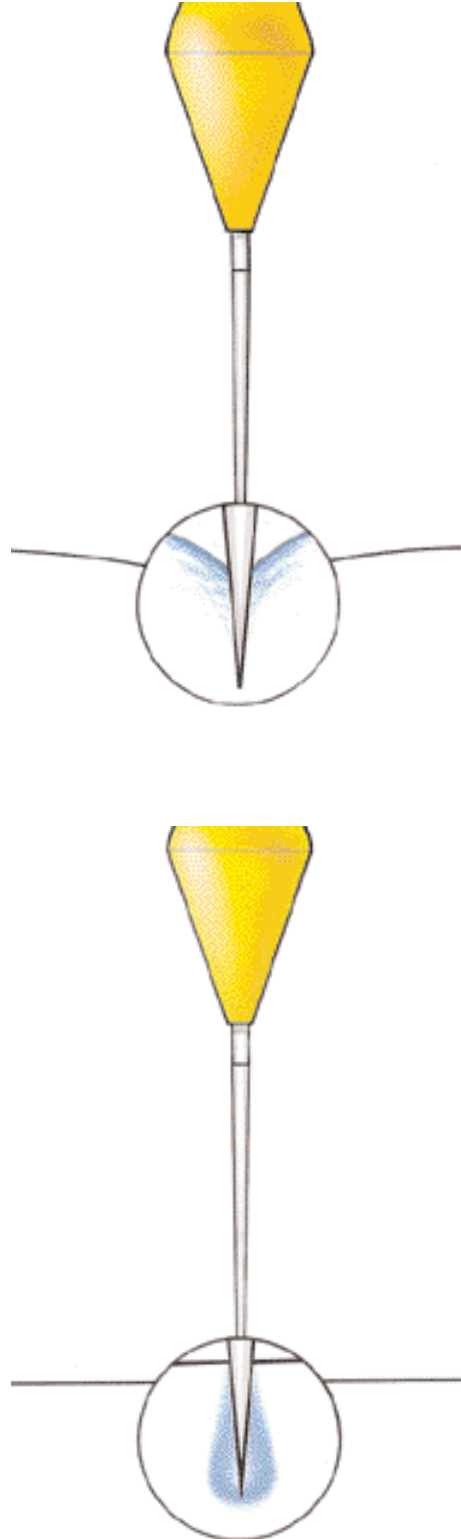


Fig. 20.3.3 With the second emission, it is possible to insert the electromaniple more deeply or add to the effect of the first emission. In this case it is necessary to eliminate pressure on the electromaniple, in order to avoid superficial conduction (top) and to obtain the characteristic tear-drop-shaped lesion (bottom).

cross the vessel, either because it is too superficial or because it is placed to one side, the emission only partially coagulates the capillary. If the endothelium remains intact, recanalisation and recurrence of the telangiectatic vessel may take place (**Fig. 20.3.4**).

In this case the operator must intervene a second time, inserting the electromaniple to a greater depth and more precisely.

The new micro-coagulations are effected in the spaces between the previous ones.

Patients with widespread telangiectasias or with dilated venules must be treated with sclerosing solutions, and only if resistant telangiectasias remain, a rare occurrence with bisclerotherapy, is treatment completed with timed surgery (**Fig. 20.3.5**).

At the end of the session, a fine

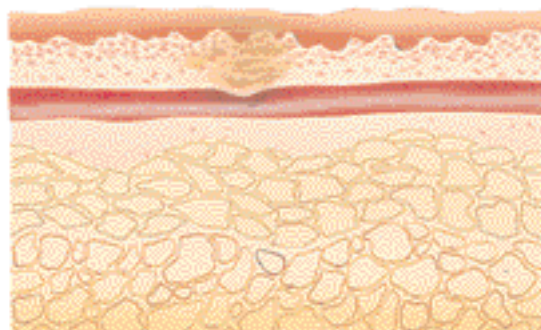
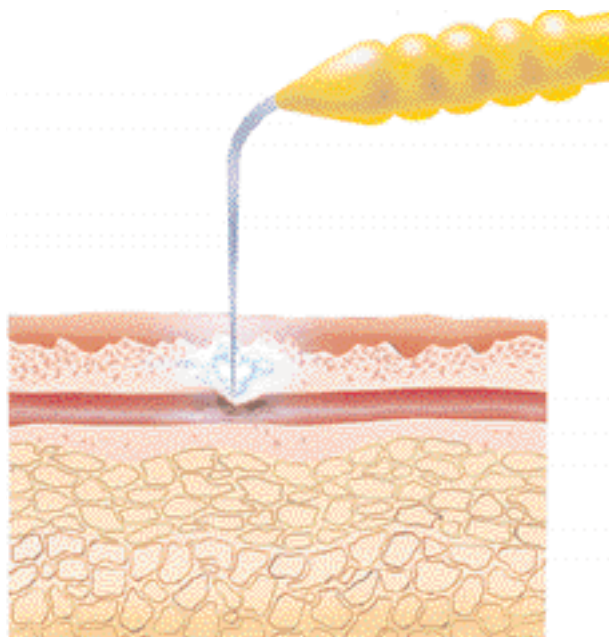


Fig. 20.3.4 When the action is too superficial or imprecise, the telangiectatic capillaries remain visible when the post-operative oedema resolves.

layer of antiseptic powder is sprinkled onto the treated area; this operation is repeated by the patient for a few days.

One week after the first treatment, the operator must check the results with a magnifying lens, by observing obliterated capillaries between the tiny coagulation points.

With telangiectasias which are still evident, further coagulations must be carried out at points interspersed between those of the previous coagulations. These new emissions are highly efficacious because, in the zone between crusts, the vessel is collapsed and the heat generated by the second emission fuses the walls, giving stable results (**Fig. 20.3.6**).

After 3 or 4 weeks the small crusts start to fall, leaving a pink colour, which fades in one or two months; during this period, the skin should not be exposed directly to the sun.

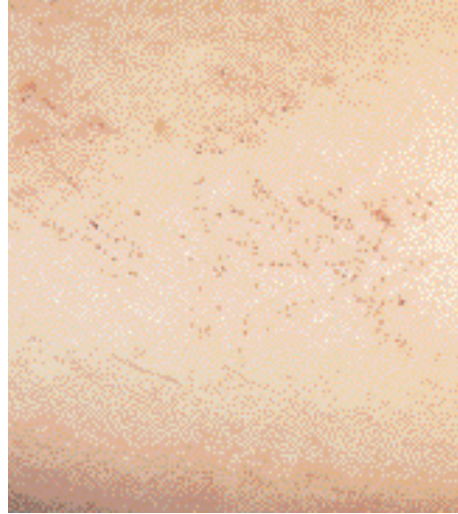


Fig. 20.3.5 Timed microcoagulations: one week later.

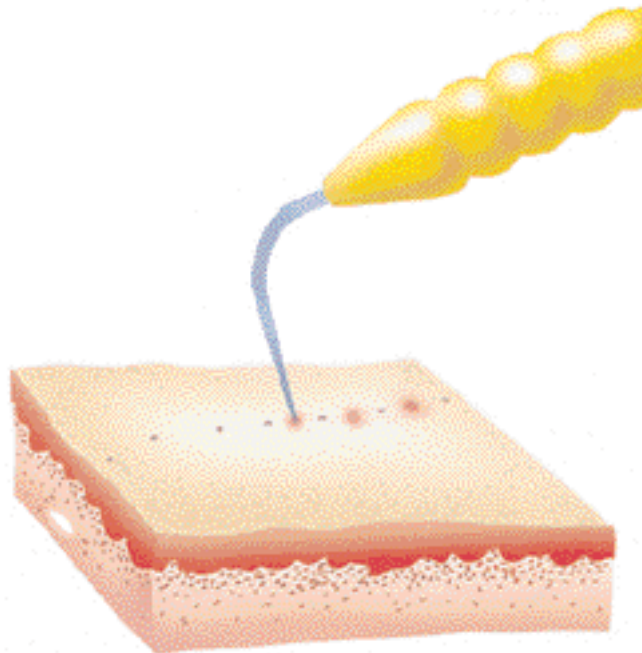


Fig. 20.3.6 Timed microcoagulations.

20.4 Endo-obliteration of veins

Some operators use intravenous coagulation to obliterate the saphenous vein, afferent veins of the saphena, cavernous angiomas, varices of lower limbs (O'Reilly 1981) and incompetent veins in regions in which venous ulcers are present (Kim 1983). For this purpose, special insulated catheters or needles are used to catheterise arteries or veins (**Fig. 20.4.1**).

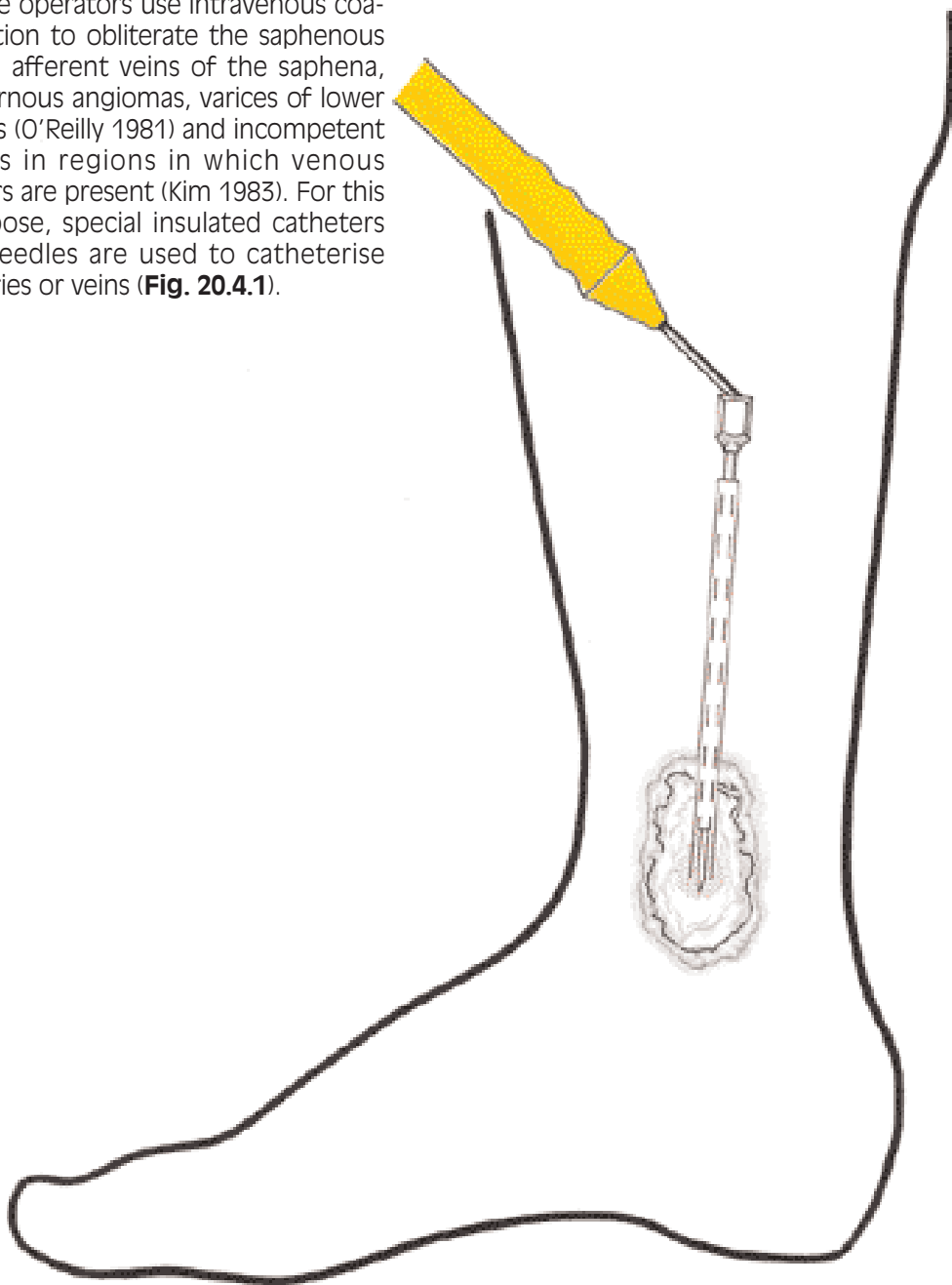


Fig. 20.4.1 Intravessel programmed coagulation.

21

RAPID DEFINITIVE EPILATION

The elimination of superfluous hair is undertaken for aesthetic and psychological reasons. It is performed both in patients with hirsutism (**Fig. 21.0.1**) and in those with normal amounts of body hair who wish to eliminate hair from certain areas of the body (armpits, legs, abdomen etc.). In patients with generalised hirsutism, endocrine and gynaecological examination is required, in order to exclude underlying causes which may require medical or surgical treatment.

Hair may be eliminated by true electrolysis, a technique which has been almost completely abandoned, or by electrosurgery.

While some techniques combine the two methods, the drawbacks of the former are still present. Electrolysis uses a small continuous current that is carried to the follicle by means of a needle electrode connected to a negative pole. Here, through a chemical process, hydrogen ions are released and sodium hydroxide is formed, which causes necrosis of the follicle. This technique is slow, painful and does not produce aesthetic results.

Electrosurgery is a more efficacious method because the high-frequency current immediately generates heat in the tissues, producing a localised lesion.

This is extremely rapid and relatively painless. However a risk of scarring is still present. In traditional electrosur-

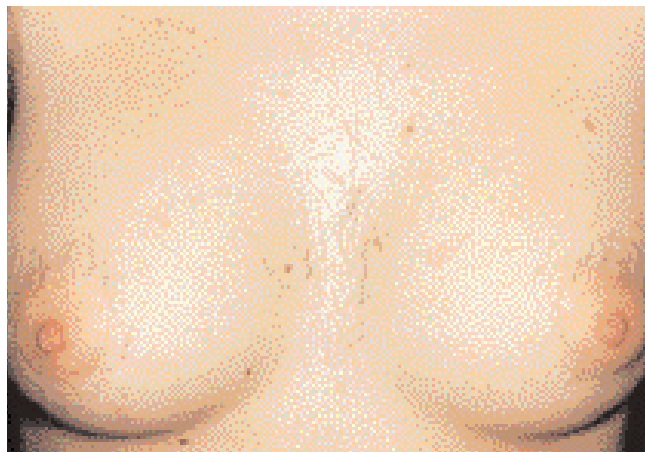

Fig. 21.0.1 Hirsutism

gery units, emission times are regulated directly by the operator, using a pedal, and are therefore imprecise. In a normal sitting, between 50 and 100 hairs are treated and there is always a percentage of discharges which are too short or too long. Consequently, to limit scarring, one is obliged to use a low power, which may not yield permanent results. Traditional electrosurgery units do not have precise power regulation, nor are they able to provide energy emissions which are constant and repeatable. These features are not essential if the duration of the emissions cannot be controlled precisely.

In the past, surgical epilation was attempted by raising the skin to be epilated and using scissors to cut away the hairbulbs situated in the sub-cutaneous tissue (Freerk 1978).

A special instrument has been described which is used to carry out this type of intervention in the armpit region (Inaba 1976).

Results are variable, not because of residual scarring, which is now preventable, but because of regrowth from persistently by germinating hair cells. The generative zone of the hair is not in fact limited to the hairbulb, as was once thought, and incomplete elimination of germinative cells inevitably leads to regeneration of hair. The difficulty of achieving permanent results, owing to the anatomical-functional resistance of the pilus-follicle complex, justifies scepticism with regard to costly, non-selective procedures such as laser epilation.

In order to avoid scarring (**Fig. 21.0.2**) and to achieve definitive high-quality epilation, it is advisable to use the timed surgical method.

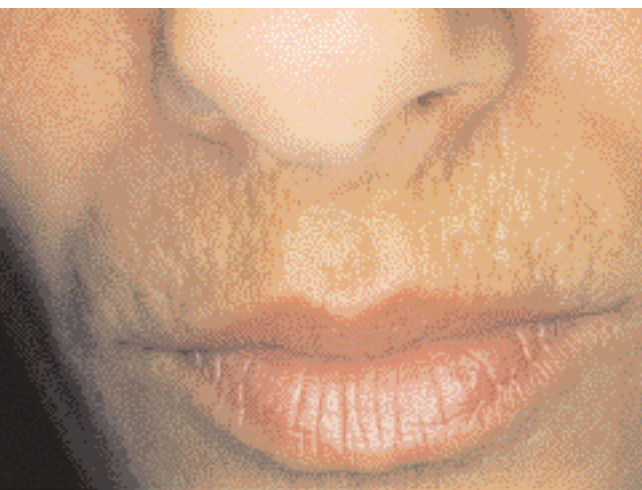

Fig. 21.0.2 Traditional electrocoagulation frequently produces unsightly pitted scars, which can be corrected by mixed peeling.

21.1 Anatomy and Physiology of Hair Growth

To understand how permanent epilation may be achieved, it is necessary to have some knowledge of the anatomy and physiology of normal hair.

Hair grows from follicles, which are small invaginations of the surface epithelium. At the base of each follicle is the dermal papilla. The hair shaft is produced by the division of the cells surrounding the papilla, the hair bulb.

The follicles are usually at an angle to the skin surface and are pulled towards the upright position by the action of a small erector pili muscle which runs from the mid-point of the follicle to the dermo-epidermal junction. Above the insertion of the muscle there is a sebaceous gland and, in some areas, an apocrine gland opens into the follicle.

Hair growth occurs in cycles involving a growing phase and then a resting phase, followed by loss of the old hair and growth of a new hair.

The hair shaft consists of three components; a thin core or medulla, a thick cortex which forms the bulk of the hair, and a thin surrounding cuticle. The inner root sheath consists of cuticle and two layers of cells - Henle's and Huxley's layers.

This is surrounded by the outer root sheath, which is continuous with the superficial epithelium.

The inner root sheath is a rigid structure that is able to guide the hair shaft during keratinisation.

The hair shaft, deprived of its inner root sheath, emerges from the follicle and constitutes the visible part of the hair. It is important to

remember that the inner root sheath adheres closely to the external root sheath, there being no space between the two, up to the opening of the ducts of the sebaceous glands. At this level the internal root sheath disappears.

The follicle may be conveniently divided into two parts, a superficial portion, the lower limits of which are the openings of the sebaceous glands, where there is a space between the walls of the follicle and the hair, and a deeper portion,

situated below the openings of the sebaceous glands, where the follicle is closely adherent to the hair shaft. Permanent epilation is achieved by destroying the hair bulb and the deep portion of the follicle, beneath the openings of the sebaceous glands.

Eliminating only the bulb is inadequate, as adjacent cells of the deep portion of the follicle assume a regenerative capacity and give rise to new hair, complete with a new papilla (Montagna 1967) (**Fig. 21.1.1**).

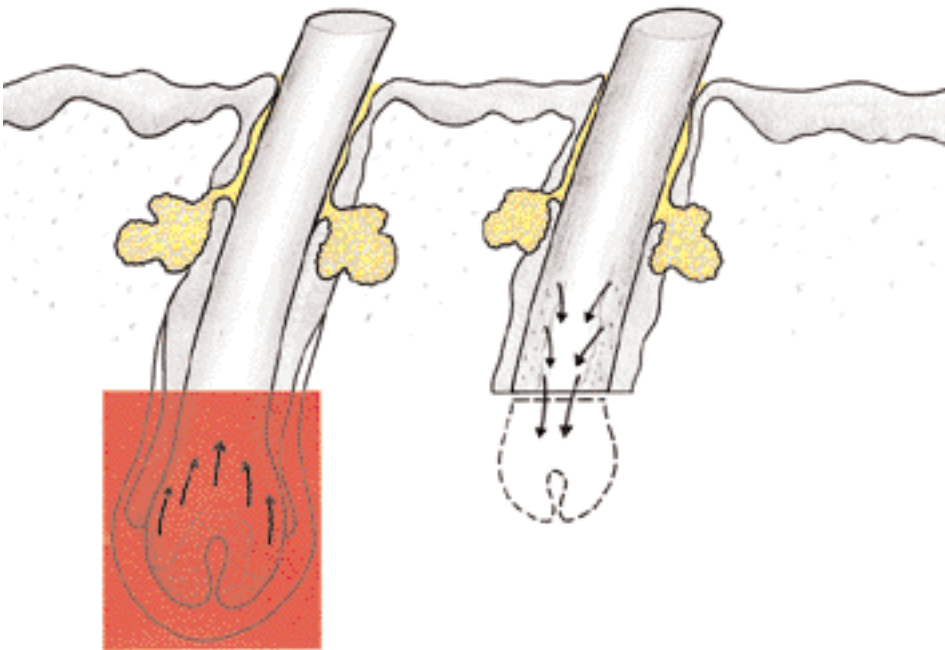


Fig. 21.1.1 The germinative cells of the hair are situated in the hair bulb; if the bulb is removed, cells of the deeper part of the hair follicle, beneath the openings of the sebaceous glands, assume a regenerative capacity. To obtain permanent epilation it is necessary to eliminate these cells too.

The hair is surrounded by a dense vascular plexus (**Fig. 21.1.2**) and a rich network of myelinated and non-myelinated nerve fibres (**Fig. 21.1.3**).

It is therefore impossible to produce painless epilation except by using anaesthetic solutions or cream.

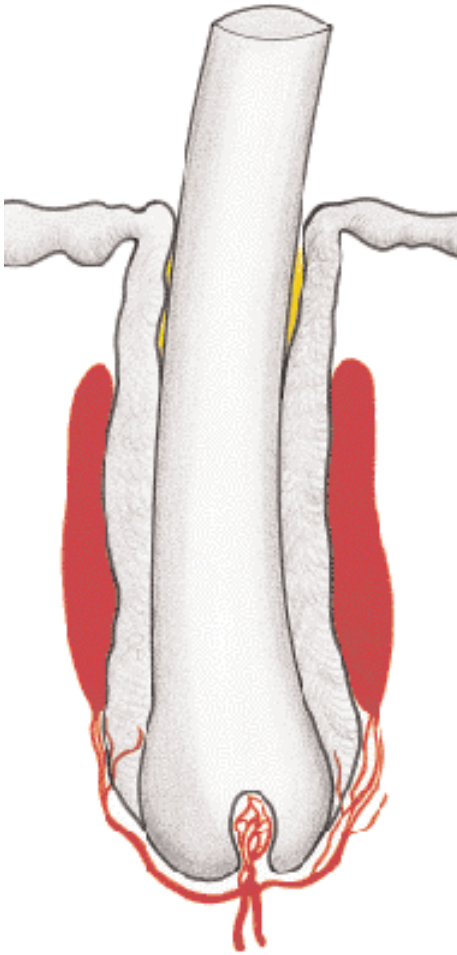


Fig. 21.1.2 A venous plexus around the hair follicle. Any bleeding indicates incorrect insertion of the electromaniple

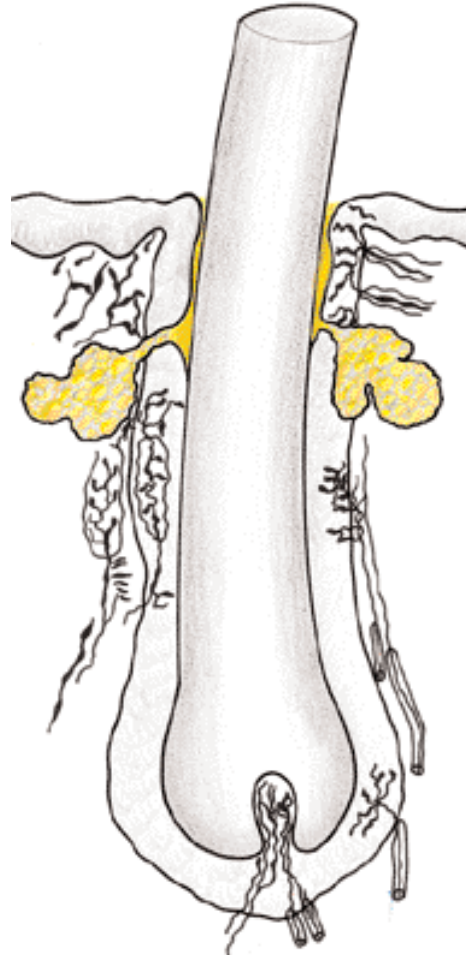


Fig. 21.1.3 The hair is rich in myelinated and non-myelinated nerve fibres.

21.2 Timed epilation

Programme data

Timed 25 hundredths of a second - Coag microelectrodes - from 2 to 5 Watts - EM 10 Green.

Timed coagulation produces rapid and definitive epilation, without the risk of scarring, and allows the operator to concentrate solely on inserting the electromanipule into the hair follicle (Capurro 1986).

By using controlled power and timing, and a conical point, it is possible to achieve definitive results superior to those obtainable with conventional epilation apparatuses. In the conventional apparatuses, the duration of the electrical discharge is determined by the operator, the power cannot be regulated precisely and is not indicated in Watts (see section 9.3), and the use of lower frequencies may cause the patient greater discomfort.

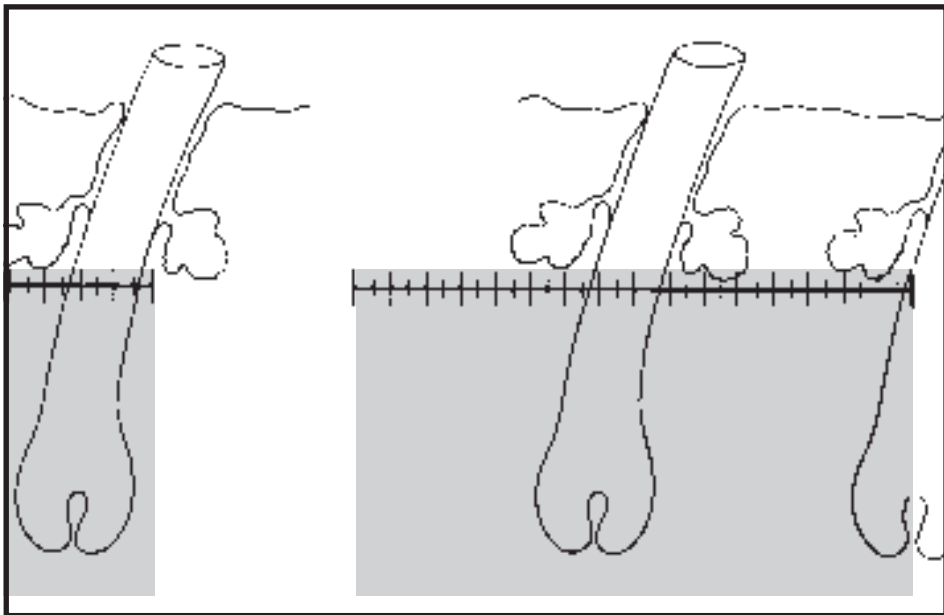


Fig. 21.2.1 The emission time determines the extent of the lesion. The illustration on the left shows thermal action caused by **3 Watts** with an emission time of **25 hundredths of a second**. On the right, the same power with emission time of **1 second**. In this latter case, coagulation extends beyond the single hair follicle being treated and produces scars when contiguous hair follicles are treated.

21.3 Technique

After placing the patient's return electrode in contact with the skin and disinfecting the area around the treatment site (with a non-flammable disinfectant), the operator sets the apparatus to the **timed** mode and the emission time to between **18 and 30 hundredths of a second** depending on the thickness of the hair.

The average timing is **25 hundredths of a second**.

The function is set to **coagulation with microelectrodes** and the power from **2 Watts** for fine hair, to **3, 4 or 5 Watts** for facial and body hair (Tab. 21.1).

The shorter emission times are needed for fine hair, on the lip for

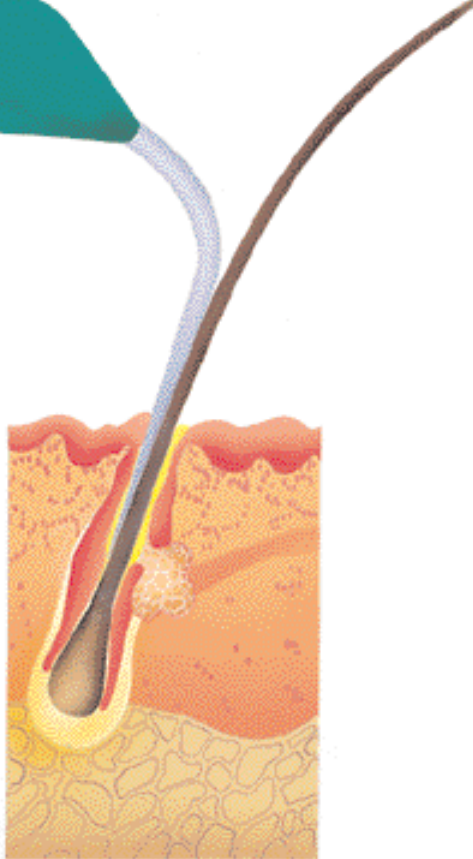


Fig. 21.3.1 Above the opening of the sebaceous glands the hair is separate from the wall of the follicle. Below this, it is closely adherent to it. The conical point must be inserted into the follicle parallel to the hair as it leaves the follicle.

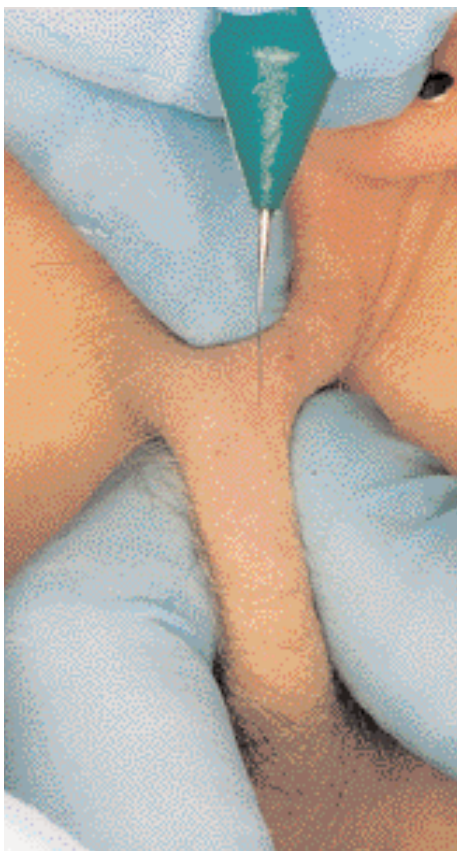
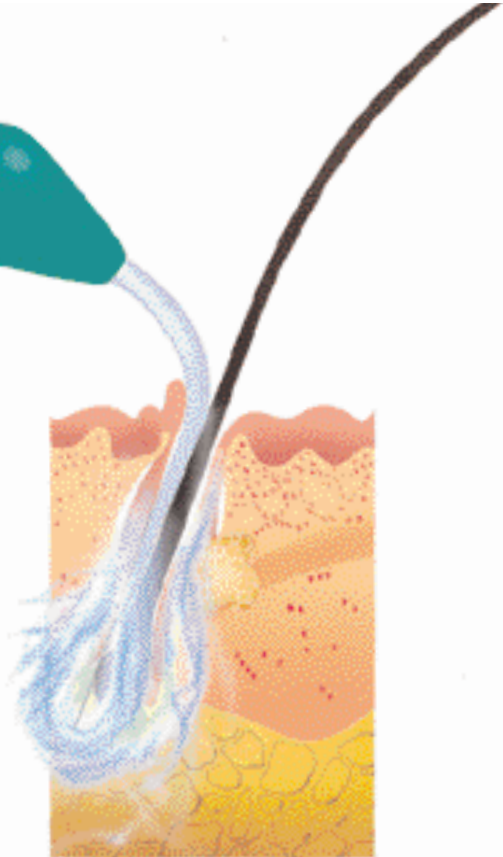

Fig. 21.3.2 Pinching the skin facilitates insertion of the **EM 10** electromaniple.

Fig. 21.3.3 When the electromaniple meets with slight resistance, it is in the second portion of the hair follicle below the opening of the sebaceous glands. The operator generates a timed emission and simultaneously inserts the point into the deeper part of the hair follicle.



example, and the longer times for coarse body hair. Emission times above **30 hundredths** of a second must never be used.

If a satisfactory result is not obtained, the power should be increased.

An **EM 10 White** electromaniple is used for fine hair, an **EM 10 Green** electromaniple for facial hair and an **EM 10 Grey** electromaniple for body hair.

Epilation is achieved by inserting the electromaniple point into the follicle. Resistance is not due to contact with the hair bulb, as some erroneously believe, but to contact with the part of the follicle situated below the opening of the sebaceous glands (**Fig. 21.3.1**). Insertion of the electromaniple into the more superficial part of the follicle is assisted by stretching and pinching the skin (**Fig. 21.3.2**). Electromaniple

insertion should be atraumatic, painless and must not cause bleeding.

The direction of the point should follow the direction of the hair as it exits the follicle.

The conical shape of the point concentrates high frequency current at the tip (see section 7.4.1). When inserted into the follicle, the triangular-sectioned tip easily penetrates to the deeper part of the hair follicle despite the lack of space around the stem of the hair.

After reaching the resistance zone, the operator presses the pedal and simultaneously lowers the electromaniple from one to three millimetres, down to the bulb, thereby coagulating the second portion of the follicle. In this way, all of the germinative cells of the hair are destroyed. The downward movement of the point is facilitated during the emission (**Fig.**

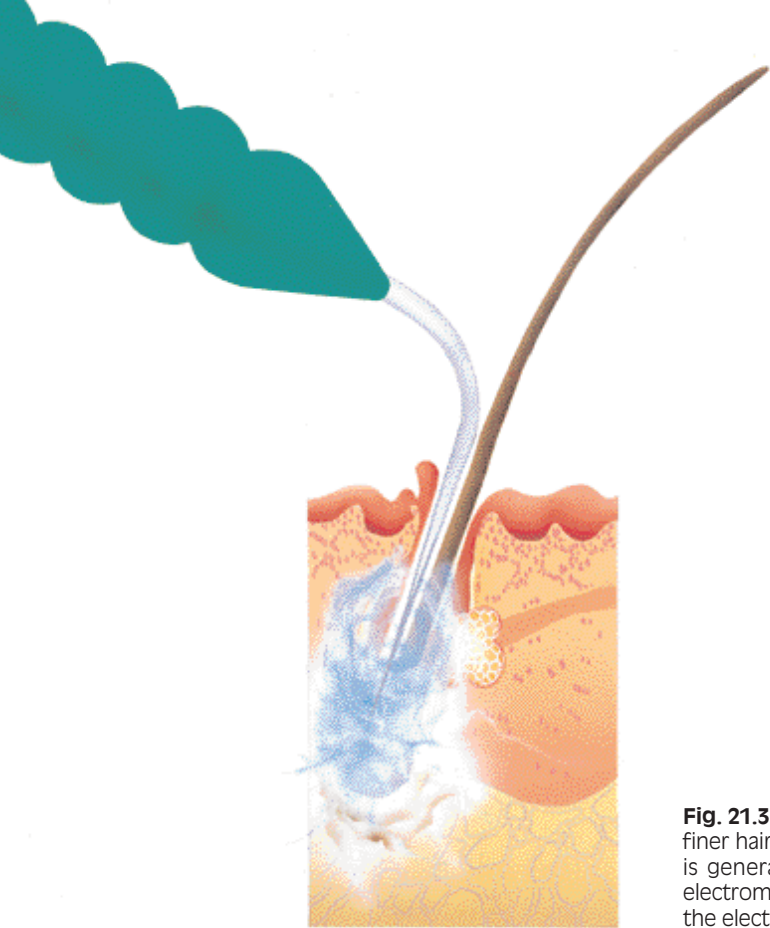


Fig. 21.3.4 A single emission is sufficient for finer hair; for terminal hair a second emission is generated after slightly withdrawing the electromaniple. During the second emission the electromaniple is kept still.

21.3.3). Epidermal lesions, which occur if the emission is too superficial, are thus avoided.

A single emission is sufficient to eliminate fine hairs, but for terminal hairs a second emission is required; this is generated after the electromaniple is pulled back to the superficial portion of the deeper follicle. During the second emission, which completes the destruction of the germinative cells, the operator holds the electromaniple still (**Fig. 21.3.4**).

The downward movement is also particularly useful as it allows hairs which leave the follicle in the telogen phase to be treated effectively (**Fig. 21.3.5**).

It should be noted that the resistance zone described above is felt only if the electromaniple is inserted slowly.

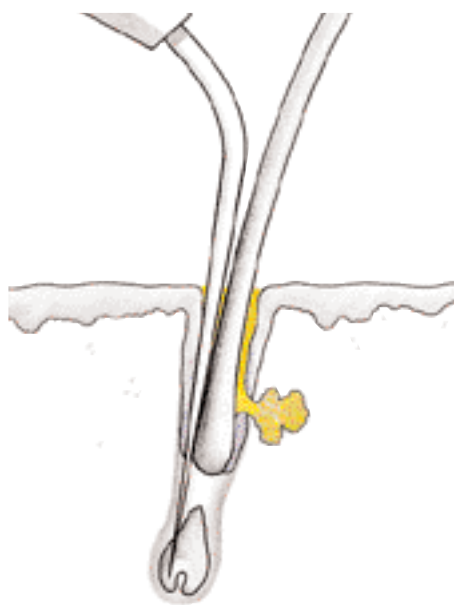


Fig. 21.3.5 The first emission, executed with a moving point, is effective even on hairs in the telogen phase

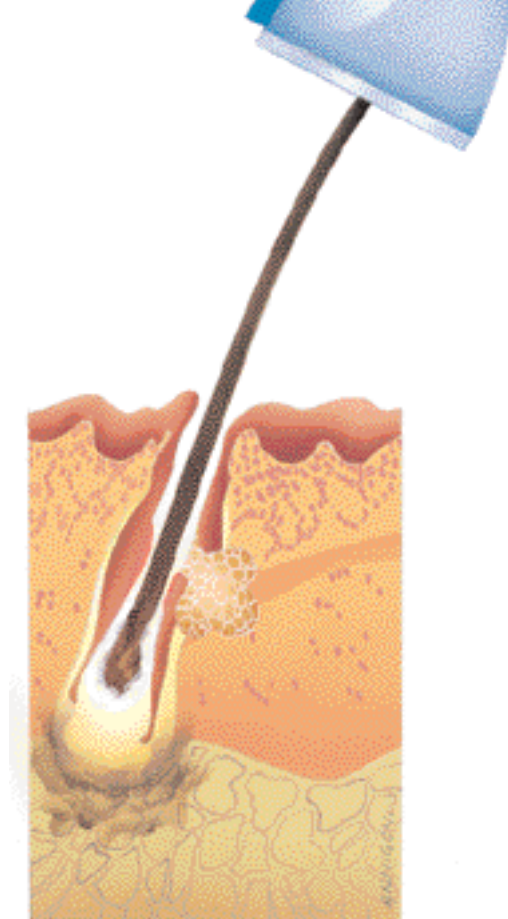


Fig. 21.3.6 The treated hair must be extracted without any resistance. If resistance is encountered, the follicle must be treated again more precisely.



Fig. 21.3.7 Epilation forceps should not be too stiff, to avoid operator fatigue.

When the conical point of the electromaniple comes into contact with the deeper portion of the hair follicle, a slight dimpling of the skin surface is noted.

In clinical practice the insertion of the electromaniple and simultaneous emission are sufficiently rapid to render the phenomenon of resistance imperceptible. The treated hair should offer no resistance to extraction (**Fig. 21.3.6**) It is removed with the fingers or epilation forceps (**Fig. 21.3.7**).

If there is resistance, the electromaniple must be re-inserted and the emission repeated with greater precision, as the germinative zone has not been destroyed.

The hair must always be extracted to avoid infection or foreign body reactions.

Programming in one-hundredths of

a second, and with relatively high and perfectly stable power, produces a very limited lesion and safe destruction of the germinative cells of the hair, without scarring, even if the emission is repeated and the hairs treated are very close together. With timed surgery, pain is minimal, owing to the very brief emission time and high frequency discharge, which is filtered to remove low frequencies. This eliminates muscle stimulation and the sensation of electric shock, which is perceived with lower frequency units in unanaesthetised patients.

Timed coagulation allows the commonly requested process of epilation to be rapidly learnt. The operator can concentrate exclusively on precisely positioning the electromaniple. Indeed, once an effective programme has been determined and terminal hairs have been eliminated, failure in the same area with a treated hair of the same dimensions, is usually due to incorrect positioning of the electromaniple. In epilation with timed surgery, there is no need to use an electromaniple with a partially insulated point.

Tab. 21.1 Programme data for timed epilation

Region	Function	Watts	1/100 s	Elettromaniple
Upper lip	Coag. micro elect.	2-3	20	EM 10 White
Cheek, chin	Coag. micro elect.	3-4-5	25	EM 10 Green
Trunc	Coag. micro elect.	3-4-5	25	EM 10 Green or Grey
Limbs	Coag. micro elect.	3-4-5	25	EM 10 Green or Grey

21.4 Pulsed epilation

Programme data

Direct pulsed 25/68 hundredths of a second - Coag microelectrodes - from 2 to 5 Watts - EM 10 Green.

Once the technique of epilation has been mastered, the operator can perform epilation by pulsed emission.

In this automatic mode of the Timed micropulse apparatus, the emission time is **25 hundredths of a second** and the inter-pulse is **43 hundredths of a second**.

When the pedal is pressed, the apparatus generates a series of emissions.

The series is interrupted by lifting the foot off the pedal.

Epilation by pulsed emission is more rapid than by single timed emission. The epilation technique is the same as that previously described, except that the operator does not lift his foot off the pedal.

Two emissions are normally carried out, though this number may be increased if the hairs are of a large size. Like the other pulsed functions, this function must be used in the direct mode.

21.5 Epilation of the face

Epilation of the face with timed coagulation is carried out in weekly or fortnightly sittings.

Each sitting lasts approximately 20 minutes, during which around 60 hairs are eliminated.

If necessary, all hairs may be eliminated in a single sitting, even if they are numerous.

With traditional electrosurgery, on the

other hand, this is not possible, as the unselective coagulation of adjacent follicles may lead to skin damage and scarring (see fig. 21.2.1). Epilation may be carried out on the cheeks, upper lip, chin, neck and ears.

The hair line can be modified.

The edge of the eyelid may be epilated in the case of ingrowing hairs abrading the cornea, and midline hairs of the eyebrows can be eliminated; in men this is the most frequent epilation, together with epilation of the zygomatic area, the cheek and the neck.

On the upper lip, where hair follicles are extremely short, particular attention must be paid to avoid superficial emissions, which may injure the epidermis.

As short an emission time as possible and the **EM 10 White** electromaniple must be used. Epilation is carried out under topical or regional (**Fig. 21.5.1-2**) anaesthesia. Regional anaesthesia is preferable as it does not alter the conductivity of the surface of the skin.



Fig. 21.5.1 An anaesthetic cream (Emla) is applied 1 hour before epilation.

Fig. 21.5.2 1.5 ml of anaesthetic solution (2% mepivacaine) injected into the gingival fornix above the canine tooth anaesthetises the infraorbital nerve. This enables the corresponding half of the lip to be epilated completely and painlessly.

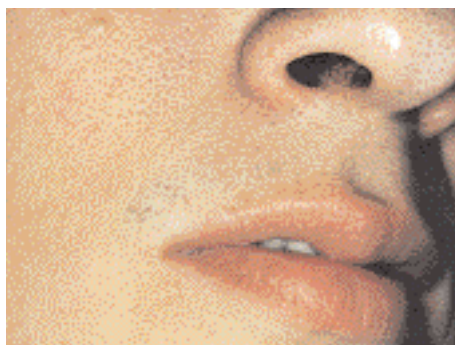
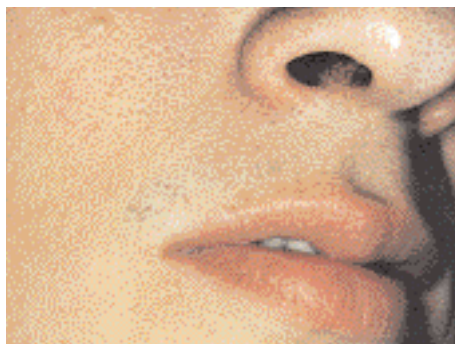
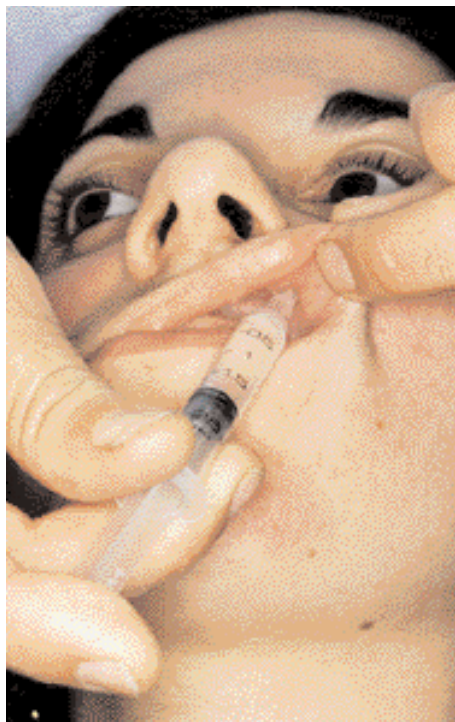Fig. 21.5.3 During epilation, slight reddening occurs. Programme data: **coagulation with microelectrodes, 2 Watts, 20 hundredths of a second, EM 10 White** electromaniple.

All of the hairs may be eliminated in one session (**Fig. 21.5.3**).

Epilation of eyelid, eyebrow, ear and columellar hairs (**Fig. 21.5.4**) is often performed under local anaesthesia.

Epilation should be avoided on infected skin, as this may exacerbate and spread the infection.

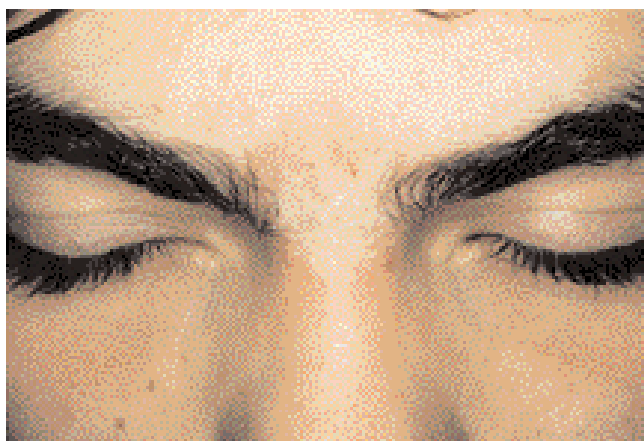

Fig. 21.5.4 A small quantity of local anaesthetic with adrenaline allows painless epilation of the glabellar region. Timedsurgery allows the removal of all of the hairs present. Below, the results three months after treatment. Programme data: **coagulation with microelectrodes, 3 Watts, 25 hundredths of a second, EM 10 Green** electromaniple.



In epilation of the face, an average power of **2 Watts** for the upper lip and **3** or **4 Watts** for hair on the cheek and chin is used (**Fig. 21.5.5-6**).

In a few patients, epilation is faster with a power of **5 Watts**.

This is related to the dimension of the hair, which often becomes reinforced after years of removal with tweezers.

In the first treatment sessions, the operator sets the time to intermediate values (**25 hundredths of a second**).

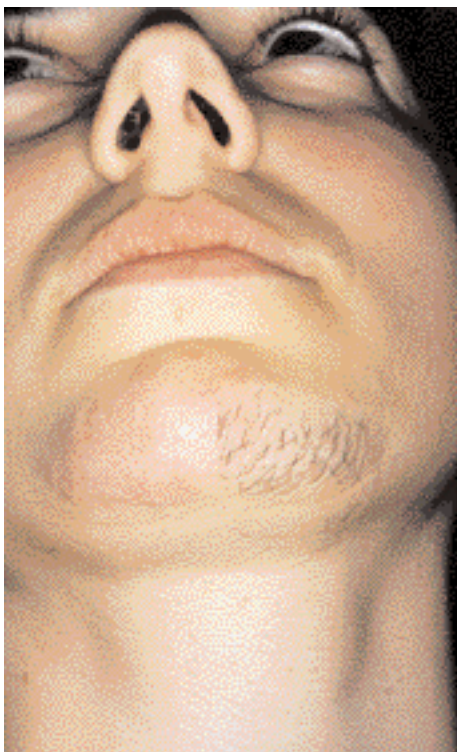

Fig. 21.5.5 Epilation of the chin. Anaesthetic is not required. In one session all hairs are eliminated. The telogen-phase follicles are treated in later sittings. Programme data: **coagulation with microelectrodes, 4 Watts, 25 hundredths of a second, EM 10 Green** electromaniple.

If these are insufficient to obtain the desired results, emission time is increased by a few hundredths of a second at a time.

If the germinative zone is still not

completely coagulated, power is increased, for example from **3** to **4 Watts**, but in this case, emission time must be reduced to the medium value .

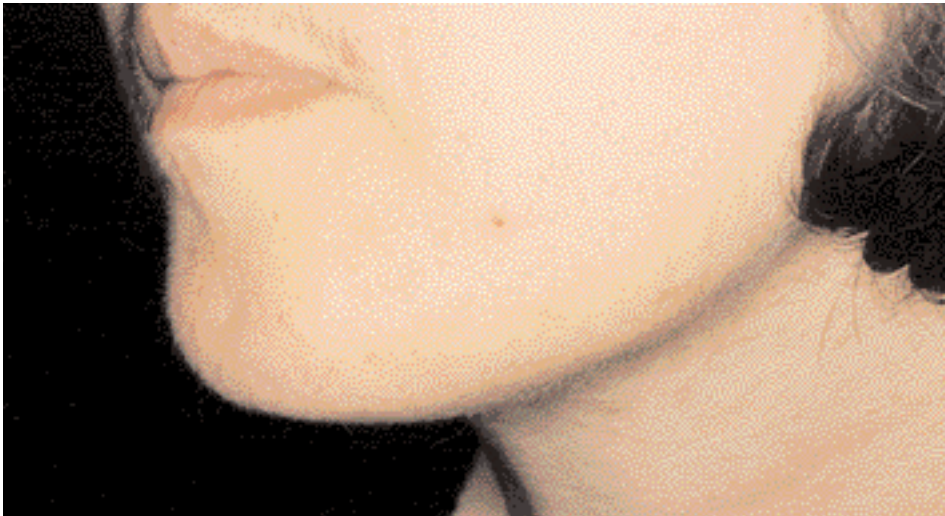
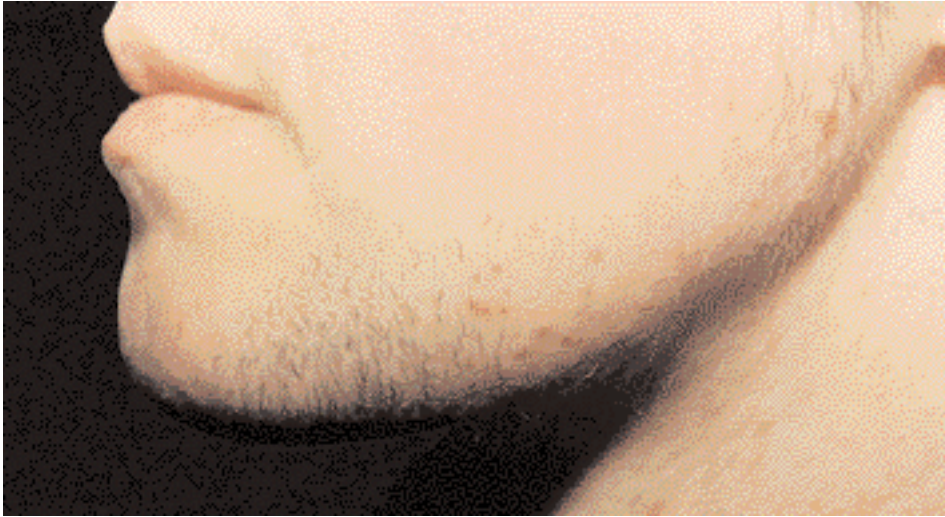
Fig. 21.5.6 Hypertrichosis (top). No regrowth three years later (bottom). No visible signs remain. The number of sittings is proportional to the hairs per cm² in the area. Programme data: **coagulation with microelectrodes, 4 Watts, 25 hundredths of a second, EM 10 Green** electromaniple.

21.6 Epilation of the Body

Epilation of various regions of the body can be carried out: the axilla (**Fig. 21.6.1**), the periareolar region and the breasts (**Fig. 21.6.2**), the back, the abdomen (**Fig. 21.6.3**), the groin (**Fig. 21.6.4-5**) and the lower limbs.

Where the hair to be eliminated is quite densely concentrated, for example in the axilla, epilation is carried out under local anaesthesia by eliminating all of the hair in a single sitting. In the groin region the operator outlines the zone to be epilated, using the patient's bathing costume as a template.

Epilation must be repeated two or three times, with two or three months between each sitting, to remove hairs in the telogen phase not present and therefore not treated during the first and second sittings.

For the convenience of the operator it is possible to divide the region into two zones, which will be epilated in two sittings. Each zone is anaesthetised with local anaesthetic. In total epilation of other regions of the body, local or topical anaesthesia is optional and only used at the patient's request. The efficacy of the technique can be checked easily in these body regions; unlike the face, on which no visible signs are left, with treatment of follicles on the

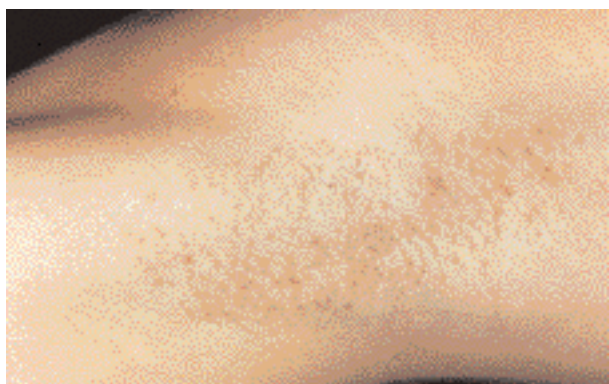
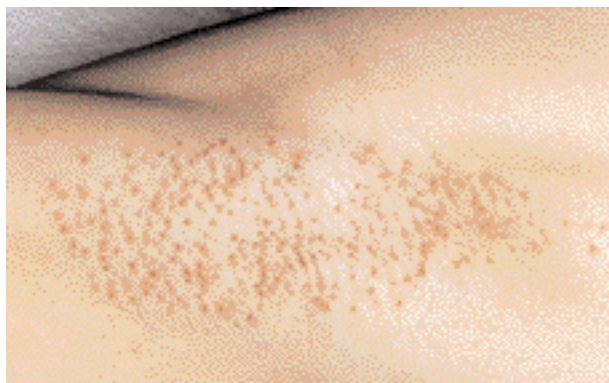
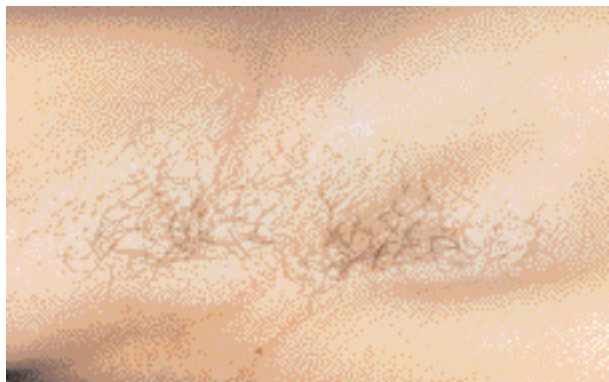Fig. 21.6.1 Epilation of the axilla: results after one week and two weeks. Programme data: coagulation with microelectrodes, 4 Watts, 25 hundredths of a second, EM 10 Grey electromaniple. Local anaesthesia.

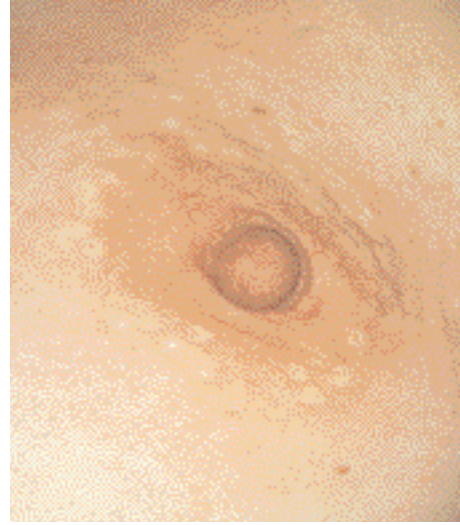
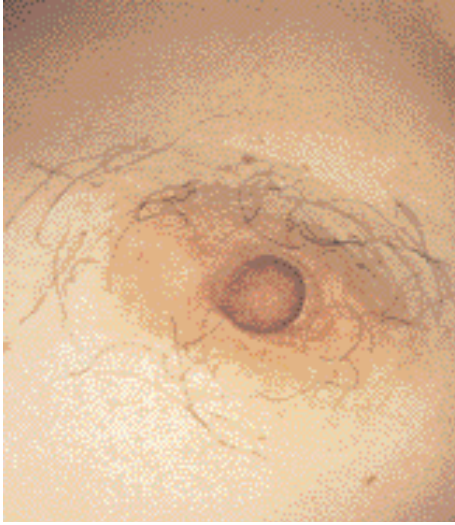


Fig. 21.6.2 Epilation of the areola carried out without anaesthesia. On the right, results immediately after the sitting. Programme data: **coagulation with microelectrodes, 5 Watts, 25 hundredths of a second, EM 10 Grey** electromaniple.

body, a light spot forms, which remains evident on account of loss of pigmentation caused by thermal shock.

This allows the treated follicles to be distinguished by examination with a magnifying lens. In this way the extent of hair growth from uncoagulated follicles can be checked.

In particularly conductive skin, tiny crusts form. These detach after two or three weeks.

On the face, this rarely occurs and lasts only a few days. On the body, there will be no visible signs after a few months and any de-pigmentation will have resolved.

The power used in epilation of the body is **3 or 4 Watts**.

In a few patients, epilation is easier with **5 Watts**; emission times in the preceding session remain valid.

Partially insulated electromaniples are not used.

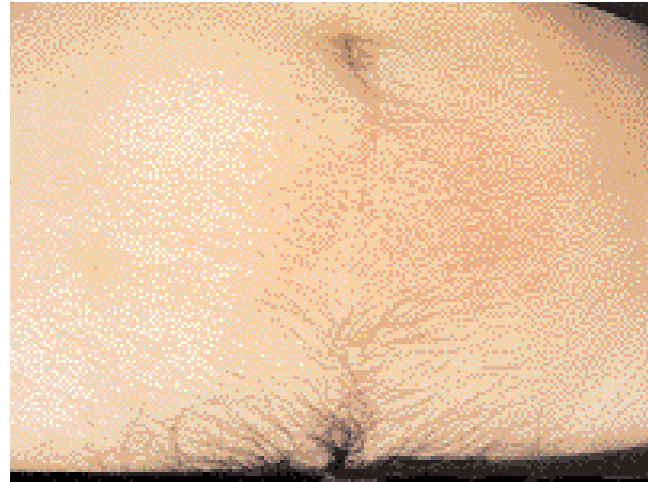


Fig. 21.6.3 Epilation of the lineae alba. The operator eliminates all of the hair between the naval and the upper margin of pubic hair. Local anaesthesia is optional in this region. Programme data: **coagulation with microelectrodes, 4 Watts, 25 hundredths of a second, EM Grey** electromaniple.

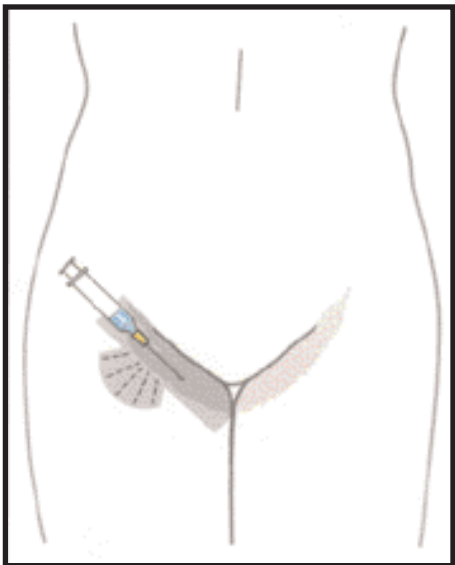


Fig. 21.6.4 To perform epilation in the groin area, the operator injects an anaesthetic solution without epinefrine (6 ml of 2% lido-caine).

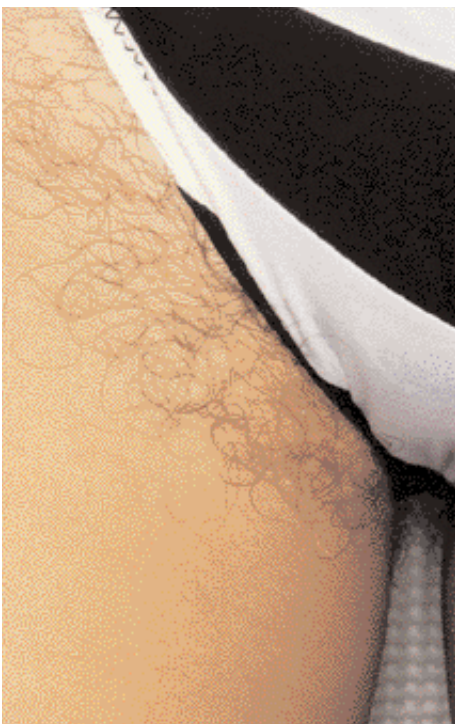

Fig. 21.6.5 Epilation of the groin. On the right, results after the second of three sittings. Programme data: **coagulation with microelectrodes, 4 Watts, 25 hundredths of a second, EM Grey** electromaniple. Local anaesthesia.

Tab. 21.2 Complications of timed and pulsed Epilation

Problem	Cause	Solution
Bleeding on insertion of electromaniple	Imprecise insertion of electromaniple	Insert electromaniple into superficial portion of follicle
Pigmentation	Immediate exposure to UV rays	Apply de-pigmenting and sunblock cream
Immediate whitening of skin surface	Coagulation too superficial; dirty electromaniple	Carry out first emission with electromaniple penetrating more deeply; clean electromaniple
Small scars	Electromaniple too large cf. skin texture; power too high and/or emission time too long; dirty electromaniple	Use finer electromaniple; reduce power and emission time; clean electromaniple; timed surgical resurfacing; mixed peeling

21.7 **Post-operative treatment**

After epilation, the treated zone is disinfected with an alcoholic solution and a corticosteroid lotion is applied. Patients should avoid exposure to the sun and should use a sunblock after treatment. Table 21.2 lists possible complications of epilation.

21.8 **Hair Growth**

Hair correctly treated with timed-surgery cannot regrow. It is useful for the operator to discuss with the patient the different stages of hair growth and the necessity for retreatment of the same area even if all hairs present have been removed (**Fig. 21.8.1**). In order to prevent new growth, all follicles which give rise to terminal hairs must be treated, including those in the telogen phase, which are often not visible. Therefore, to produce a satisfactory result in the groin, for example, three or four total epilations of visible

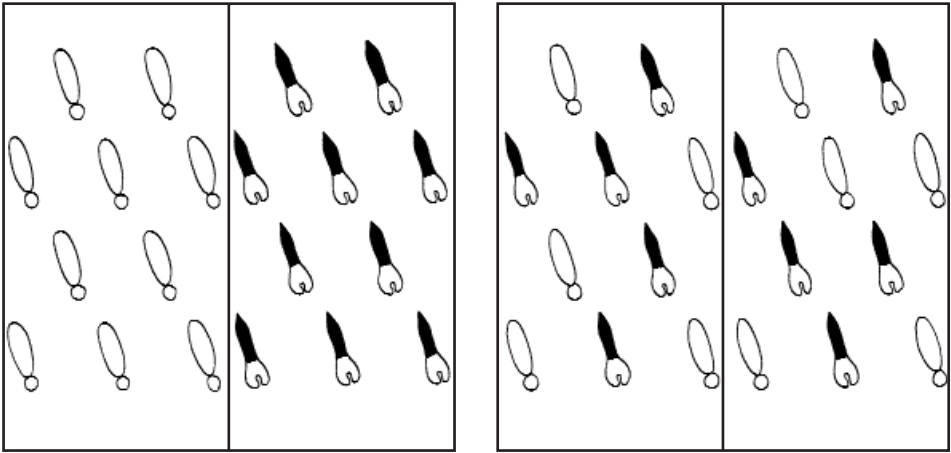


Fig. 21.8.1 In many animals, hair growth is synchronised, with all hair shedding simultaneously (left). In man, on the other hand, the individual hair follicles are all at different growth or resting stages (right).

hair are required, with sittings three months apart. For the chin, more sittings are required, spaced one week apart: this is due to the greater density of hair follicles present in the region (Tab. 21.3) and the more rapid hair growth.

It is thought that fine lanugo hair may be transformed into coarse terminal hairs under the influence of hormonal changes, such as occur at menopause.

Tab. 21.3 Regional distribution of hair

Region	Follicles/cm ²
Forehead	770
Cheek (men)	770
Cheek (woman)	730
Arm	20
Forearm	100
Abdomen	40
Thigh	55
Leg	50

22

TIMEDSURGICAL PEELING

Timedsurgical peeling at low power may be used to level small scars and small cutaneous irregularities.

The technique consists of producing precisely controlled coagulation.

The first sweep of the electromaniple de-epithelialises the skin; subsequent sweeps level the dermis. Timedsurgical peeling is carried out exclusively on the face.

Small prominent hypopigmented scars left by surgical excision of facial neoformations virtually disappear after superficial peeling, which induces migration of melanocytes from the edges of the scars during the process of re-epithelialisation.

Timedsurgical peeling at high power is used to sculpt the nose during rhinophyma procedures (see section 17).

an **EM 10 Yellow** electromaniple bent at an angle is used.

For levelling small cutaneous imperfections on the face, a power between **1 and 3 Watts** is used (**Fig. 22.1.1**).

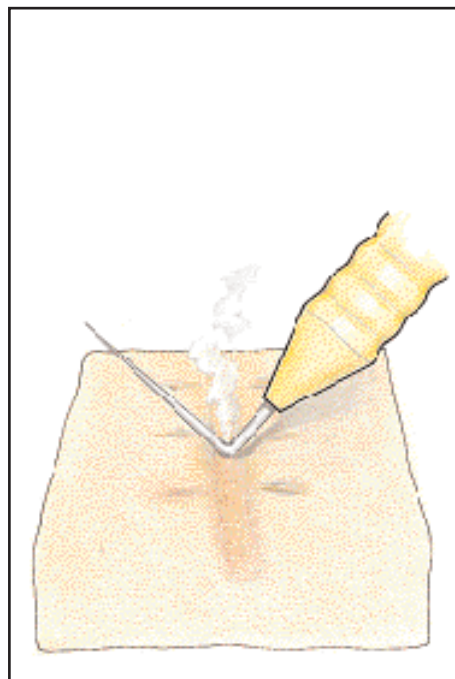
At such low powers it is sometimes necessary to increase the conductivity of the skin by moistening it with a gauze soaked in physiological saline or a non-flammable disinfectant. The skin should be illuminated by a tangential light source in order to show up surface imperfections.

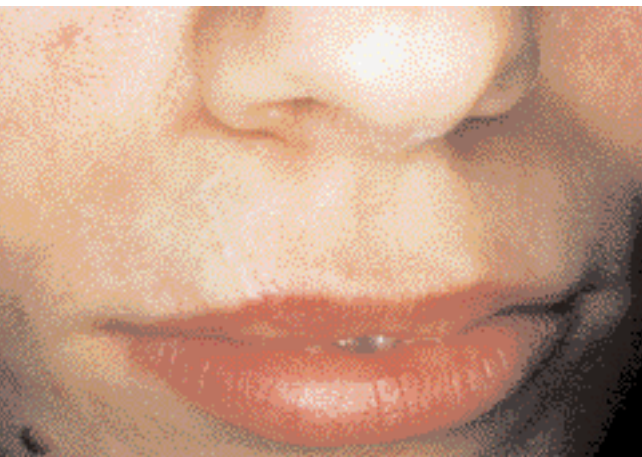22.1 Peeling at low power

Programme data

Direct - Coag microelectrodes - from 1 to 3 Watts - EM 10 Yellow (bent at an angle)

After placing the return electrode in contact with the patient's skin and disinfecting the area to be treated with a non-flammable solution, the operator sets the Timed unit to the direct mode, in which emission time is controlled directly by the pedal, and the function to coagulation with microelectrodes. For peeling,





Small areas can be treated without anaesthesia.

Larger areas require the application of an anaesthetic cream (EMLA) to avoid deformation of the skin surface.

Postoperatively, an antiseptic powder should be applied to the face; a dry crust forms and protects the re-epithelialising areas.

After the crusts have spontaneously fallen, the treated zone remains pink for several weeks and must be protected from UV radiation with anti-sun cream until the normal skin colour has returned.

Levelling of hypertrophic scars or acne scars is performed by means of timed surgical resurfacing, which does not heat the tissues and is more efficacious.

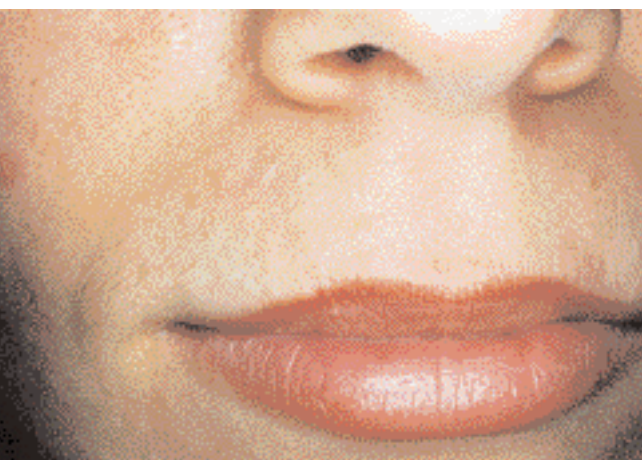
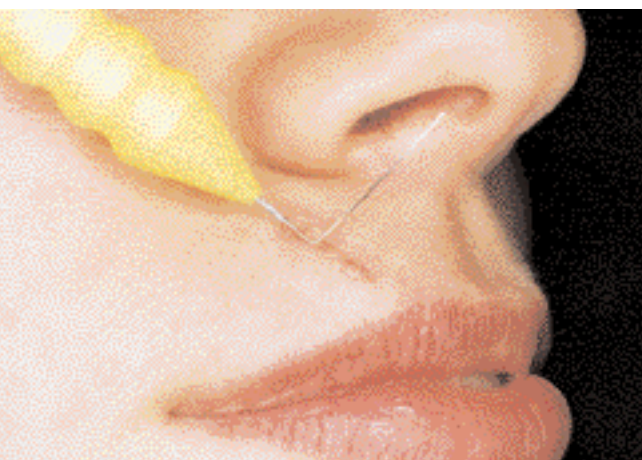
Fig. 22.1.1 Peeling can be used to level a small prominent scar. Programme data: **coagulation with microelectrodes, 2 Watts, EM 10 Yellow** electromaniple, bent at an angle.

23

TIMEDSURGICAL RESURFACING FOR LEVELLING SCARS

Programme data:

Direct pulsed 0.3/5.3 hundredths of a seconds - Cut - 50 or 72 Watts - EM 15

Timedsurgical resurfacing is a technique used to level the surface of the skin and scars (**Fig. 23.0.1**), including acne scars. The technique uses a high-power pulsed emission and an extremely short emission time.

Its action may be very superficial or deep, according to the number of sweeps of the electromaniple over the same area.

Timedsurgical resurfacing enables the skin to be de-epithelialised. However, this technique does not guarantee the integrity of the dermis.

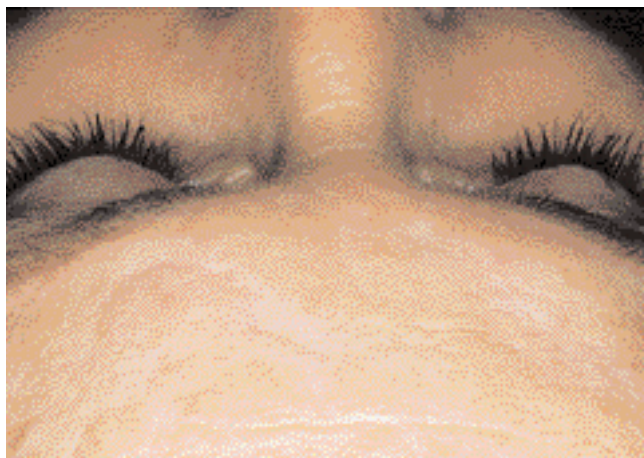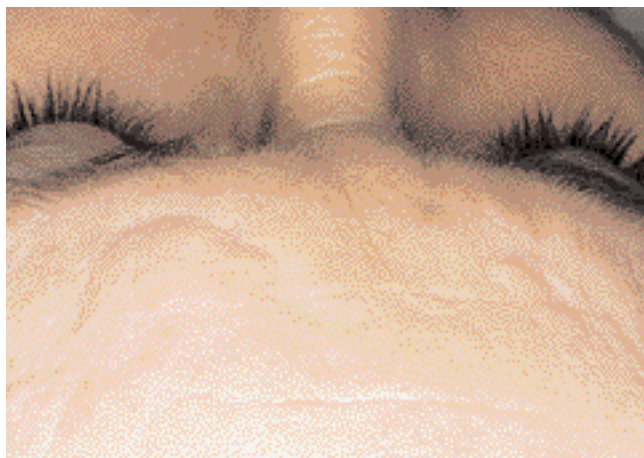

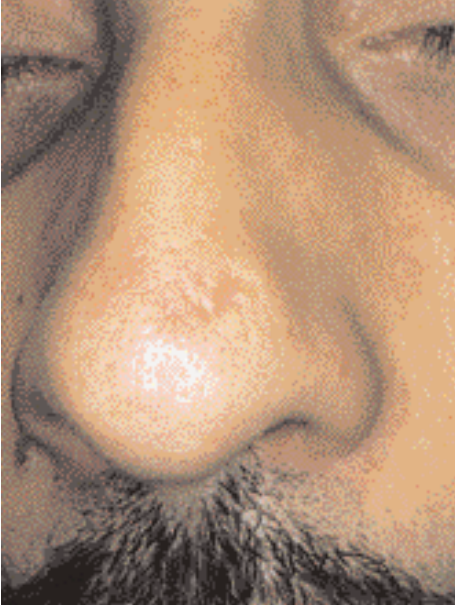
Fig. 23.0.1 Uneven scars from a road accident. Timedsurgical resurfacing. Programme data: cut, pulsed 0.3/5.3 hundredths of a second, 50 Watts, EM 15 electromaniple. Local anaesthesia. Result after one resurfacing session.



23.1 Technique

To level hypertrophic or pitted scars and acne scars the cutting function is used and power is set to **50 or 72 Watts (Fig. 23.1.1-3)**.

During resurfacing, the tip of the **EM 15** electromaniple must be kept clean by using P100 abrasive paper.

This technique may be combined with other techniques; for example, acne scars which are deep can be removed or raised with slow pulsed timed cutting; extensive scars may be levelled by several times surgical resurfacing sessions.

The operator first places the neutral electrode in contact with the patient's skin and disinfects the operating site with a non-inflammable solution. The Timed apparatus is then set to the direct mode and to the pulsed mode with the shortest

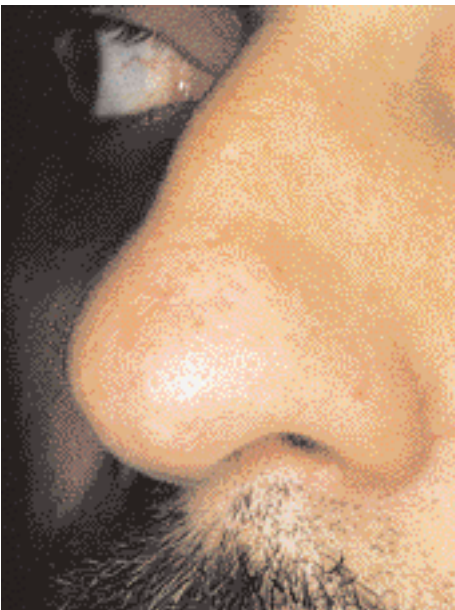
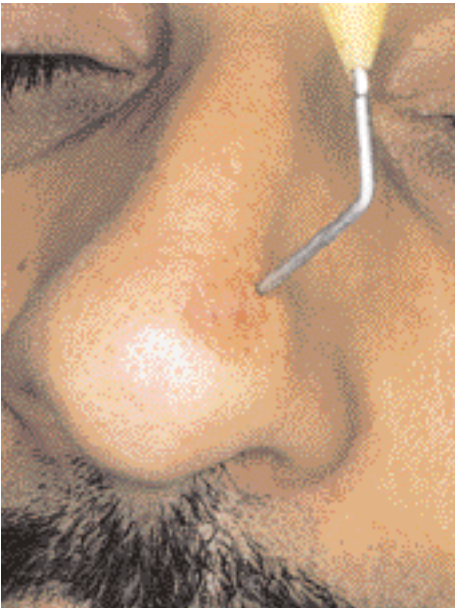
Fig. 23.1.1 Pitted scar. Timesurgical resurfacing. Programme data: **cut, pulsed 0.3/5.3 hundredths of a second, 50 Watts, EM 15** electromaniple. Local anaesthesia. Result after two resurfacing sessions.

activation time, **pulsed 0.3/5.3 hundredths of a second.**

An **EM 15** electromaniple is fitted. Local or topical anaesthesia is performed.

First, the tip of the electromaniple is passed over the skin in order to de-epithelialise it. The tip then passes closely over the surface of the skin in regular sweeps. A micro-arc is generated between the electromaniple tip and the skin. Several sweeps are performed. Resurfacing is continued on the dermis until the desired result is obtained.

During resurfacing, it is particularly useful to illuminate the operating field with a tangential light; this shows up the imperfections of the skin.

After the operation, the treated area is left exposed to the air or sprinkled with antiseptic powder.

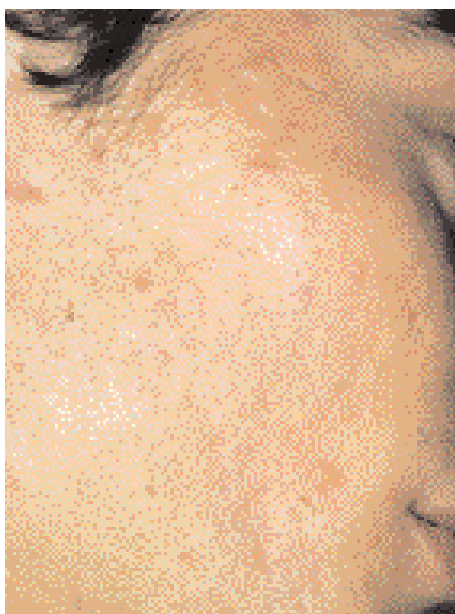
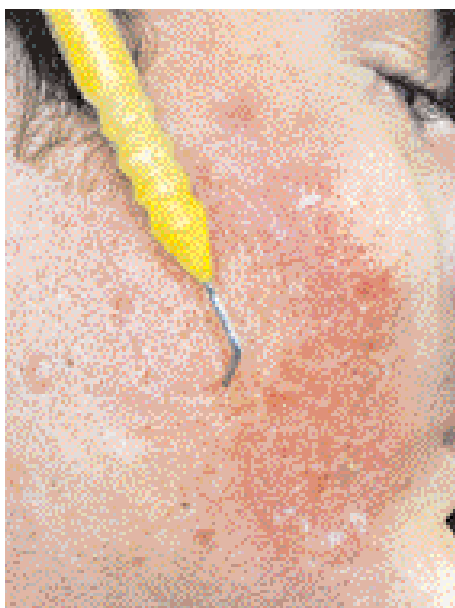
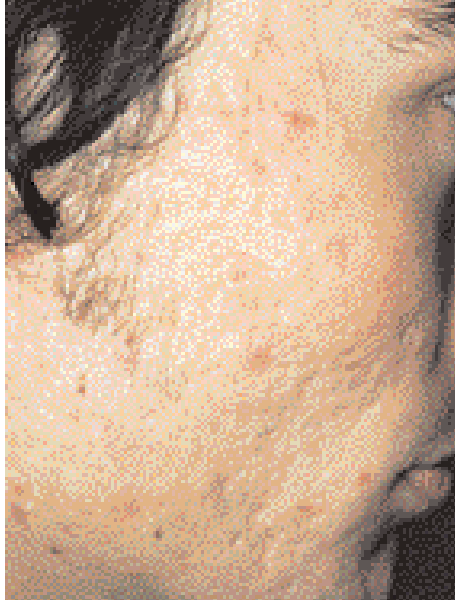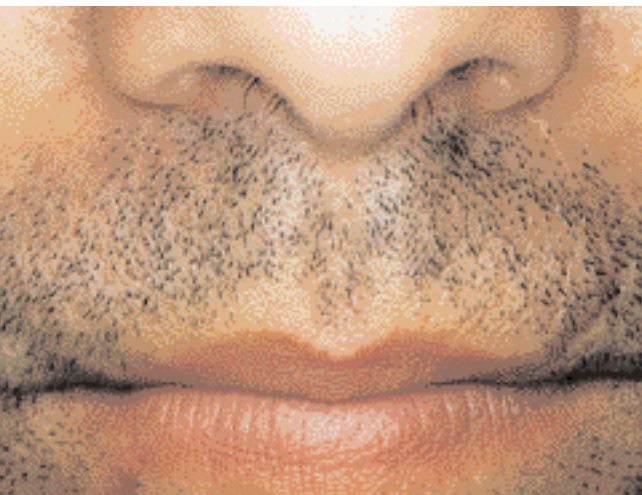Fig. 23.1.2 Scars resulting from acne. Timedsurgical resurfacing. Programme data: **cut, pulsed 0.3/5.3 hundredths of a second, 50 Watts, EM 15** electromaniple. Local anaesthesia.



A thin crust forms which detaches after one or more weeks, leaving a patch of reddened skin.

The redness does not last long, since the heat generated by resurfacing does not involve deep tissues, causes only slight inflammation and does not accelerate skin aging processes.

Timedsurgical resurfacing is also used to remove tattoos. In this application the Timed is set to coagulation with microelectrodes and the power to 27 or 38 Watts (see section 27).

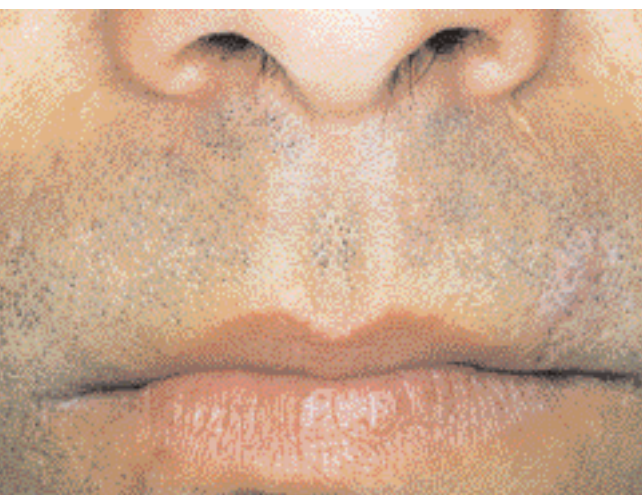
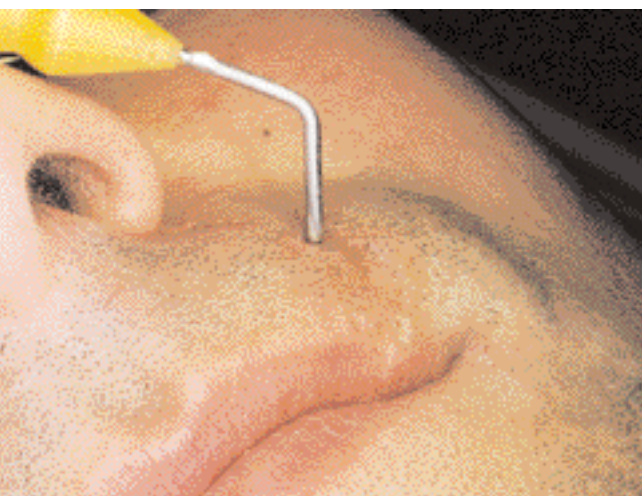
Fig. 23.1.3 Scar resulting from dog bite. Timedsurgical resurfacing. Programme data: **cut, pulsed 0.3/5.3 hundredths of a second, 50 Watts, EM 15** electromaniple. Local anaesthesia.

24

TIMEDSURGICAL DE-EPITHELIALISATION

By using a current with the correct electrical characteristics it is possible to de-epithelialise the skin (Capurro 1988).

The separation of the epidermis (**Fig. 24.0.1**) from the dermis is selective. Histological examination after de-epithelialisation shows the integrity of the derma papillae (**Fig. 24.0.2-3**). The applications of timed surgical de-epithelialisation are numerous: elimination of skin blemishes, tattoos, naevi flammei and wrinkles.

The removal of the epidermis, whose thickness varies from one person to another and also from one area of the body to another, enables the application of chemicals to the surface to be standardised. Weak chemical substances, which may have little or no effect when applied to intact skin, may have a marked effect on de-epithelialised skin, equal to strong chemical peeling agents (e.g. phenol and trichlo-

racetic acid), but with a uniform and constant action. Traditional chemical peeling must overcome the barrier of the epidermis and therefore acts in an irregular manner.

Mixed peeling (the name given to timed surgical de-epithelialisation followed by the application of a weak chemical substance) has eliminated the difficulties and irregularities of traditional chemical peeling. The chemical solutions which may be applied after de-epithelialisation are: sodium chloride and resorcin.

With this technique there is no risk of acting inadvertently on an adjacent area, because the chemical agent will only act where the skin has been de-epithelialised. During timed surgical de-epithelialisation there is no bleeding, as the plane of the dermis papillae is avascular.

De-epithelialised skin is the optimum surface to receive grafts of cultivated keratinocytes and melanocytes, thus

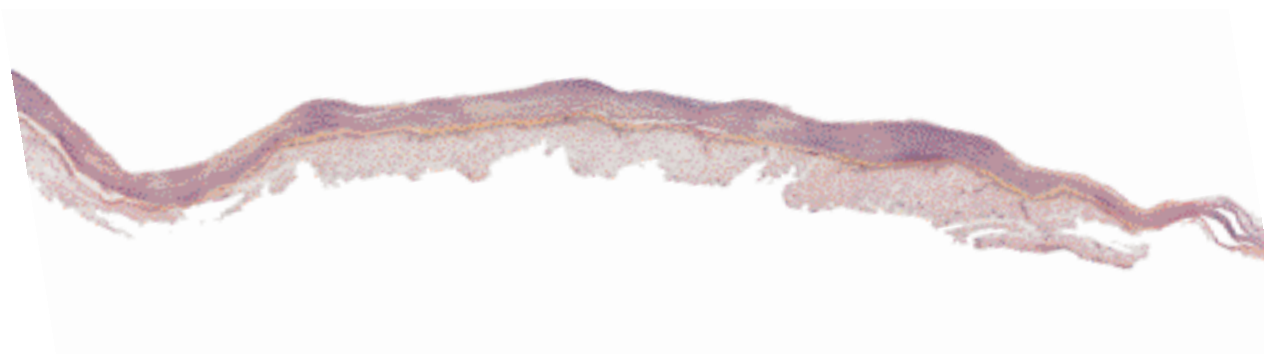


Fig. 24.0.1 Section of epidermis detached by means of timed surgical de-epithelialisation at 1 Watt.

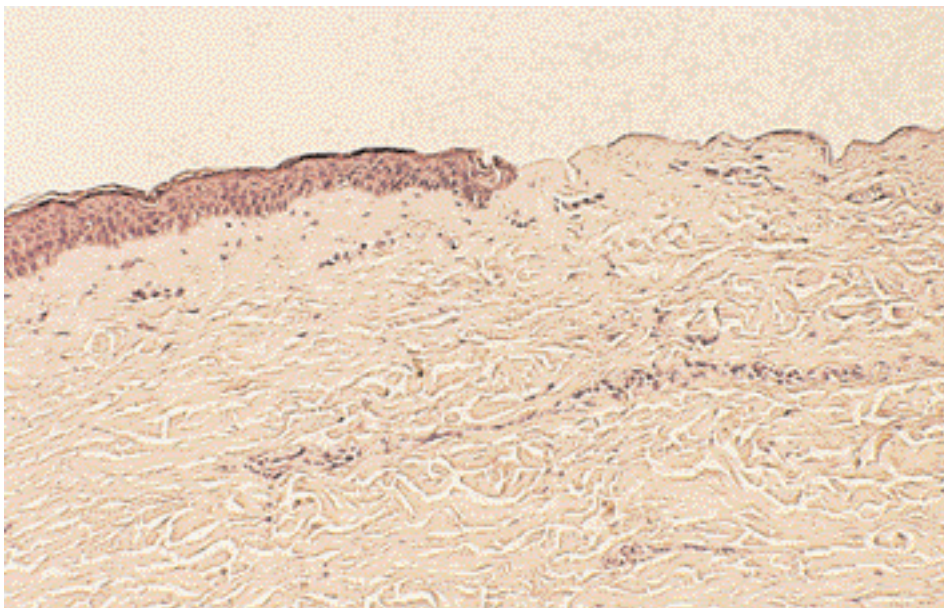


Fig. 24.0.2 On the left, intact skin. On the right, skin de-epithelialised by means of timed surgical current. Section of human skin, facial region. Haematoxylin - eosin; magnification 125 x.

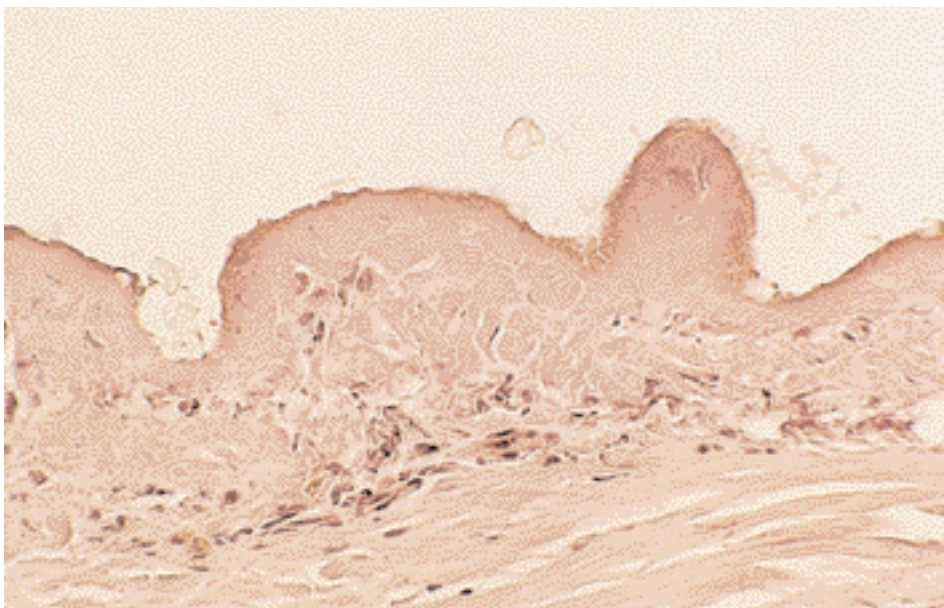


Fig. 24.0.3 The dermal papillae are intact following de-epithelialisation. Programme data: coagulation with microelectrodes, 1 Watt, EM 10 Yellow electromanipule, bent at an angle.

allowing depigmented areas to be repigmented (Capurro 1993).

Timedsurgical de-epithelialisation can be carried out by any of three programmes and with either of two types of electromaniple, in accordance with specific procedures.

24.1 Characteristics of the timed surgical current

For correct de-epithelialisation, it is necessary to avoid the formation of a spark between the electrode and the tissues. Sparking is a frequent feature of traditional electrosurgery. The sparks damage the dermis and may cause scarring. Fulguration causes superficial drying, which forms a barrier to the absorption of any chemical substance which may be applied afterwards.

The power system of the Timed apparatus is designed to avoid this problem, and to obtain a correct action on the epidermis.

24.2 De-epithelialisation at 1 Watt

Programme data

Direct - Coag microelectrodes - 1 Watt - EM 10 Yellow (bent at an angle)

After disinfecting the operating area and placing the neutral electrode in contact with the patient's skin, the operator sets the Timed apparatus to the direct mode and to coagulation with microelectrodes. Power is set to **1 Watt**. An **EM 10 Yellow**

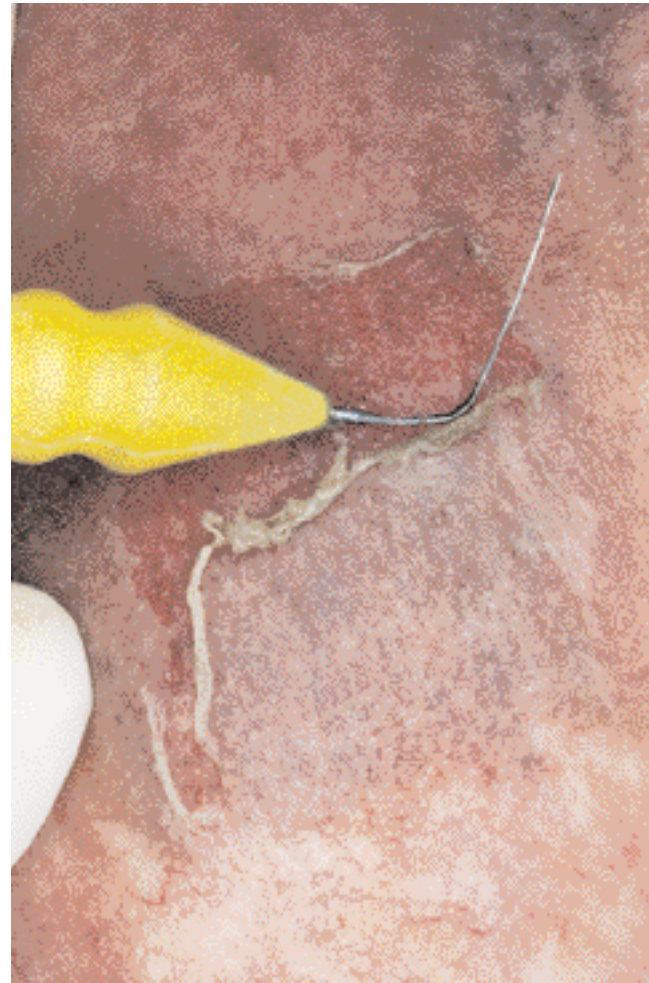


Fig. 24.2.1 Mixed peeling of naevus flammeus. Timedsurgical de-epithelialisation. Programme data: **coagulation with microelectrodes, 1 Watt, EM 10 Yellow** electromaniple, bent at an angle. Local anaesthesia.

electromaniple bent at an acute angle is inserted. The procedure is carried out under a magnifying lens. The operator gently skims the surface of the skin with the edge of the angle of the electromaniple, carrying out small regular circular movements.

The skimming action reduces the area of contact between the electromaniple and the skin and increases the energy density at the point of contact, therefore allowing an efficacious result to be obtained at **1 Watt**. If the skin is particularly dry and non-conductive, it must be moistened with an aqueous saline solution. The coagulated epidermis is removed by using the electromaniple with the power off. (**Fig. 24.2.1-2**). During de-epithelialisation the electromaniple must be cleaned frequently so that current flow through it is not impaired.

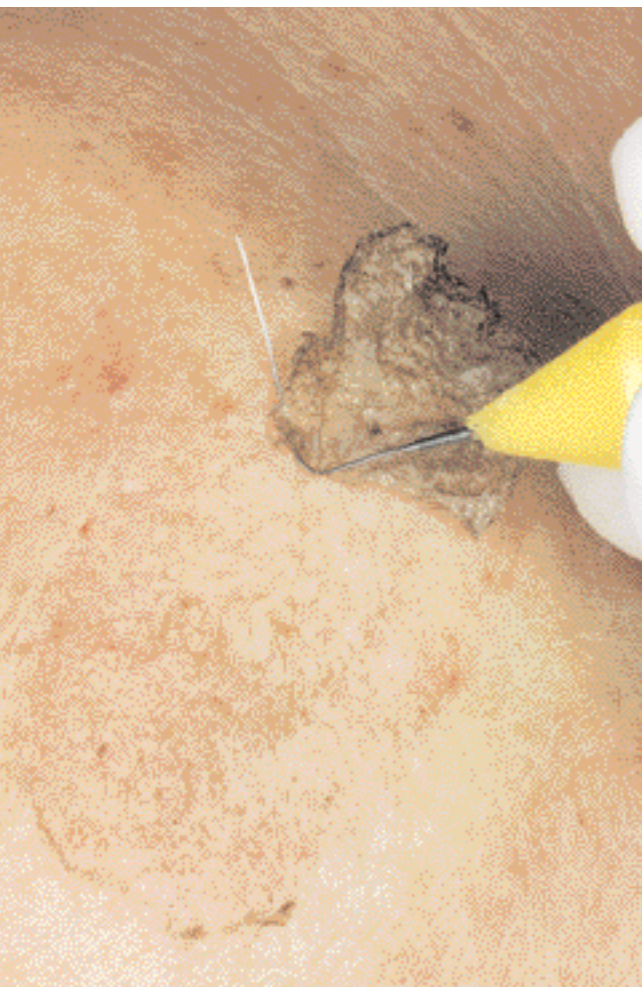

Fig. 24.2.2 Mixed peeling of dermo-epidermal pigmentation. Timedsurgical de-epithelialisation. Programme data: **coagulation with microelectrodes, 1 Watt, EM 10 Yellow** electromaniple bent at an angle. Local anaesthesia.

24.3 Pulsed de-epithelialisation

Programme data

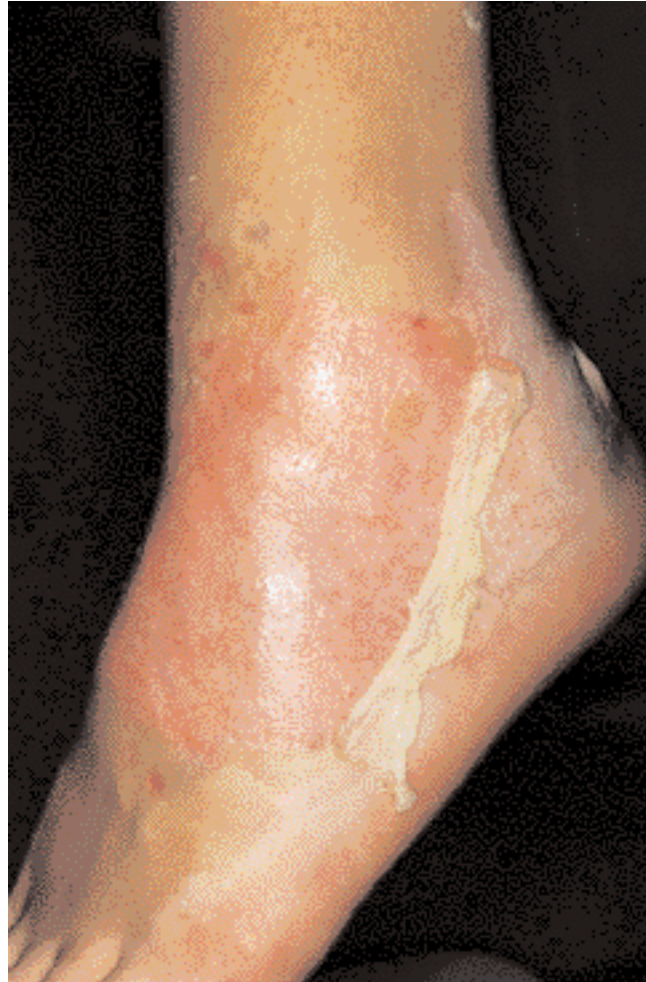Direct pulsed 4/9 hundredths of a second - Coag microelectrodes - 1 or 2 Watts - EM 10 Yellow
(bent at an angle)

De-epithelialisation with a current pulsed at **4/9 hundredths of a second** is carried out over areas where it will be necessary to apply grafts of keratinocytes and melanocytes for re-pigmentation of stabilised vitiligo and achromic scars (**Fig. 24.3.1**).

In addition to leaving the dermal papillae intact, pulsed de-epithelialisation does not damage the superficial capillary plexus. The integrity of this vascular network (**Fig. 24.3.2-3**) is of considerable importance in enabling cultivated keratinocytes and melanocytes to take root.

Pulsed de-epithelialisation is also used in mixed peeling to eliminate wrinkles on the eyelids (**Fig. 24.3.4**).

Fig. 24.3.1 Pulsed timed surgical de-epithelialisation for the treatment of stabilised vitiligo. Cultivated melanocytes and keratinocytes have been grafted onto the dermis. Programme data: **pulsed 4/9 hundredths of a second, coagulation with microelectrodes, 2 Watts, EM 10 Yellow** electromaniple, bent at an angle. Local anaesthesia. The capillary-papillary plexus appears intact.



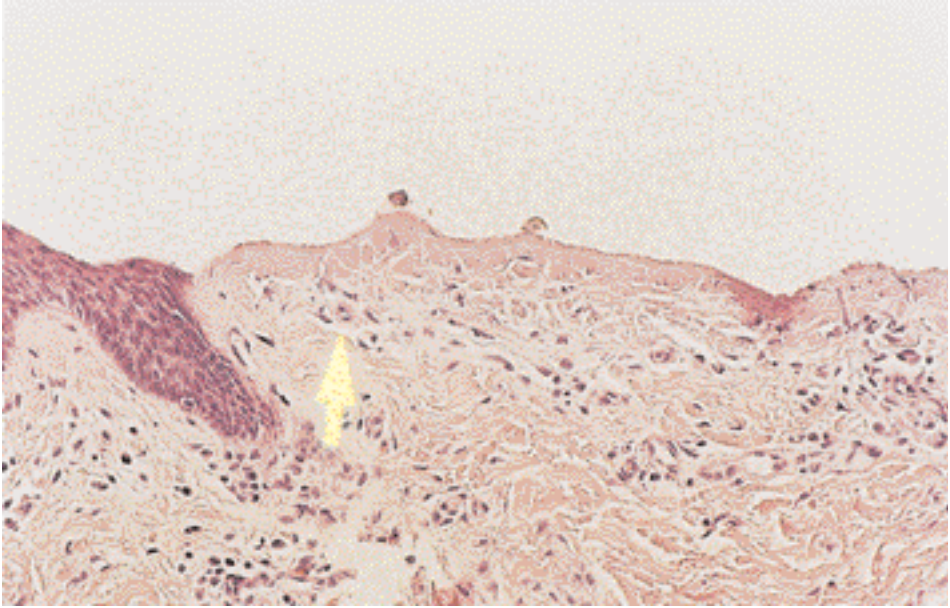


Fig. 24.3.2 Pulsed timed surgical de-epithelialisation. The capillary-papillary plexus is intact.

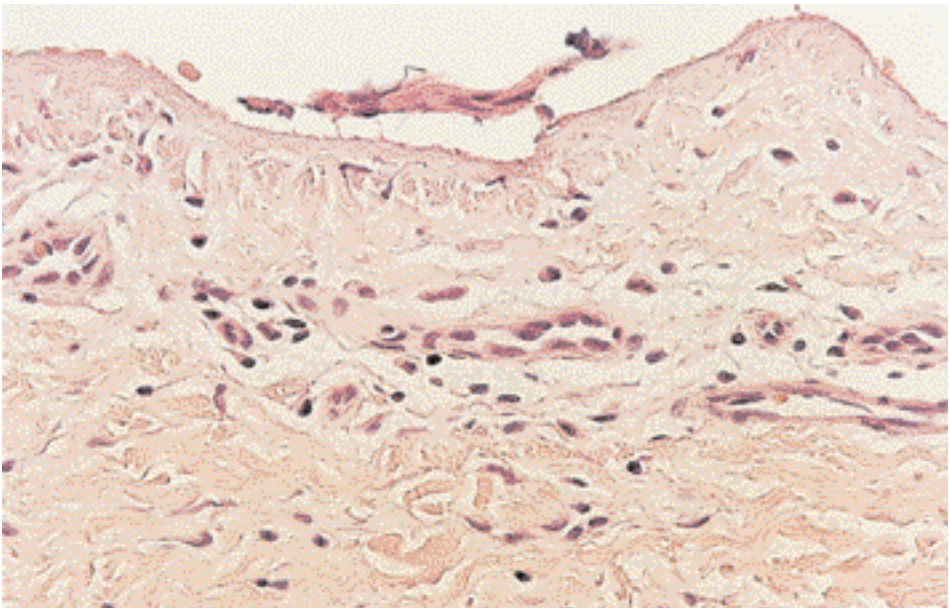


Fig. 24.3.3 Enlargement of the intact capillary-papillary plexus. Programme data: **pulsed 4/9** hundredths of a second, **coagulation with microelectrodes, 1 Watt, EM 10 Yellow** electromaniple, bent at an angle.

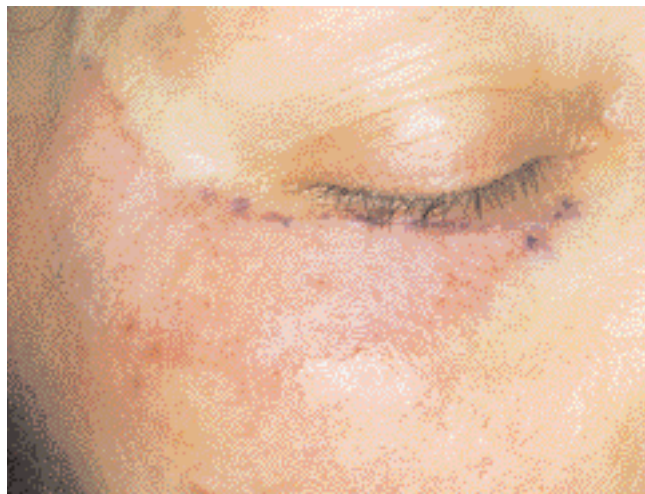
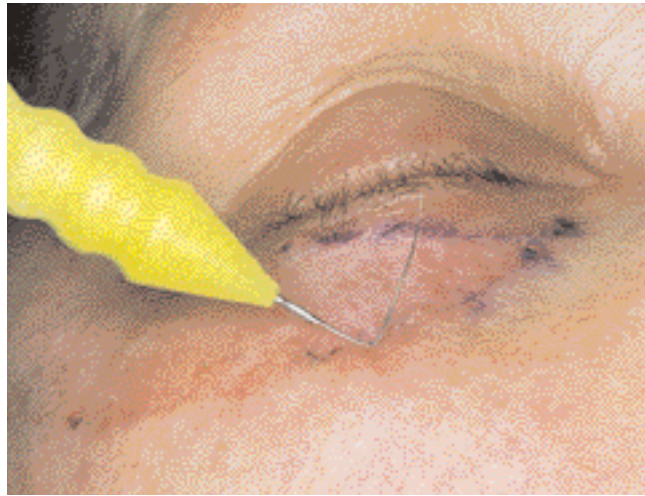
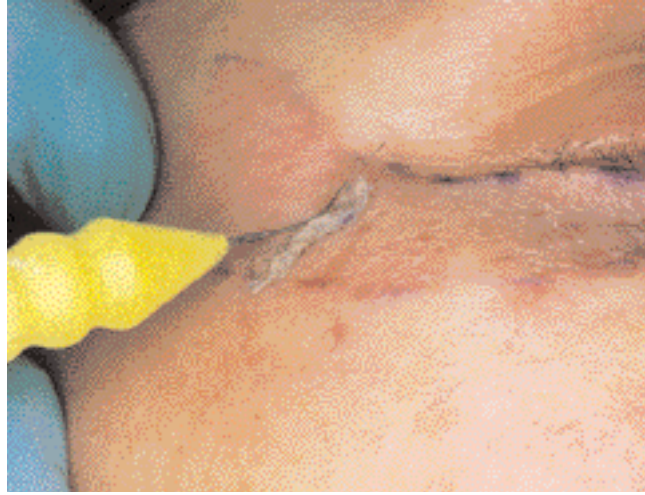


Fig. 24.3.4 Mixed peeling to eliminate eyelid wrinkles. After de-epithelialisation, a non-saturated resorcin solution is applied for a few seconds. Programme data: **pulsed 4/9 hundredths of a second, coagulation with microelectrodes, 1 Watt, EM 10 Yellow** electromaniple, bent at an angle. Local anaesthesia.

24.4 De-epithelialisation over medium-sized or larger areas

Programme data

Direct - Coag microelectrodes - 14 or 20 Watts - EM 15

Once the return electrode has been placed in contact with the patient's skin and the area disinfected, a local anaesthetic is given. The Timed apparatus is then set to the **direct** mode and the function to **coagulation with microelectrodes**.

Power is set to **14** or **20 Watts**, according to the size of the area to be de-epithelialised. An **EM 15** electromaniple is connected. The section of the active electrode between the tip and the corner of the angle is used in contact with the patient's skin (see appendix). Priming of the de-epithelialisation is carried out by skimming the cutaneous surface with the electromaniple, with rapid circular movements.

The electromaniple is then pressed against the skin and the epidermis is coagulated. The epidermis which collects on the electromaniple is removed (**Fig. 24.4.1**).

The circular movements of the electromaniple are smaller and less rapid when the power is low, more rapid and larger with high power. The electromaniple must never come into contact with an area which has already been de-epithelialised and must always be kept in motion; if it is allowed to stop moving, a dermal lesion will be produced. The de-epithelialised dermis initially appears white and then pink. Yellowing indicates an incorrect lesion. The technique of de-epithelialisation described is rapid, and is used only for the electrosalting of tattoos covering medium-sized or large areas.

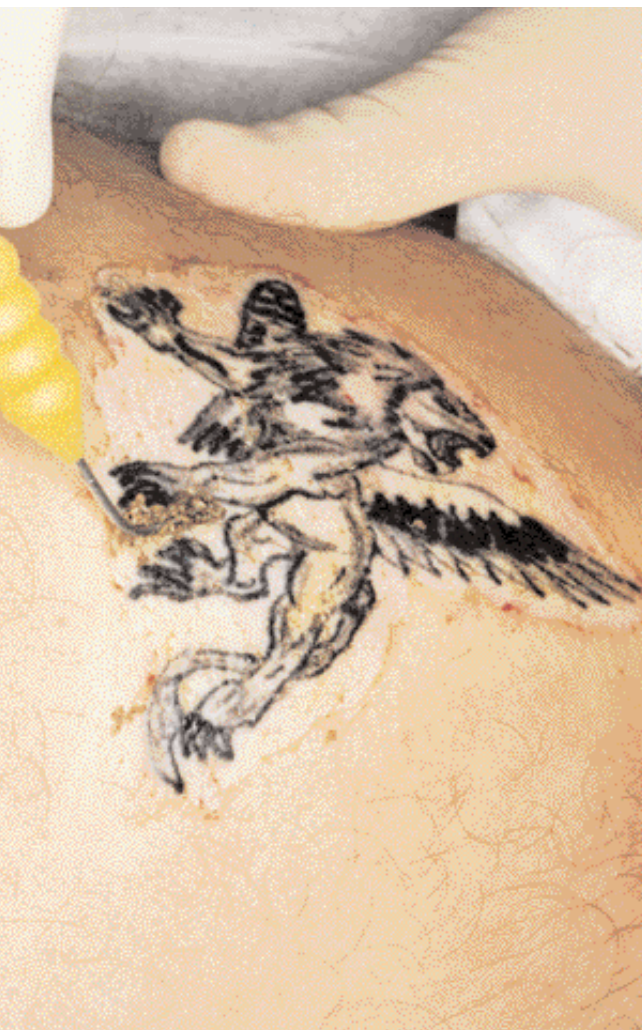

Fig. 24.4.1 Mixed peeling of a moderately large tattoo. Timedsurgical de-epithelialisation. During de-epithelialisation the epidermis is collected on the electromaniple. Programme data: **coagulation with microelectrodes, 14 Watts, EM 15** electromaniple. Local anaesthesia.

25

RE-PIGMENTATION OF STABILISED VITILIGO AND ACHROMIC SCARS

Programme data

Direct pulsed 4/9 hundredths of a second - Coag microelectrodes - 1 or 2 Watts - EM 10 Yellow (bent at an angle)

Skin which has been de-pigmented, after chemical, physical or mechani-

cal lesions, or areas affected by stabilised vitiligo, may be re-pigmented. Re-pigmentation is obtained by grafting onto the de-epithelialised depigmented area keratinocytes and melanocytes which have been freshly cultivated (Capurro 1993) (**Fig. 25.0.1-6**).

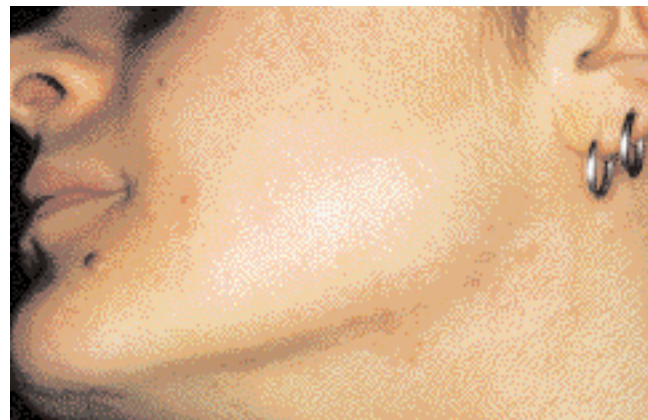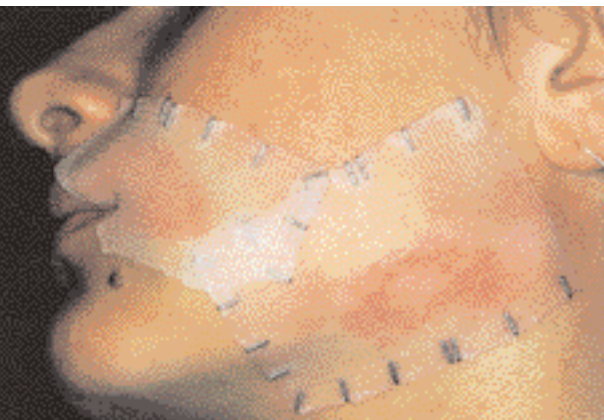

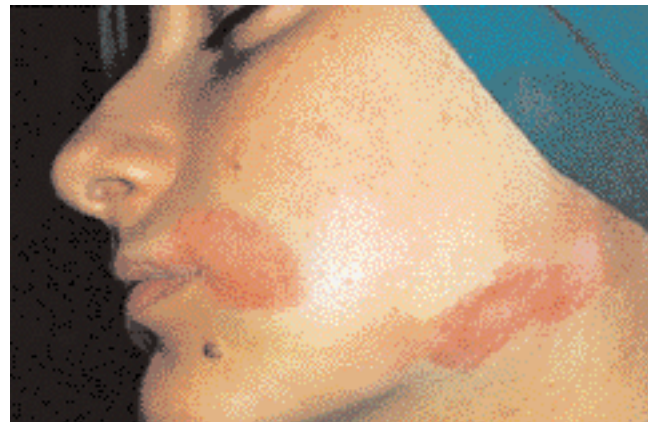
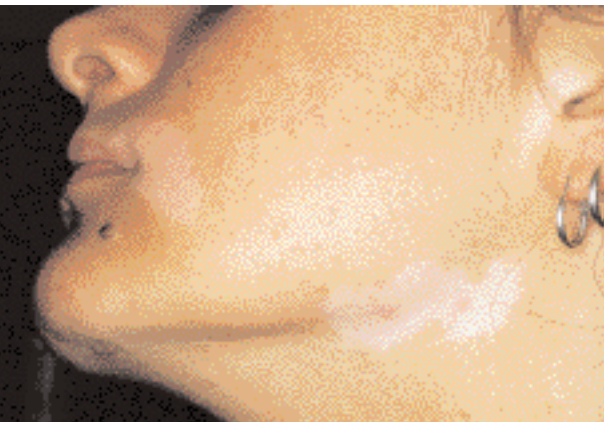Fig. 25.0.1 Stabilised vitiligo. Pulsed timed surgical de-epithelialisation and application of cultivated autologous keratinocytes and melanocytes.

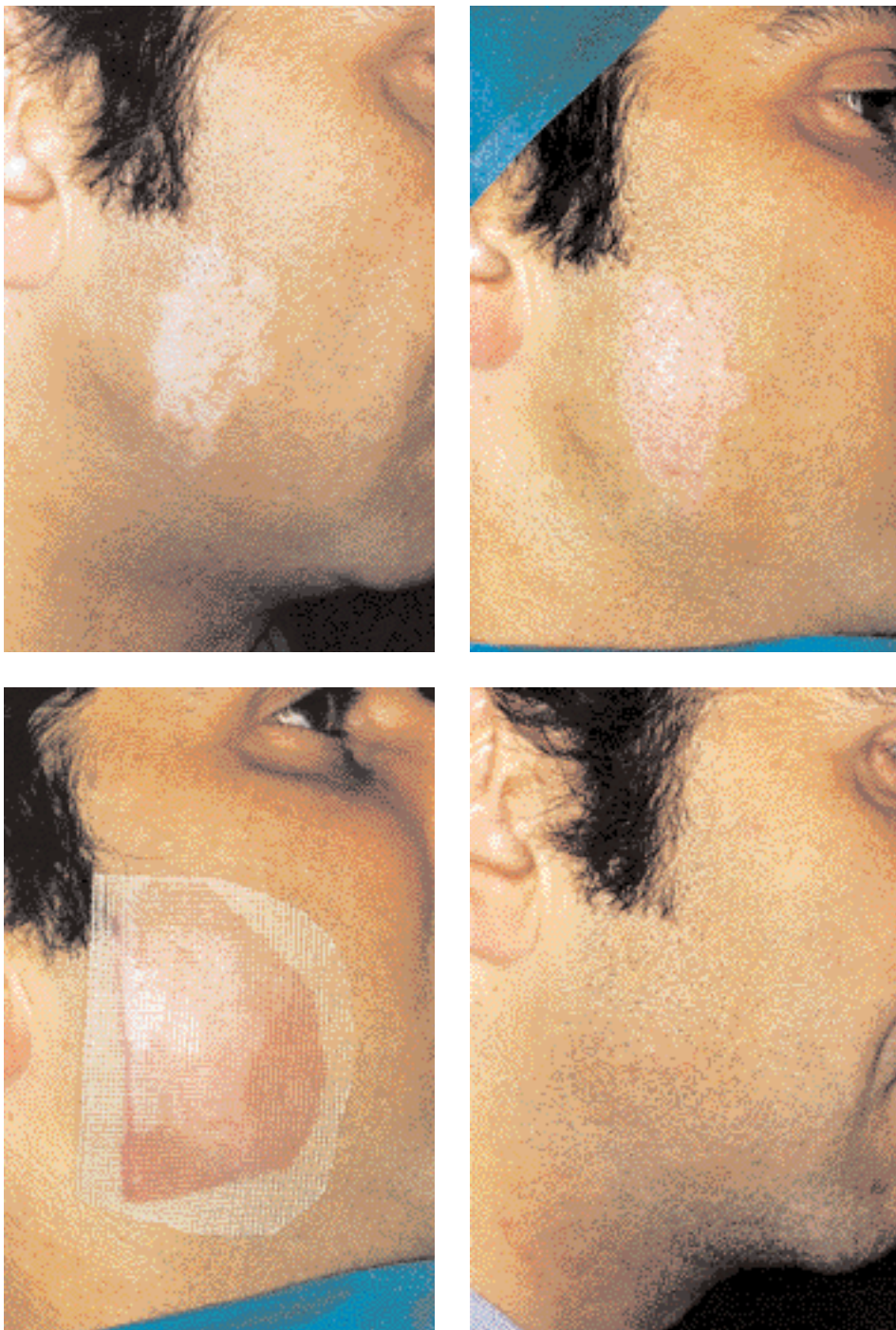
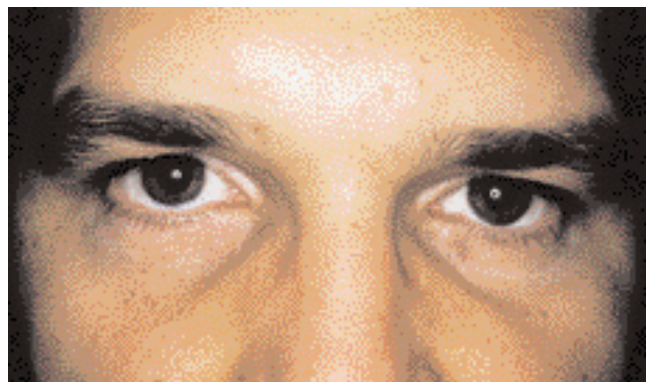
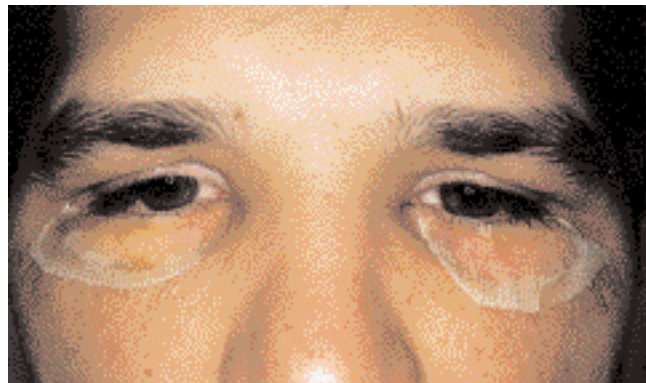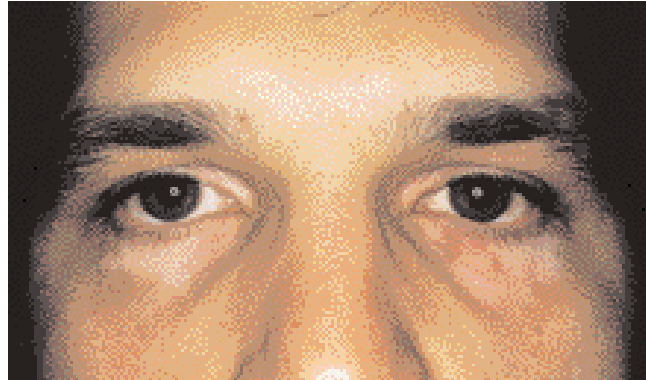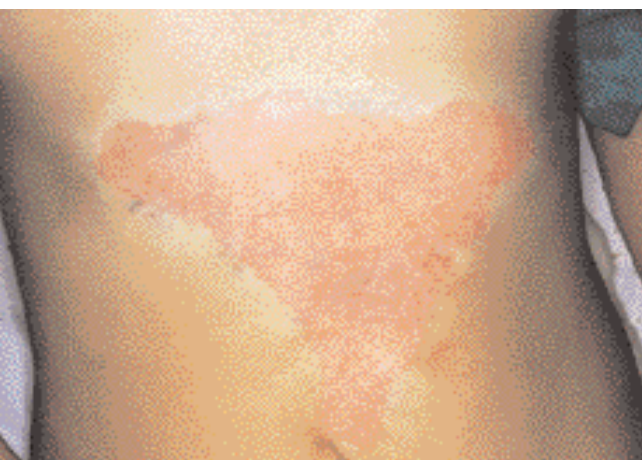
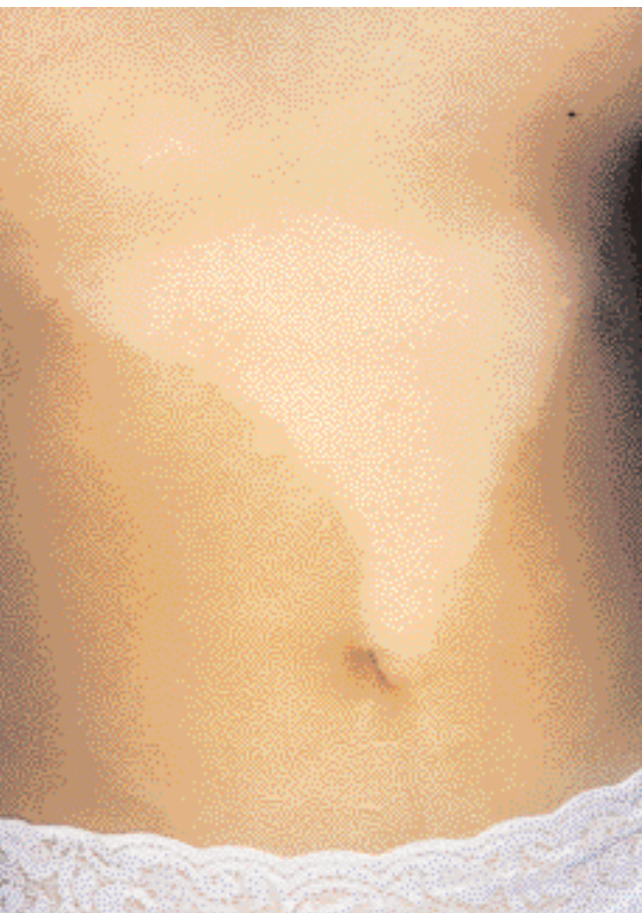Fig. 25.0.2 Pulsed timesurgical de-epithelialisation of an area affected by stabilised vitiligo. Programme data: **pulsed 4/9 hundredths of a second, coagulation with microelectrodes, 1 Watt, EM 10 Yellow** electromaniple, bent at an angle. Local anaesthesia. Result after 9 months.

The treatment consists of taking 1 square centimetre of intact skin and cultivating the epidermis in the laboratory (P. Guerra, S. Capurro, F. Melchi, G. Primavera, S. Bondanza, R. Cancedda, A. Luci, M. De Luca, G. Pellegrini; in press). Under the "Wood" light, the skin must appear uniformly pigmented. The operating field is disinfected with povidone-iodine solution and carefully washed with physiological solution. Local anaesthesia should be administered by means of mepivacaine without epinephrine. After about three weeks, an adequate amount of keratinocytes and melanocytes is ready in the correct physiological proportion. It is possible to obtain an area up to 10,000 times larger than the cutaneous sample taken. When the culture is ready, timed-surgical de-epithelialisation of the depigmented area is carried out. To facilitate de-epithelialisation, the patient should apply a 15% - 30% urea cream for 2 weeks prior to the operation.

The neutral electrode is positioned and the operating field is disinfected with povidone-iodine solution. The patient is given a local anaesthetic. The Timed micropulse apparatus is set to the **direct pulsed mode 4/9 hundredths of a second** and the **coagulation with microelectrodes** function is selected. Power is set to **1 Watt** and an **EM 10 Yellow** electromani-

Fig. 25.0.3 Stabilised vitiligo. Pulsed timed-surgical de-epithelialisation and application of cultivated autologous keratinocytes and melanocytes. Programme data: **coagulation with microelectrodes, 1 Watt, pulsed 4/9 hundredths of a second, EM 10 Yellow** electromaniple, bent at an angle. Local anaesthesia.





ple is connected. The electromaniple is bent to an acute angle. The edge of the angle skims the epidermis which, when coagulated, is easily removed with the same electromaniple, non-activated. On large areas of the limbs **pulsed** de-epithelialisation at **2 Watts** can be carried out. When the de-epithelialisation is complete, the area is thoroughly washed with physiological saline solution and the graft of cultivated keratinocytes and melanocytes is applied. The dressing, which must be stable but non-compressive, is changed after 8 days. The new epidermis is visible after 15-20 days, once the thin crust has detached. The treated area must not come into contact with soap, detergent, creams or perfumes for two months. Irritant chemical substances could damage the cells and

Fig. 25.0.4 Piebaldism. Pulsed timesurgical de-epithelialisation. Programme data: **coagulation with microelectrodes, pulsed 4/9 hundredths of a second, 1 Watt, EM 10 Yellow** electromaniple, bent at an angle. Local anaesthesia.

reduce proliferation. Two months after grafting, the patient must expose the treated area to the sun in order to stimulate repigmentation.

Repigmentation should take place uniformly over the whole surface in one year.

With exposure to the sun, the area may become darker than normal skin. Over a period of two years, this normally lightens and returns to the colour of the neighbouring skin.

Complete repigmentation can be achieved only if the condition is perfectly stable (Tab. 25.1).

As pulsed timed surgical de-epithelialisation is the only technique which maintains the integrity of the dermal structure and the vascular capillary network, it enables the cultivated keratinocyte and melanocyte graft to take root completely.

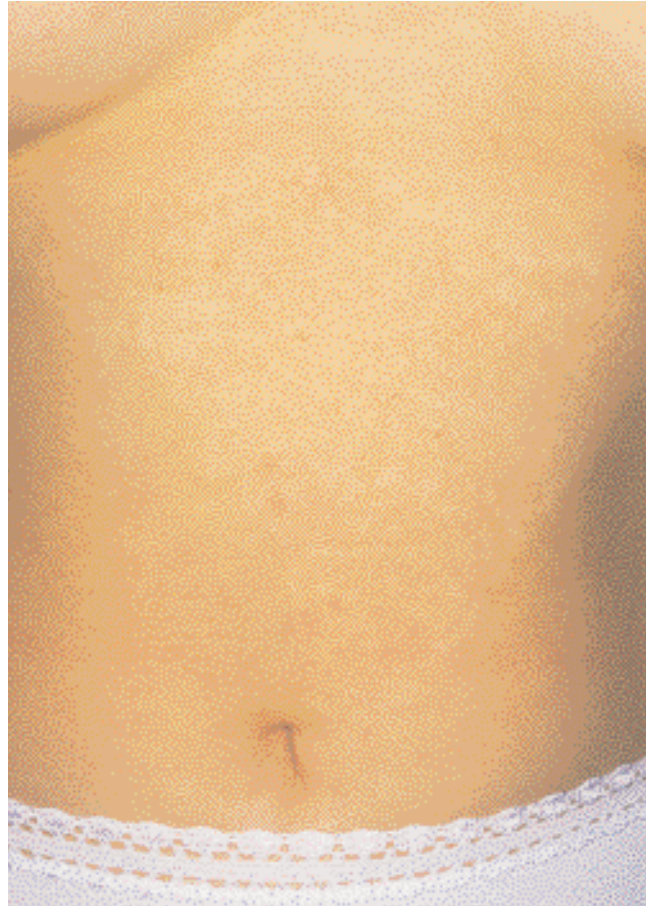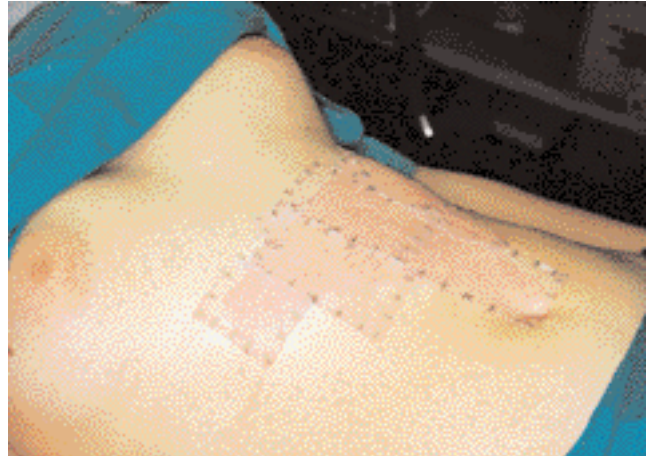


Fig. 25.0.5 Autologous keratinocytes and melanocytes, cultivated from a 1 cm² normo-pigmented skin fragment removed 20 days before grafting, are applied. Result after 11 months.

Tab. 25.1 Vitiligo stability

No new lesions appearing during the last two years.
No enlargement or modification of old lesions during the same period of time.
No new Koebner phenomenon developing during this time.
Spontaneous repigmentation at the periphery or within vitiligo lesions
(Falabella 1992).

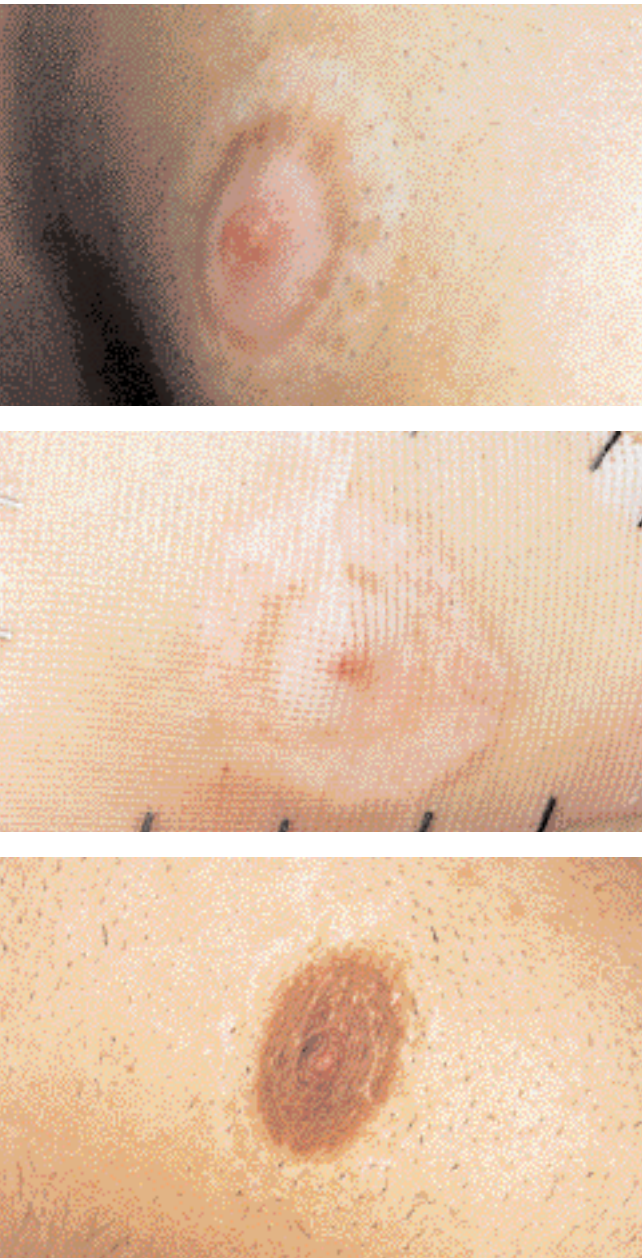


Fig. 25.0.6 Repigmentation of the areola. Keratinocytes and melanocytes cultivated from a skin fragment taken from the inguinal region have been grafted onto the de-epithelialised area. Result after 4 months.

26

ELIMINATION OF CUTANEOUS HYPERPIGMENTATION

Cutaneous hyperpigmentation may be due to a disturbance of the melanin system or to an abnormal presence in the skin of exogenous or endogenous pigment other than melanin. The first condition, or hypermelanosis, may be due either to an increased number of melanocytes or to an increased concentration of melanin in the epidermis. Often, it is not easy to distinguish between the two conditions, both because of normal variations in the content of melanin in the epidermis and because of regional and age-related differences in the density of melanocytes within the epidermis.

Melanin can also be found within macrophages in the dermis, which may impart a grey or blue colour to the pigmentation.

Pigmented lesions due to benign or malignant proliferations of melanocytes (naevi and melanomas), which may appear as pigmented lesions of the skin, are dealt with elsewhere in this handbook.

Circumscribed cutaneous hyperpigmentations without apparent proliferation of melanocytes are mainly due to increased concentrations of melanin in the epidermis (which usually produces brown hyperpigmentation). The most common disorders here encountered are:

- freckle (or ephelis): a macule found on sun-exposed skin characterised by melanocytes with a

greater capacity for melanogenesis after exposure to sunlight.

- Café au lait spot: a hyperpigmented patch which may be present at birth in the setting of neurofibromatosis or in otherwise normal persons.
- melanotic patches in Albright's syndrome.
- Becker's naevus: a malformation of the epidermis and pilo-sebaceous units.

An increased content of melanin in the epidermis can be associated to such conditions as:

- chloasma (syn. melasma).
- urticaria pigmentosa.
- macular amyloidosis.

Localised hyperpigmentation frequently represents the end stage of a prior inflammatory process which involves the dermal/epidermal junctions: localised post-inflammatory hyperpigmentation.

Among these, special mention should be made of:

- fixed drug eruption, Berloque dermatitis (phototoxicity induced by topical application of oil of bergamot), "erythema ab igne" a consequence of long-standing thermal injury).

Increased melanin in the epidermis can also be found in a variety of skin lesions characterised by proliferation, whether non-neoplastic or neoplastic, benign or malignant:

- melanosis of the vulva.

- solar lentigo (syn. senile lentigo, liver spot, old age spot), a benign pigmented macule on skin damaged by years of exposure to sunlight, most commonly situated on the face and the backs of the hands and wrists, neck and chest and extensor surfaces of forearms.
- lichen-planus-like keratosis.
- reticulated seborrheic keratosis.
- reticulated pigmented anomaly of the flexures (the Dowling-Degos anomaly, symmetrical reticulated hyperpigmentation of the body folds).

Increased content of melanin both in the epidermis and the dermis can be found in the following conditions:

- seborrheic keratosis (hyperpigmented keratinocytes and melanin in macrophages in the upper part of the dermis).

- pigmented solar keratosis;
- pigmented Bowen's disease;
- bowenoid papulosis;
- pigmented squamous cell carcinoma;
- pigmented keratoacanthoma;
- pigmented basal cell carcinoma.

Slight extensive hyperpigmentation of the face (e.g. chloasma) is not amenable to timed surgical treatment; rather, such areas are treated with depigmenting creams, which are applied daily to the affected area. Timed surgery is able to eliminate pigmentation caused by increased concentrations of melanin. If the hyperpigmentation is small and epidermal, superficial timed surgical coagulation is used (Tab. 26.1). If the hyperpigmented lesions are very evident, or slightly raised, or doubt exists as to whether the pigment is entirely localised in the epidermis, a resorcin solu-

Tab. 26.1 Treatment of hyperpigmentation

Superficial timed surgical coagulation	Direct - Coag microelectrodes 1 Watt - EM 15	Small facial lentigines (epidermal hyperpigmentation)
Pulsed superficial timed surgical coagulation	Direct pulsed 4/9 hundredths of a second - Coag microelectrodes 1 or 2 Watts - EM 15	Lentigines of the hands (two sessions)
Pulsed timed surgical de-epithelialisation	Direct pulsed 4/9 hundredths of a second - Coag microelectrodes 1 or 2 Watts - EM 10 (bent at an angle)	Large epidermal hyperpigmentations resistant to depigmenting substance
Timed surgical de-epithelialisation and application of a saturated resorcin solution (mixed peeling)	Direct - Coag microelectrodes 1 Watt - EM 10 Yellow (bent at an angle)	Facial lentigines (Dermal-epidermal hyperpigmentation) application of resorcin for 20 seconds

tion must be applied to the de-epithelialised marks for a few seconds.

Topical or local anaesthesia is used.

Post-inflammatory hyperpigmentation must be treated by means of timed surgery at least three years after its onset. Indeed, some areas of hyperpigmentation may fade within that time, while others may persist indefinitely.

Timed surgery can also be used efficaciously to treat inflammatory linear verrucous epidermal naevi (ILVEN).

26.1 Epidermal hyperpigmentation

Programme data

Superficial timed surgical coagulation

Direct - Coag microelectrodes -

1 Watt - EM 15

Timed surgical resurfacing

Direct pulsed 0.3/5.3 hundredths of a second - Coag microelectrodes - 27 or 38 Watts - EM 15

In epidermal hyperpigmentation, the pigment is localised in the basal layer (Fig. 26.1.1).

Small solar lentigines on the face and body may be eliminated by means of superficial timed surgical coagulation (Fig. 26.1.2-4).

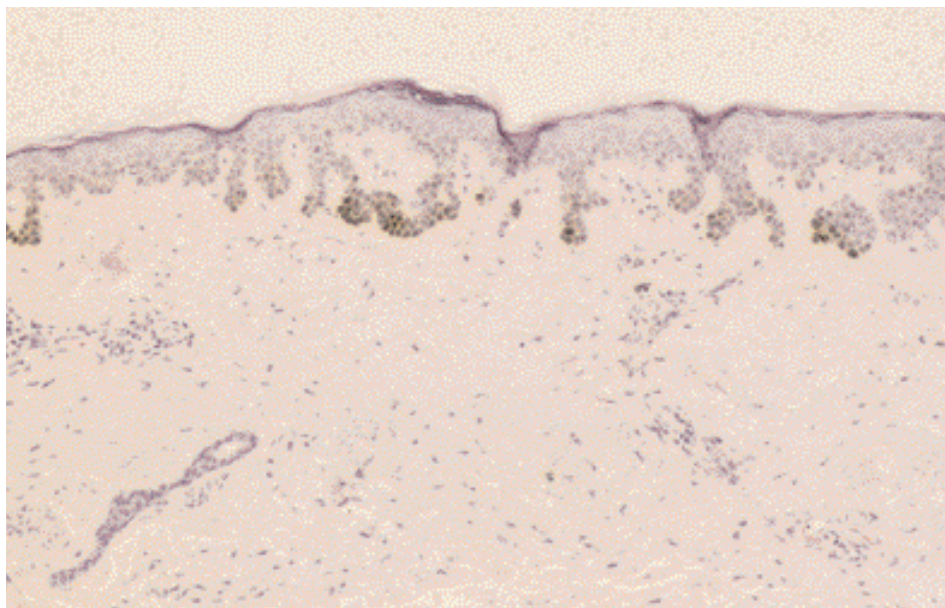


Fig. 26.1.1 Solar lentigo. Epidermal hyperpigmentation. The melanin is mostly localised in the basal layer of the epidermis.

Techniques

The neutral electrode is positioned and the operating field is moistened and disinfected with saline solution. The direct mode is selected and the apparatus is set to **coagulation with microelectrodes**. Power is set to **1 Watt** and an **EM 15** electromaniple is connected. The tip is delicately touched repeatedly onto the epidermis and coagulates the surface, which becomes lighter.

The electromaniple must be perfectly clean. The tip should be kept moving and must not remain long in the same place.

The epidermis is not removed. Healing times are brief: a week on the face.

If residual pigmentation remains, the procedure may be repeated after two months.

Very extensive areas of epidermal hyperpigmentation which are resistant to depigmenting therapy may be treated by means of pulsed timed surgical de-epithelialisation.

The innovative timed surgical resurfacing technique enables epidermal hyperpigmentation to be treated safely and efficaciously. The Timed micropulse is set to the Direct mode, coagulation with microelectrodes at a power of 27 or 38 Watts and an EM 15 electromaniple is fitted. The epidermis must not be removed.

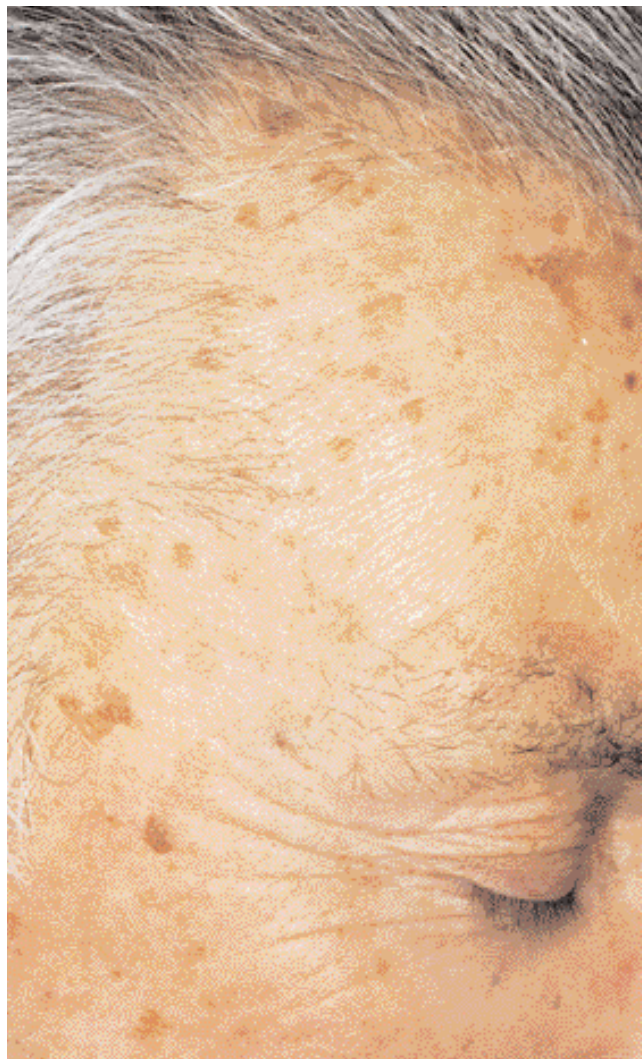


Fig. 26.1.2 Solar lentigo. Multiple small hyperpigmented areas.

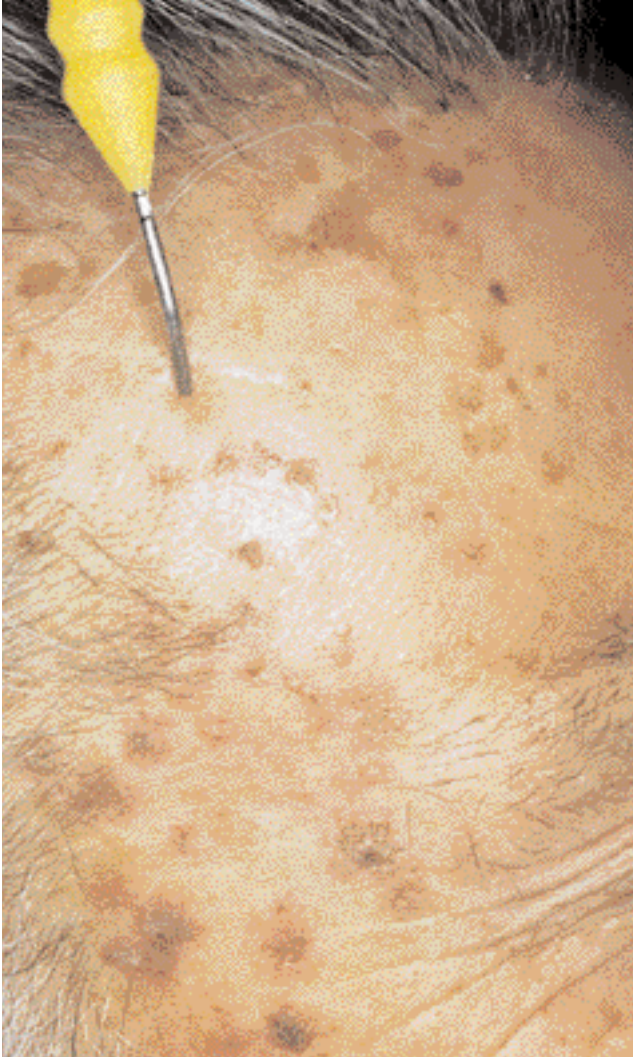


Fig. 26.1.3 Superficial timed surgical coagulation of solar lentigo. Programme data: coagulation with microelectrodes, **1 Watt, EM 15** electromaniple. Topical anaesthesia. The hyperpigmented area is repeatedly touched with the tip of the electromaniple. The coagulated epidermis is not removed.

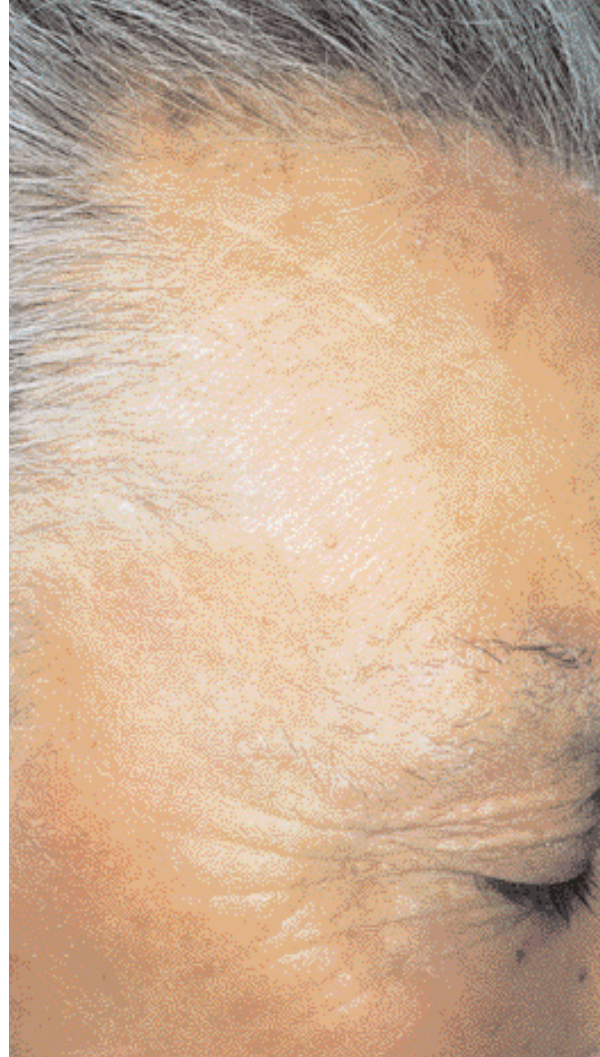


Fig. 26.1.4 Result after two sessions.

26.2 Elimination of lentigines on the hands

Programme data:

Pulsed superficial timed surgical coagulation

Direct pulsed 4/9 hundredths of a second - Coag microelectrodes - from 1 to 3 Watts - EM 15

Timed surgical resurfacing

Direct pulsed 0.3/5.3 hundredths of a second - Coag microelectrodes - 27 or 38 Watts - EM 15

Lentigines on the hands are eliminated by means of **pulsed 4/9 hundredths of a second**, following the application of a 30% urea cream for two weeks (**Fig. 26.2.1**). Two sessions are normally required. The direct mode is selected and the apparatus is set to coagulation with microelectrodes. Power is set from **1 to 3 Watts**. The tip of the **EM 15** electromaniple is touches repeatedly onto the epidermis and coagulates the surface. The epidermis is not removed. The tip of the electromaniple must be kept moving and must never dwell on one spot. The procedure is carried out under topical anaesthesia and has to be repeated after 6 months.

Timed surgical resurfacing is an extremely safe method of removing patches from the hands. When using this new technique, the epidermis must not be removed.

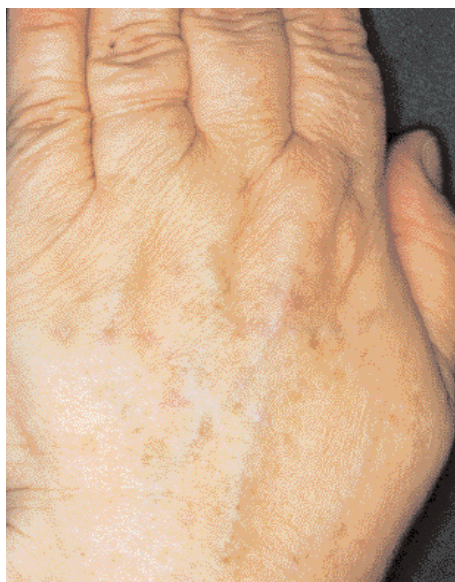
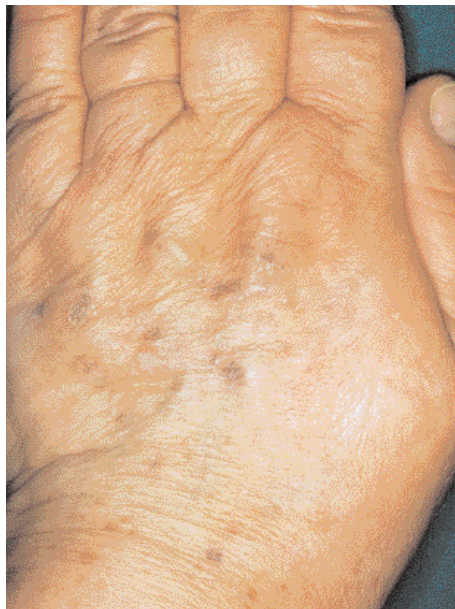
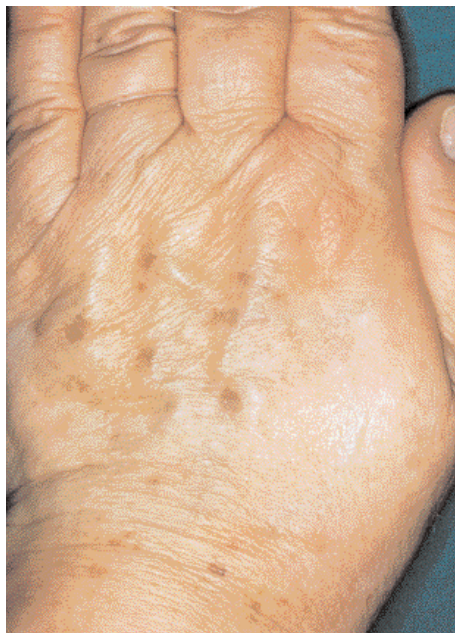Fig. 26.2.1 Patches on the hands. Superficial pulsed timed surgical coagulation. Programme data: **coagulation with microelectrodes, 2 Watts, pulsed 4/9 hundredths of a second, EM 15** eletromaniple. Topical anaesthesia. Result after one session.

26.3 Dermal-epidermal and dermal hyperpigmentation

Programme data

Timedsurgical de-epithelialisation

Direct - Coag microelectrodes - 1 Watt - EM 10 Yellow (bent at an angle)

In dermal-epidermal hyperpigmentation, the pigment is situated in the basal layer of the epidermis and in the upper part of the dermis (**Fig. 26.3.1**)

Technique

Timedsurgical de-epithelialisation is carried out at **1 Watt** with an **EM 10 Yellow** electromaniple (bent to an acute angle).

After eliminating the epidermis (see section 24.2), the operator observes the dermis through a magnifying

lens. If it appears even slightly pigmented (**Fig. 26.3.2-4**) or has an irregular surface, it is washed with an aqueous solution of resorcin (mixed peeling).

The solution is prepared by placing a small quantity of resorcin in a sterile container. The powder is dissolved in a few drops of sterile water. The resorcin is applied to the pigmented dermis with a cotton wad. After 10-20 seconds the de-epithelialised area whitens and the operator immediately removes the resorcin with a gauze soaked in physiological saline solution. Hyper-pigmentation of the dermis undergoes the same treatment, but the resorcin solution is applied for a longer time.

On the face, the area is left exposed to the air; on the body it must be protected with a non-adherent dressing. Owing to the coagulative properties of resorcin, a crust forms on the face after a few hours, and

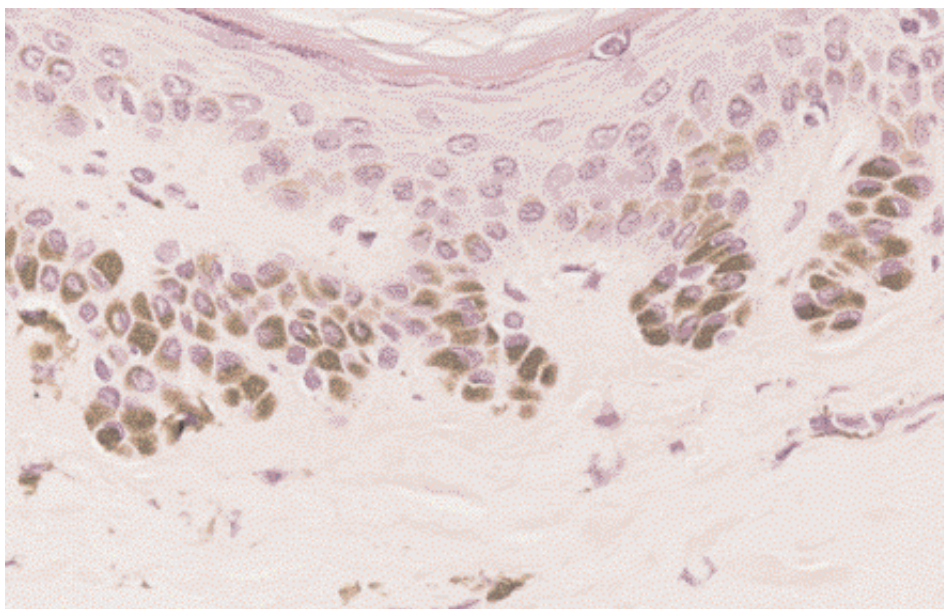
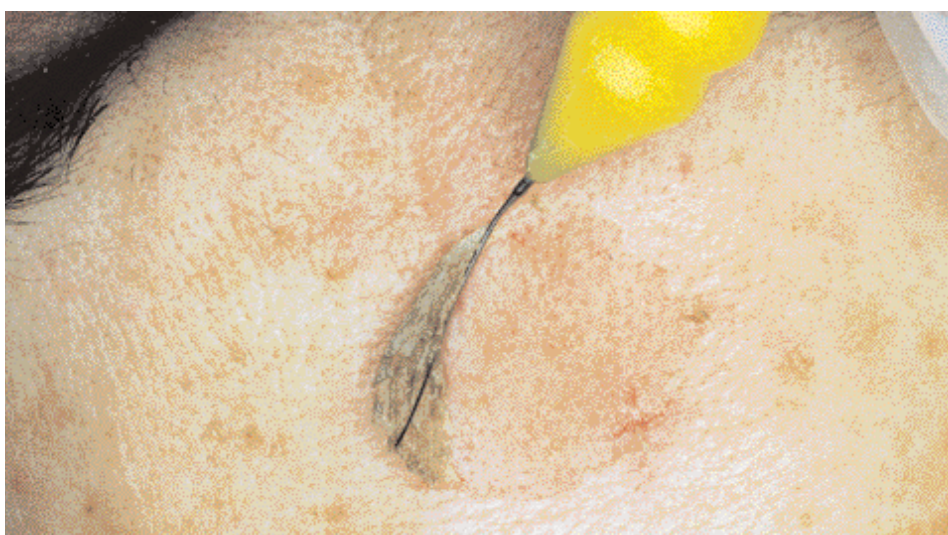
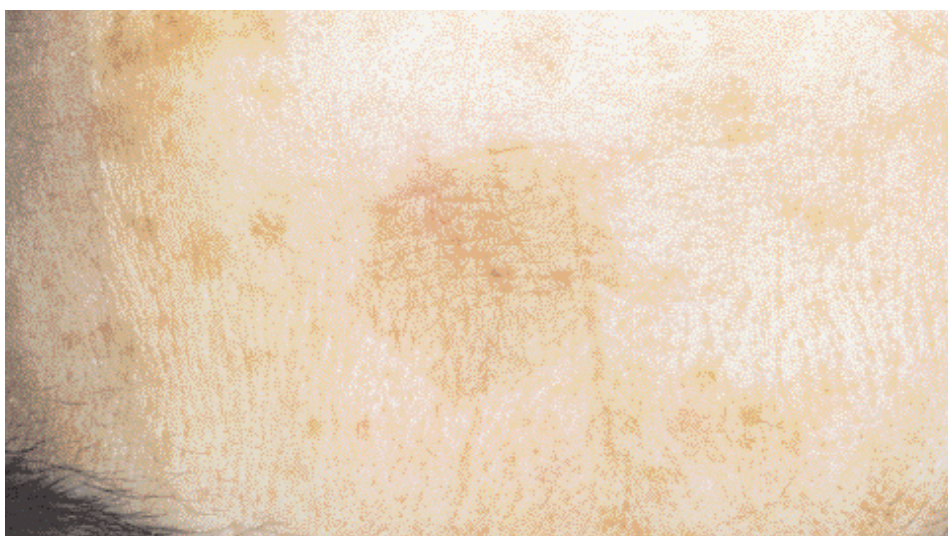
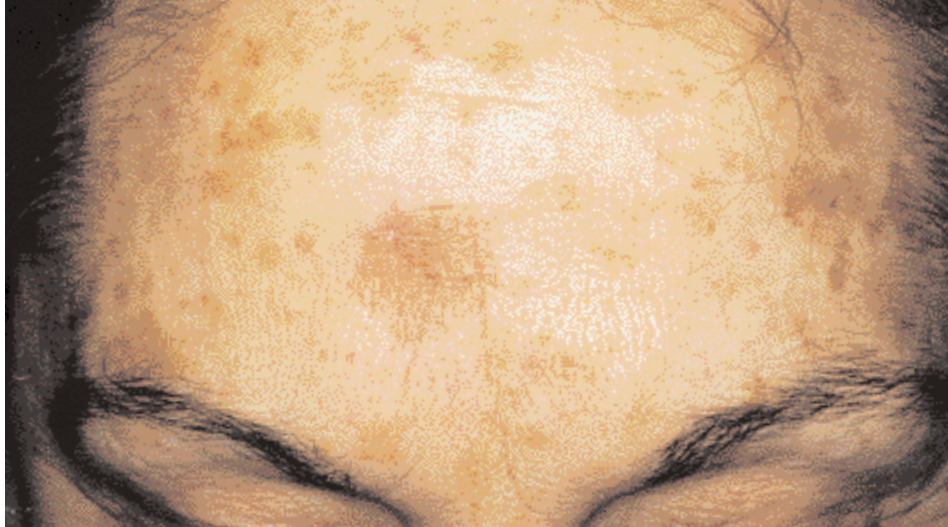Fig. 26.3.1 Solar lentigo. Dermal-epidermal hyperpigmentation. Abnormal concentration of melanin in the epidermis and dermis.



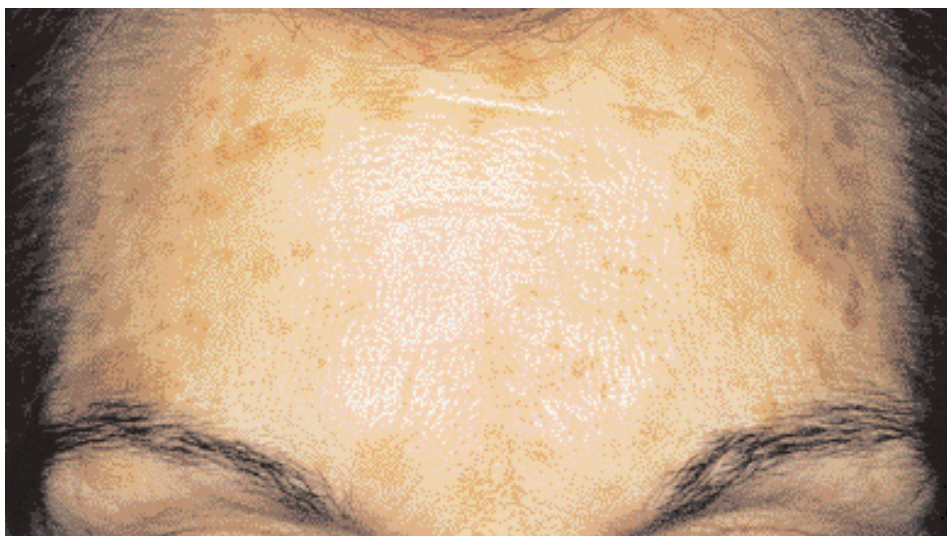
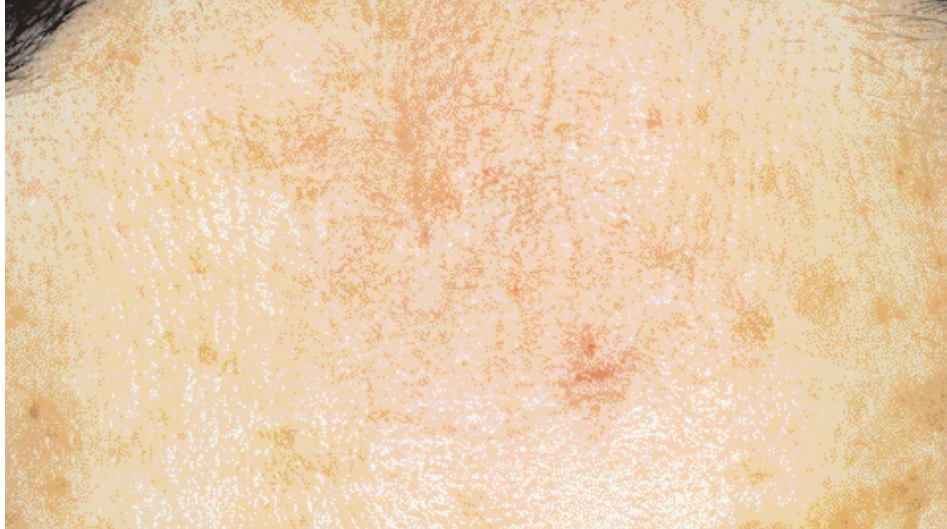

Fig. 26.3.2 Both epidermal and dermal-epidermal lentigines are present. The most conspicuous dermal-epidermal lentigo is treated by means of mixed peeling. Programme data for timesurgical de-epithelialisation: **coagulation with microelectrodes, 1 Watt, EM 10 Yellow** electro-manipule, bent at an angle. Local anaesthesia. After de-epithelialisation, a saturated resorcin solution is applied for 20 seconds. The epidermal lentigines must be treated by means of superficial timesurgical coagulation.

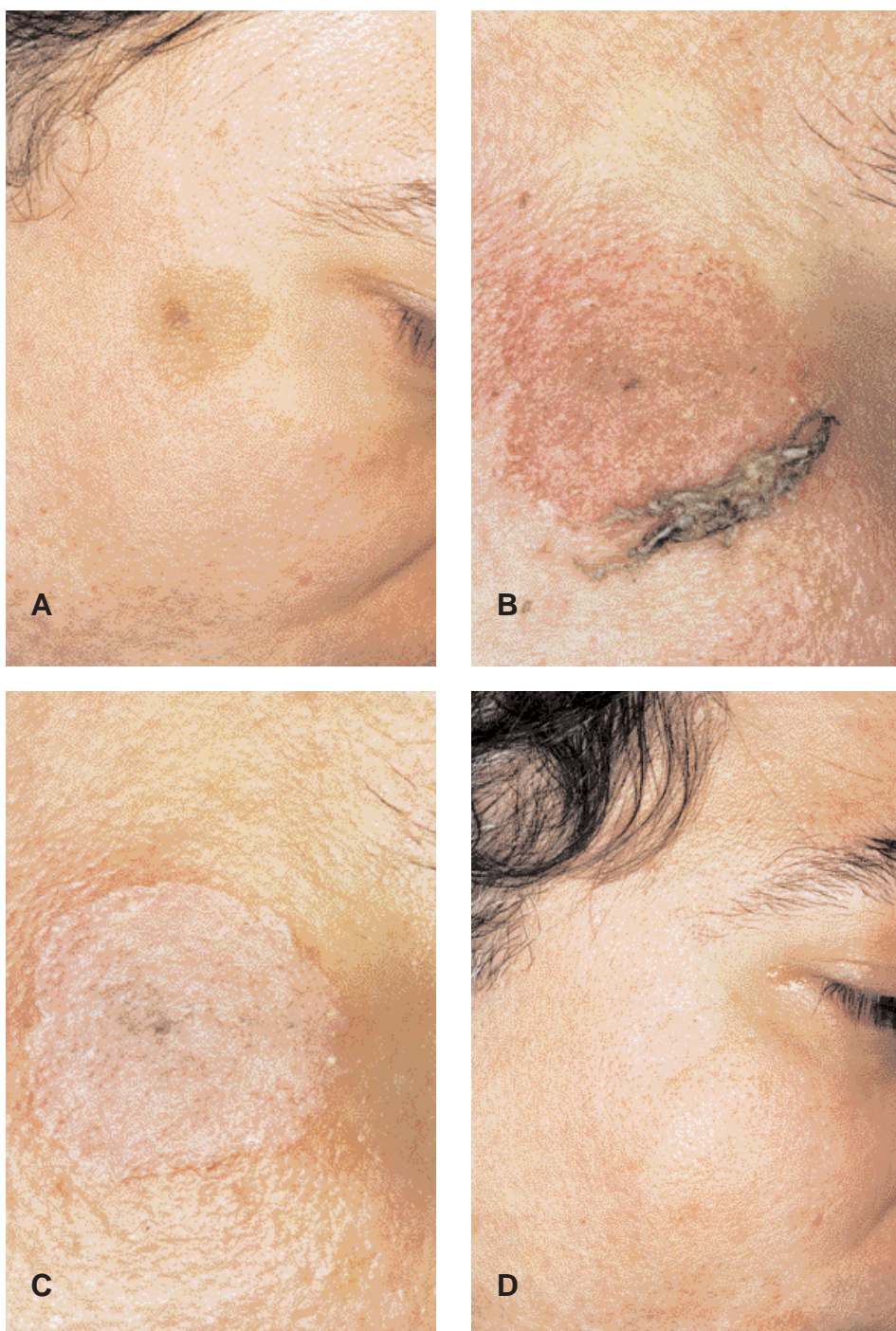

Fig. 26.3.3 Mixed peeling. **A)** Dermal-epidermal hyperpigmentation. **B)** Timesurgical de-epithelialisation. Programme data: **coagulation with microelectrodes, 1 Watt, EM 10 Yellow** electromaniple, bent at an angle. Local anaesthesia. **C)** Resorcin solution is applied for 20 seconds. **D)** Result.

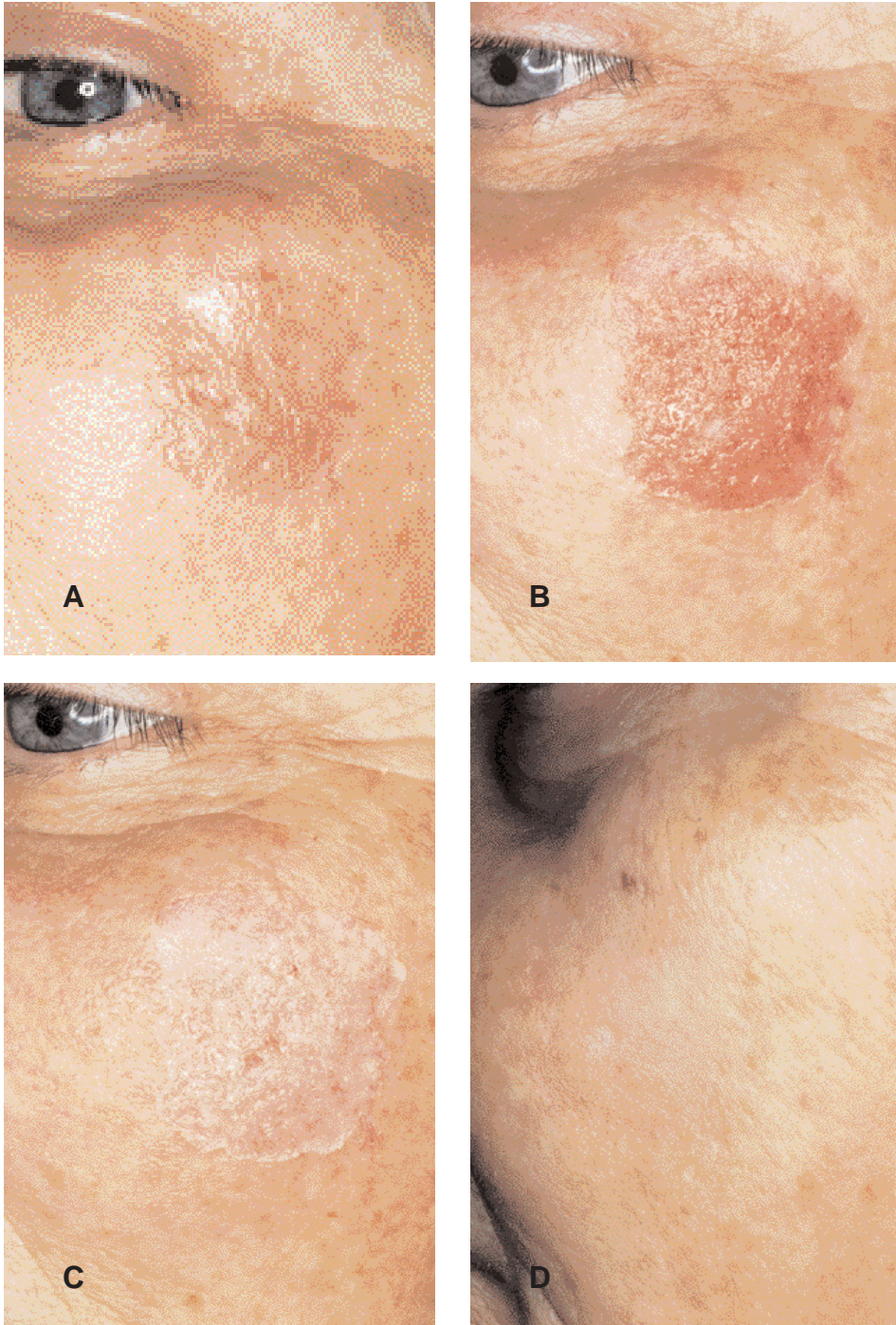


Fig. 26.3.4 Mixed peeling. **A)** Dermal-epidermal hyperpigmentation. **B)** Timedsurgical de-epithelialisation. Programme data: **coagulation with microelectrodes, 1 Watt, EM 10 Yellow** electromanipule, bent at an angle. Local anaesthesia. After de-epithelialisation, the dermis surface appears pathological. **C)** Resorcin solution is applied for 20 seconds. **D)** Result after five months. In addition to eliminating the pigmentation, mixed peeling has normalised the skin surface.

after two or three days on the body. This rapid crust formation minimises the risk of infection.

On the face, the crust falls after about 8 to 10 days, and on the body 15 to 20 days. The de-pigmented area remains pink or dark for a few months and must be protected from UV radiation with anti-sun cream. The results are consistently good.

Mixed peeling (**Fig. 26.3.5**) can also be used to treat reticulated seborrhoeic keratoses, which evolve from solar lentigines (**Fig. 26.3.6**), if they are flat and extensive.

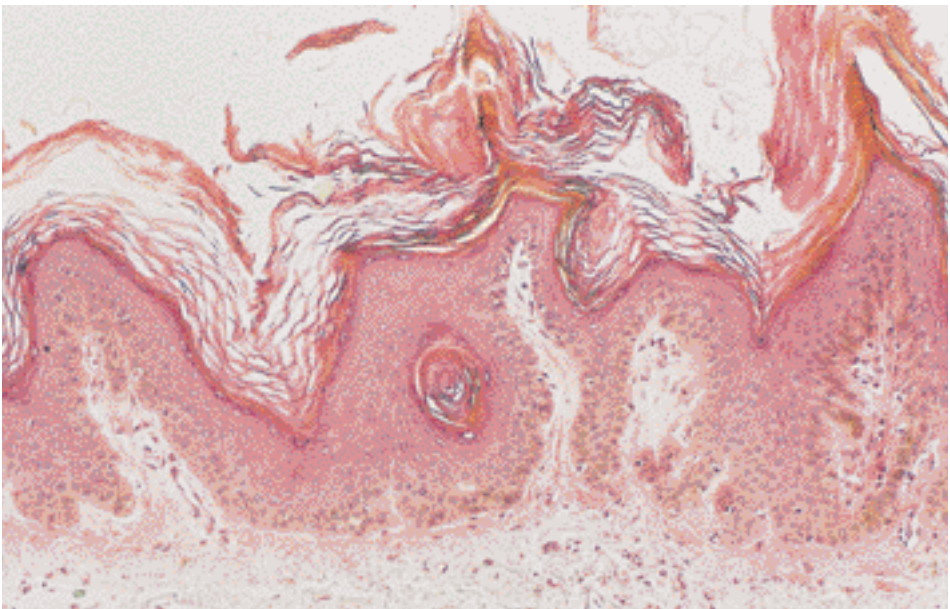


Fig. 26.3.5 Reticulated seborrhoeic keratosis.

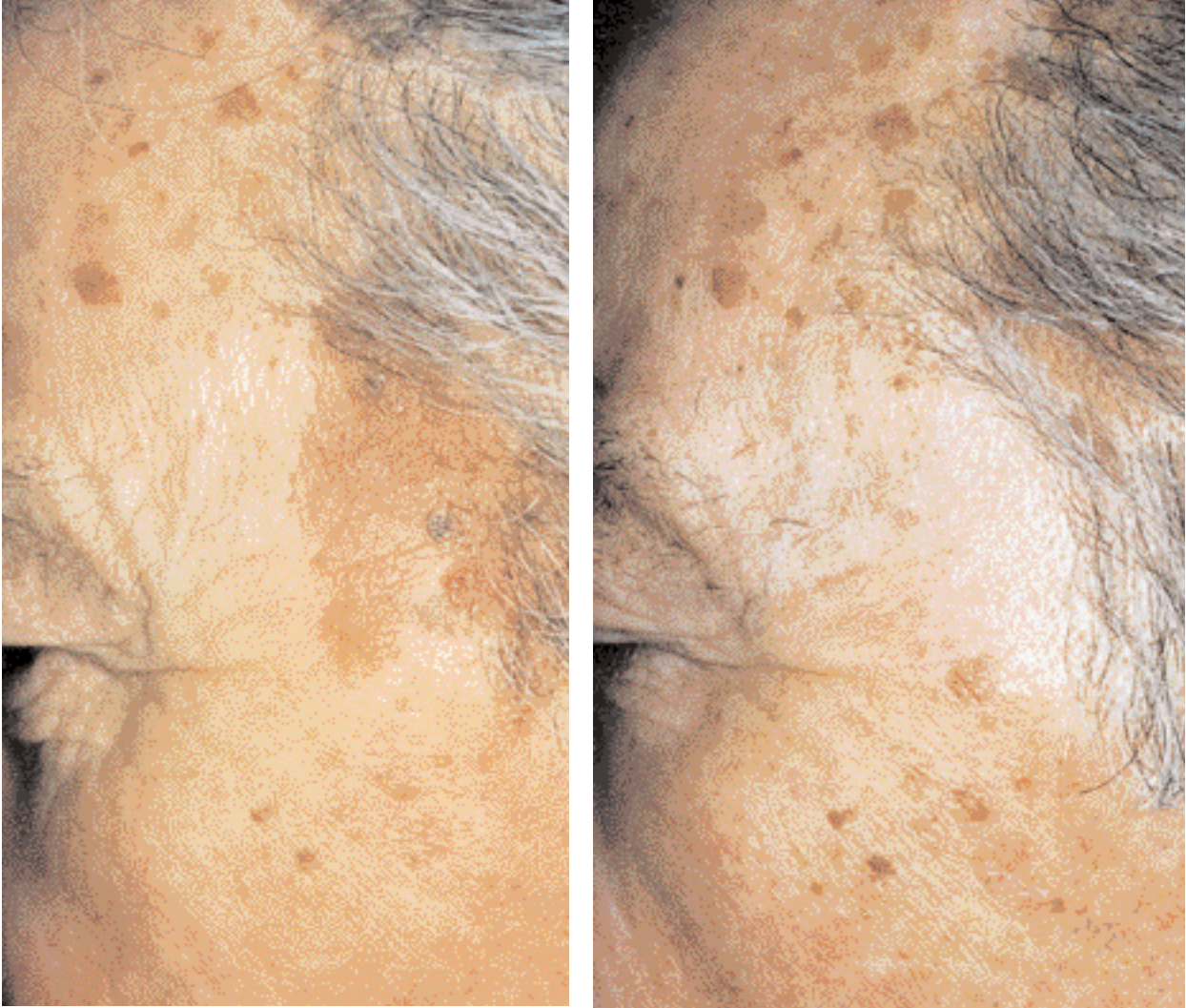


Fig. 26.3.6 Reticulated seborrheic keratoses, which evolve from solar lentigines, can be eliminated by means of mixed peeling if they are flat and extensive. Programme data: **coagulation with microelectrodes, 1 Watt, EM 10 Yellow** electromaniple, bent at an angle. Timedsurgical de-epithelialisation is performed without removing the hair. Saturated resorcin solution is applied for 30 seconds. Local anaesthesia.

Timedsurgical mixed peeling is able to treat other pigmented neofor-mations, even when extensive, such as inflammatory linear verrucous epidermal naevi (ILVEN) (**Fig. 26.3.7**). The procedure normally has to be repeated after 6 months.

After de-epithelialisation, the saturated resorcin solution is applied for 40-60 seconds. If the residual pigmentation is not too conspicuous the dwell time of the resorcin solution can be reduced during the second session. The results are excellent (**Fig. 26.3.8**).

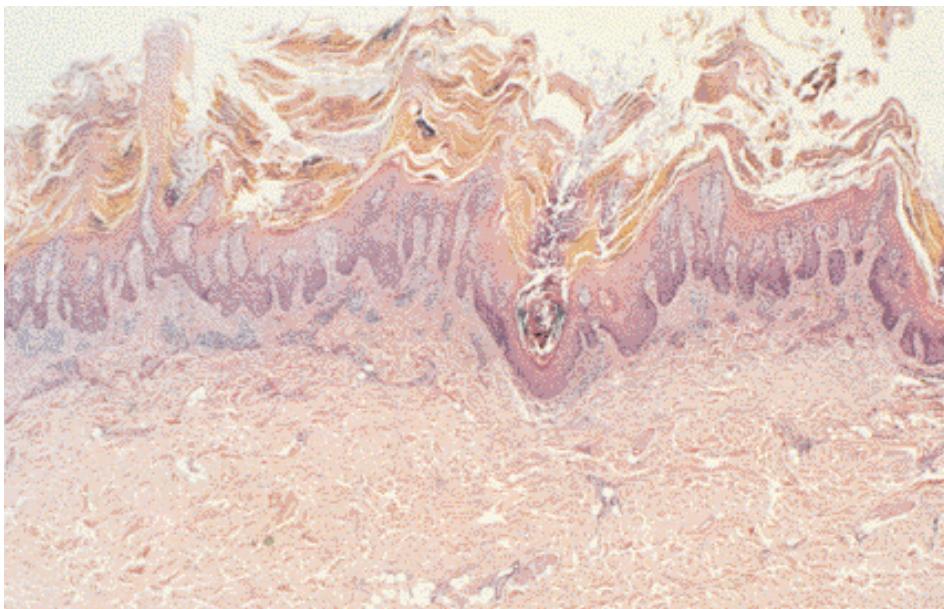


Fig. 26.3.7 Inflammatory linear verrucous epidermal naevus (ILVEN).

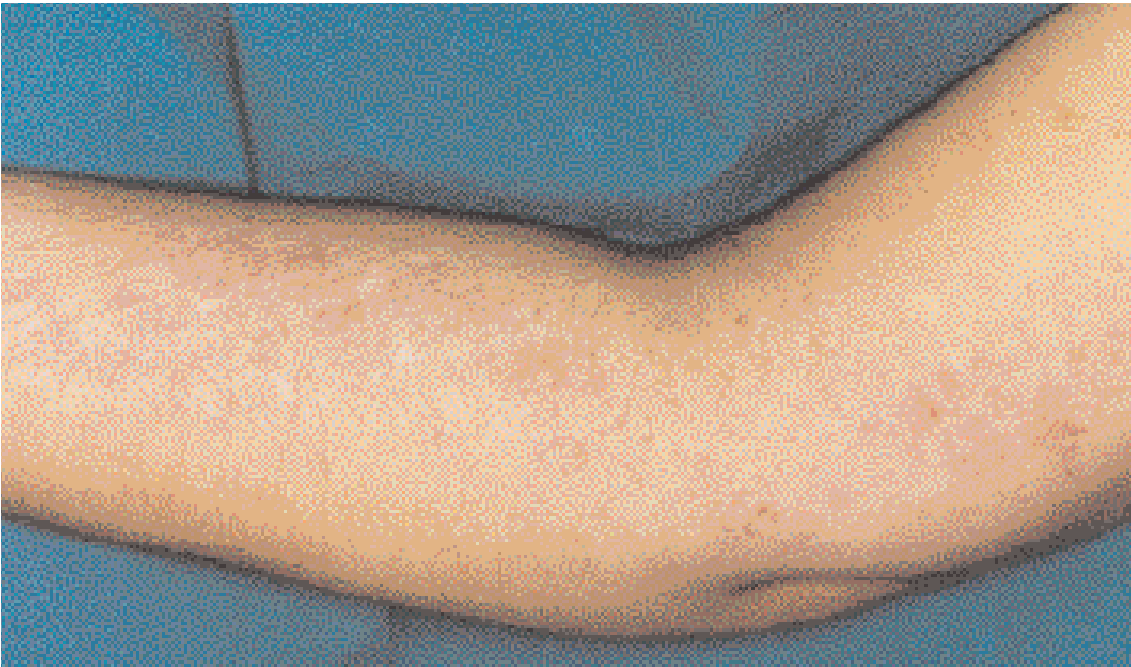
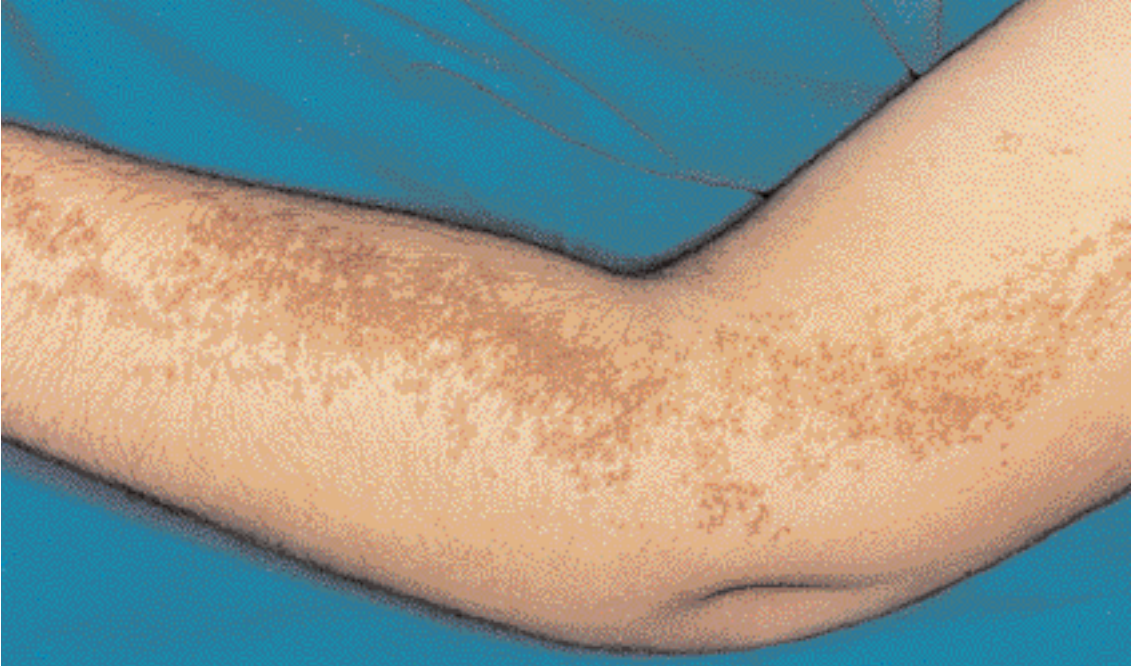


Fig. 26.3.8 Inflammatory linear verrucous epidermal naevus (ILVEN). After testing, mixed peeling is carried out. Programme data of timed surgical de-epithelialisation: **coagulation with microelectrodes, 1 Watt, EM 10 Yellow** electromaniple, bent at an angle. Local anaesthesia. Resorcin solution is subsequently applied for 1 minute. Any residual pigmentation is retreated with mixed peeling. The same result can be achieved by means of the recent timed surgical resurfacing technique in the cutting function, using a power of 50 Watts and the EM 15 electromaniple.

Timed surgical mixed peeling can be used to treat both deep and superficial congenital giant naevi (**Fig. 26.3.9**).

When the location of the giant naevus hinders excision and plastic reconstruction, mixed peeling offers a valid alternative on account of its consistently good results (**Fig. 26.3.10**).

The operation must be carried out in the first two weeks of life and repeated once or twice at yearly intervals.

Mixed peeling is able to eliminate superficial congenital giant naevi.

Deep congenital giant naevi, however, which often infiltrate the subcutaneous tissue and muscle, cannot be removed completely.

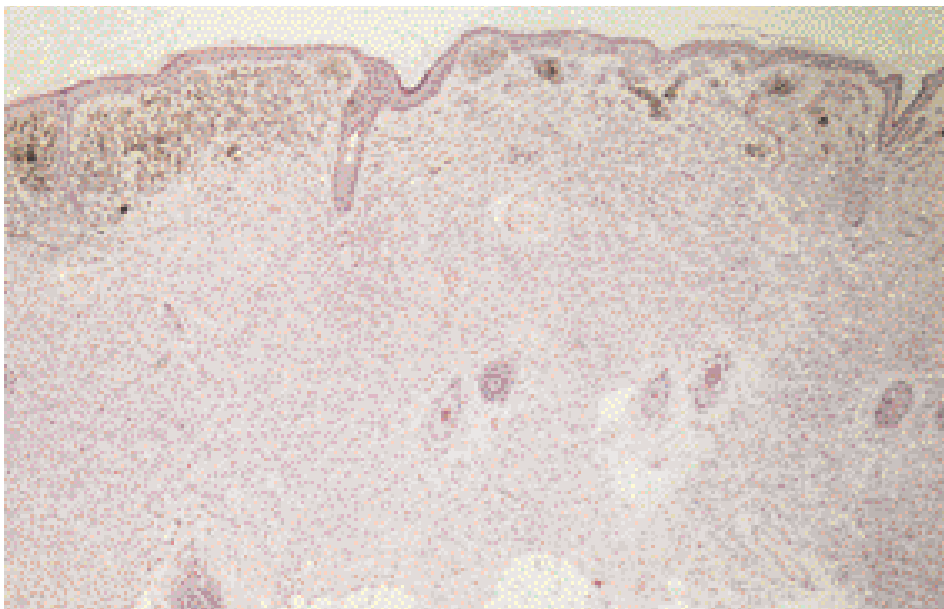


Fig. 26.3.9 Deep congenital giant naevus.

In this case, mixed peeling offers the advantage of rendering the neoformation flat right from the first session, which enables any nodules that might arise later to be detected immediately.

Subsequent sessions create a layer of fibrous tissue which prevents repigmentation of the treated area. The procedure is carried out under general anaesthesia.

Once the surface of the congenital giant naevus has been de-epithelialised, a saturated resorcin solution is applied for about 1 minute; the solution is dabbed onto more prominent areas several times.

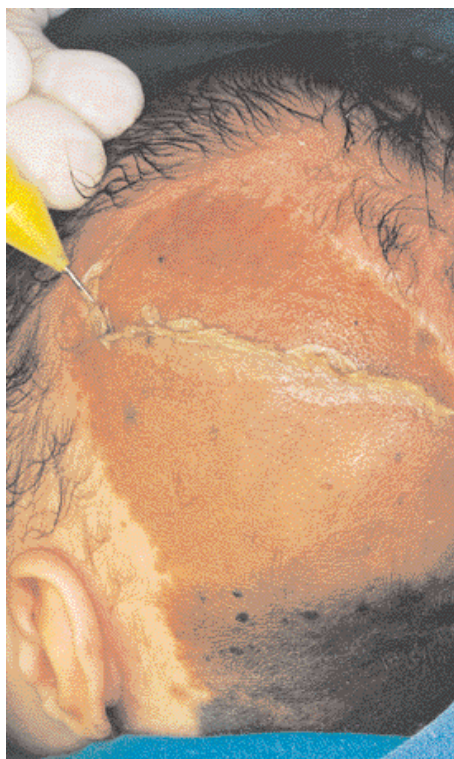
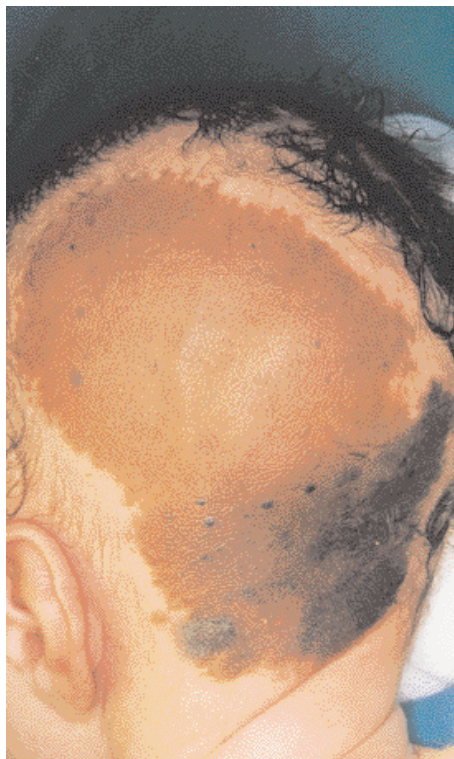
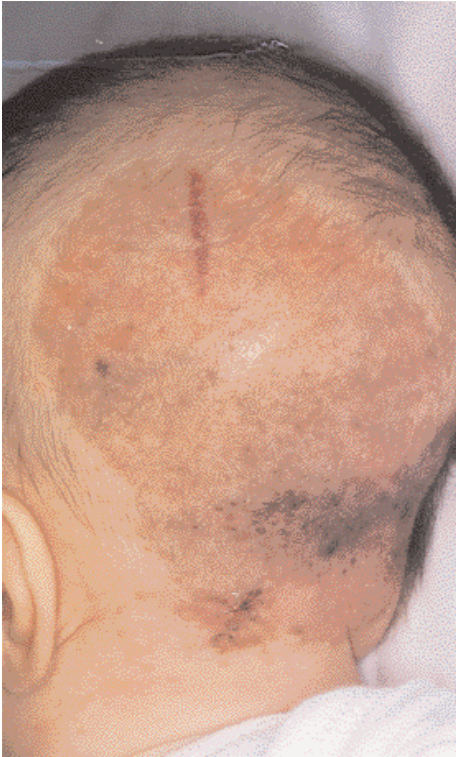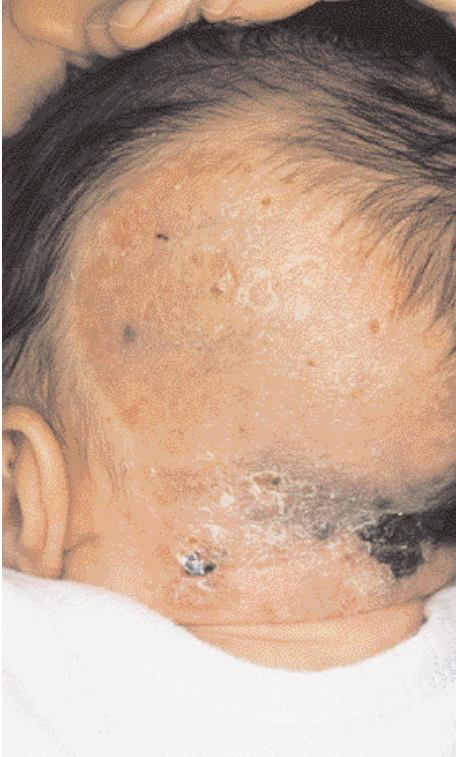Fig. 26.3.10 Mixed peeling of a deep congenital giant naevus. The operation was performed 12 days after birth. Timesurgical de-epithelialisation. Programme data: **coagulation with microelectrodes, 1 Watt, EM 10 Yellow**, bent at an angle. General anaesthesia. Application of saturated resorcin solution for 50 seconds.

(see below)

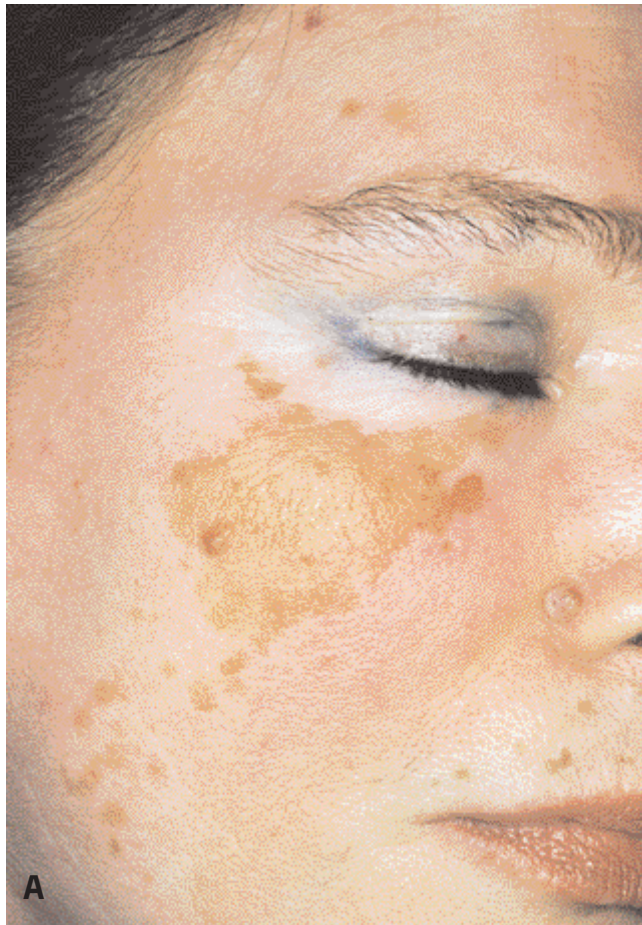

Result after the first session of mixed peeling.

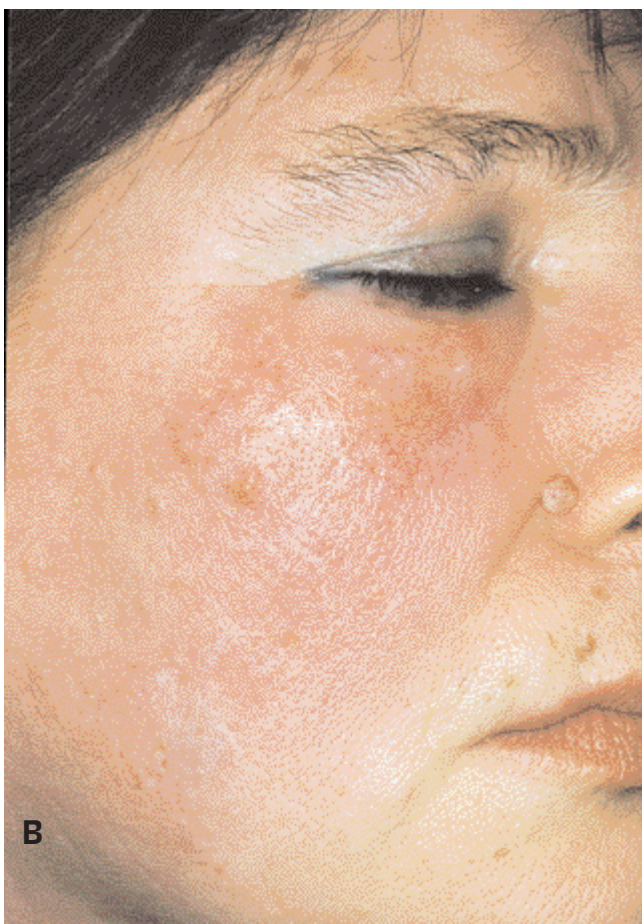26.4 Depigmentation of normochromic skin

Timedsurgical mixed peeling enables normochromic skin to be depigmented (**Fig. 26.4.1**).

The operation is required in cases of generalised or universal vitiligo when one or more areas of pigmented skin, which appear as unsightly patches, are located within an area of achromic skin. Depigmentation requires two sessions, 6 months apart. Once de-epithelialisation at **1 Watt** has been carried out, a saturated resorcin solution is applied for 40-60 seconds. Once the thin eschar has dropped off, the treated area must be protected by anti-sun cream.

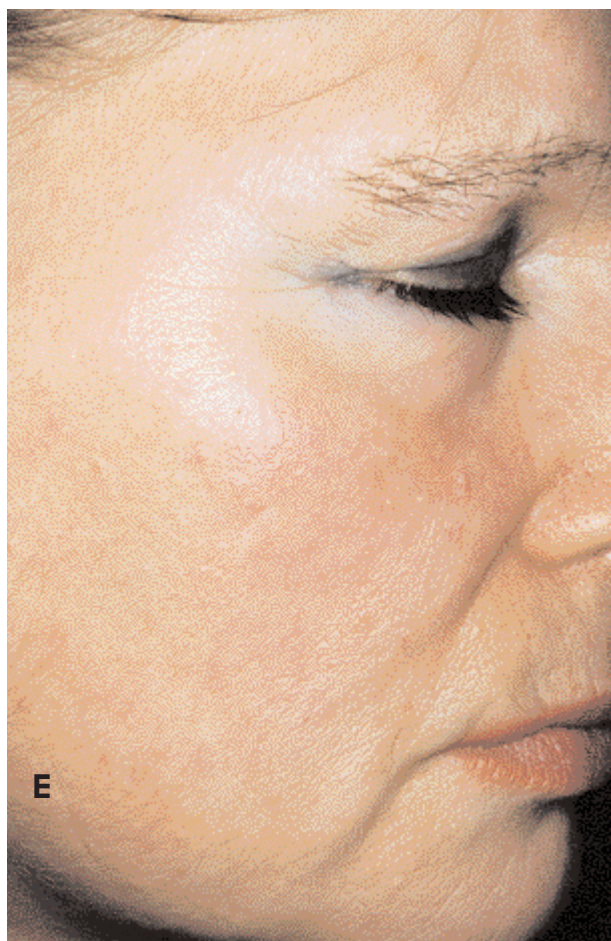
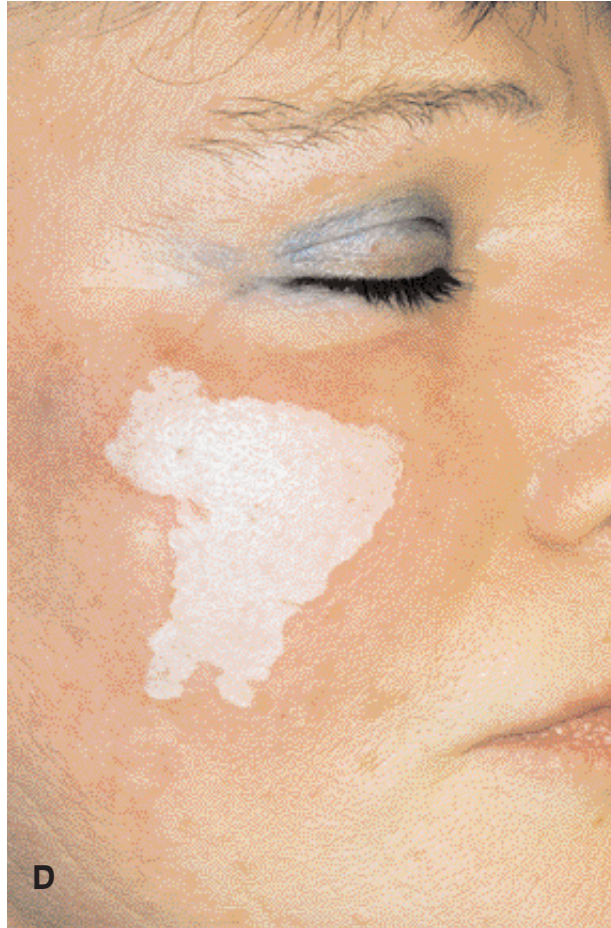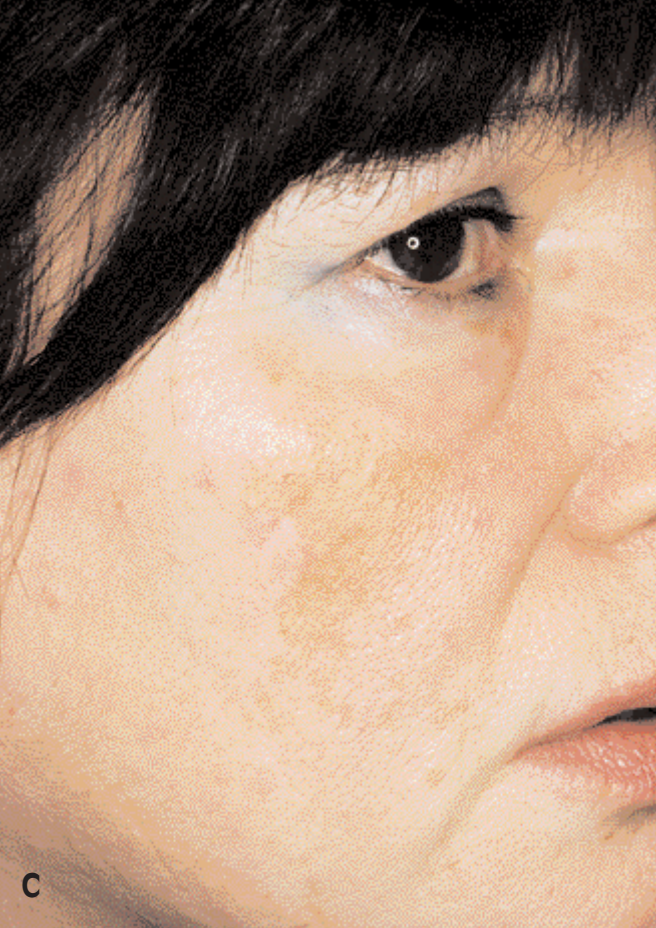


A



B

Fig. 26.4.1 Depigmentation of normochromic skin. **A)** Generalised vitiligo. **B)** Timedsurgical de-epithelialisation and application of a saturated resorcin solution for 45 second. Programme data: **coagulation with microelectrodes, 1 Watt, EM 10 Yellow** electromaniple, bent at an angle. Local anaesthesia. *(see below.)*



C) Result after the first session of mixed peeling. **D)** Immediately after the second session, during which the resorcin solution was applied for 1 minute. **E)** Result.

27

REMOVAL OF TATTOOS

The difficulty in finding a cosmetically acceptable treatment for tattoos is reflected in the existence of numerous techniques for their removal. The problem is not the elimination of the pigment, but the avoidance of visible scars. Many patients avoid treatment for fear, often justified, of a poor aesthetic result. In some small tattoos, surgical removal followed by suturing is feasible, but care has to be taken to avoid unpleasant residual scars, hypertrophic scars or scars which mirror the original design of the tattoo.

Amateur tattoos are carried out manually with various types of needle and the pigment is deposited at an uneven depth in the epidermis, dermis and subcutaneous tissues. The design and its edges are ill-defined and colour varies markedly, according to the concentration and localisation of pigmentation. Amateur tattoo pigments consist of India ink, shoe polish, paint, ink, pencil lead, carbon particles and various other pigments.

Professional tattoos are produced by automatic reciprocating needles (**Fig. 27.0.1**) that are driven to a uniform, regular, and relatively superficial position in the upper dermis. The lines of the design are sharply delineated and nonfading.

Professional tattoos consist of natural chemical compounds chosen for colour variability (brown and yellow

from ochre or sienna, blue from cobalt, green from chromium, red from mercury, violet from cobalt and magnesium, yellow from cadmium).



Fig. 27.0.1 Amateur tattoos are carried out with hand-made needles (top). Professional tattoos are carried out with specially designed automatic machines (bottom).

Traumatic tattoos are produced by penetration of the skin by small foreign particles following explosions or accidents accompanied by abrasion and laceration.

Among the mechanical, chemical and mixed methods of tattoo removal the simplest is timed surgical resurfacing (Capurro 2000), while the most efficacious is electrosalting (Capurro 1988).

Such methods enable any type of tattoo to be removed, and often yield the best aesthetic results possible, depending on the depth of the pigment, control of infection,

reactivity of the patient and limitation of micro-traumas while the treated area heals.

Resurfacing involves from 2 to 7 sittings according to the depth of the pigment; electrosalting 2, 3 or more. The general rules shown in Tab. 27.1 have to be followed.

The patient should be informed that the skin may remain hypochromic, hyperchromic or normochromic; atrophic, hypertrophic or normotrophic.

Tattoo removal is not an aesthetic treatment, but a reconstructive procedure.

Tab. 27.1 General rules for tattoo removal

Break down the tattoo into areas subject to stretching
Do not re-treat an area for at least two months after re-epithelialisation
If electrosalting is performed, the local anaesthetic must contain adrenaline
The patient must abstain from sporting activities until the tattoo has been removed completely

27.1 Timedsurgical resurfacing

Programme data

Direct pulsed 0.3/5.3 hundredths of a second - Coag microelectrodes - 27 or 38 watts - EM 15

Timedsurgical resurfacing is used in areas which are more susceptible to hypertrophic scarring. This procedure enables tattoos to be removed very delicately (**Fig. 27.1.1**). The risk of infection is minimal as a crust forms after a few days, which protects the treated area.

The micro-arc used in resurfacing pulverises the pigments of the tattoo but does not heat the tissues in depth. Healing is rapid. As the skin takes on a similar appearance to that of the surrounding area, there is no need to treat non-pigmented areas in order to mask the tattoo and render the original design unrecognisable.

After shaving the area (with a razor) and administering local anaesthesia, the operator positions the patient return electrode, sets the Timed apparatus to **coagulation with microelectrodes** in the pulsed mode at **0.3/5.3 hundredths of a second**, sets the power to **27 or 38 Watts** and fits an **EM 15** electromaniple. On the first sweep of the electromaniple, the tip is dabbed rapidly onto the skin, which is de-epithelialised.

Fig. 27.1.1 Deep tattoo removed by means of timed surgical resurfacing. Programme data: **coagulation with microelectrodes, pulsed 0.3/5.3 hundredths of a second, 38 Watts, EM 15** electromaniple. Local anaesthesia. Five treatment sessions have been carried out.

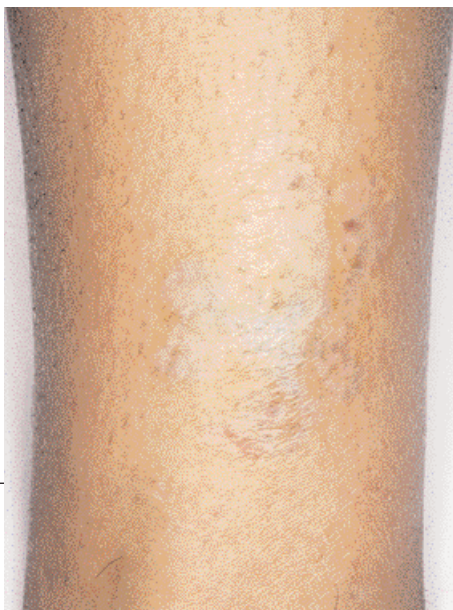
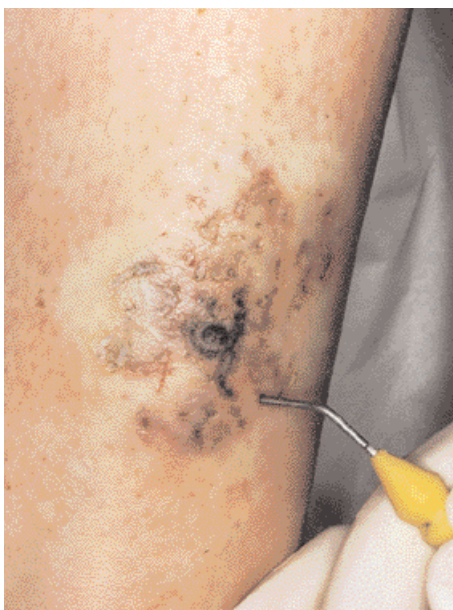
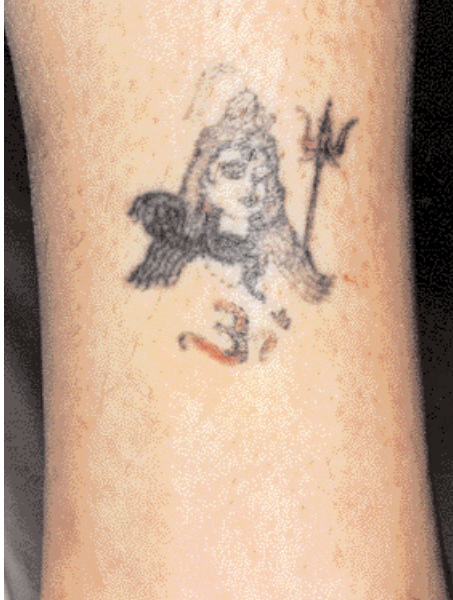

Fig. 27.1.2 Deep tattoo in the deltoid region treated by means of timed surgical resurfacing. As the design is considerably distorted when the patient moves, the treated area must be subdivided into smaller areas. Programme data: **coagulation with microelectrodes, pulsed 0.3-5.3 hundredths of a second, 38 Watts, EM 15** electromaniple. Local anaesthesia. Result after the first session of resurfacing.

Subsequently, the tip of the electro-manipule passes very closely over the pigmented dermis, generating the micro-arc that is a typical feature of timesurgical resurfacing. In the areas where the pigment is most concentrated, several sweeps of the electromanipule will be required. The electromanipule must always be kept moving. During the procedure, the tip of the **EM 15** electromanipule must be cleaned several times with abrasive paper.

In regions that are subject to movement, the procedure has to be carried out in stages (**Fig. 27.1.2**).

On completion of the procedure, the surface of the area is sprinkled with antiseptic powder and covered with a paper tissue held in place by sticking plaster.

The patient will continue to apply the antiseptic powder until the eschar is consolidated. When the eschar detaches, the area must be protected from the sun.

Subsequent operations on the treated area can be performed only after three months.

To date, timesurgical resurfacing is the safest technique for tattoo removal, and enables any type of tattoo, including traumatic tattoos, to be removed (**Fig. 27.1.3-4**).

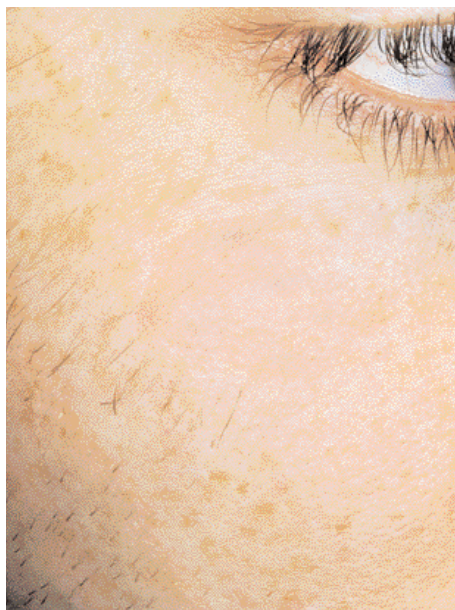
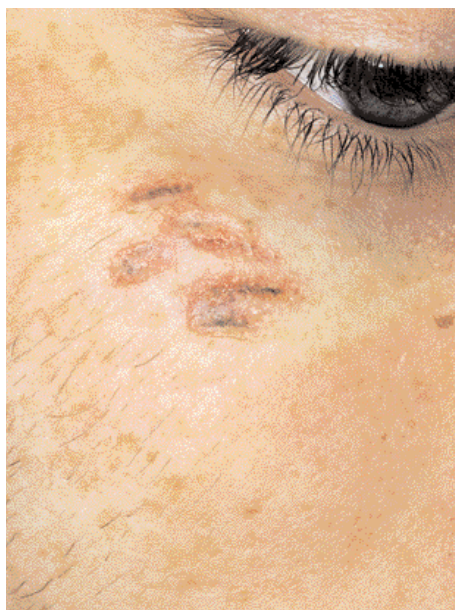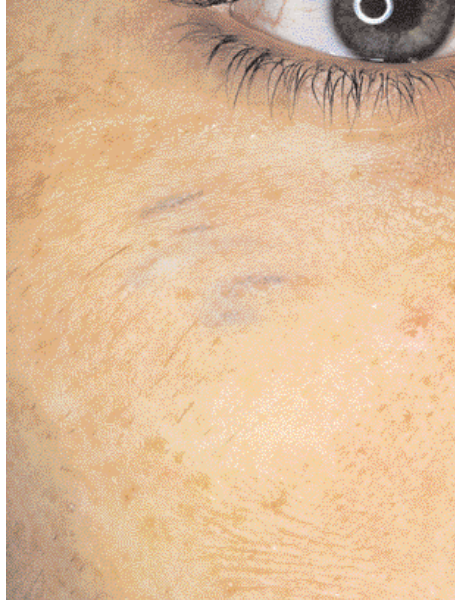


Fig. 27.1.3 Traumatic tattoo removed by means of timesurgical resurfacing. Programme data: **coagulation with microelectrodes, pulsed 0.3/5.3 hundredths of a second, 38 Watts, EM 15** electromanipule. Local anaesthesia. Result after 3 sessions of resurfacing.

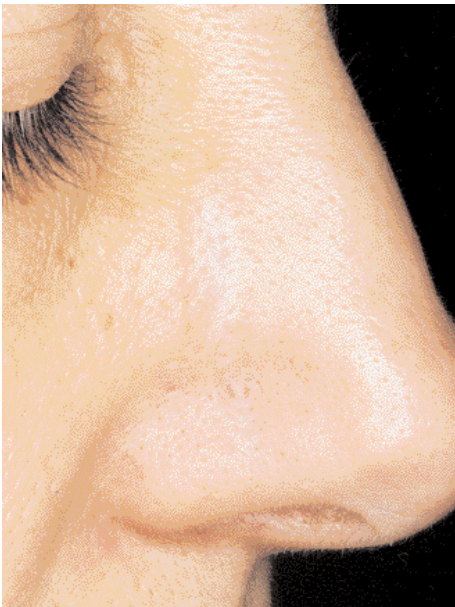
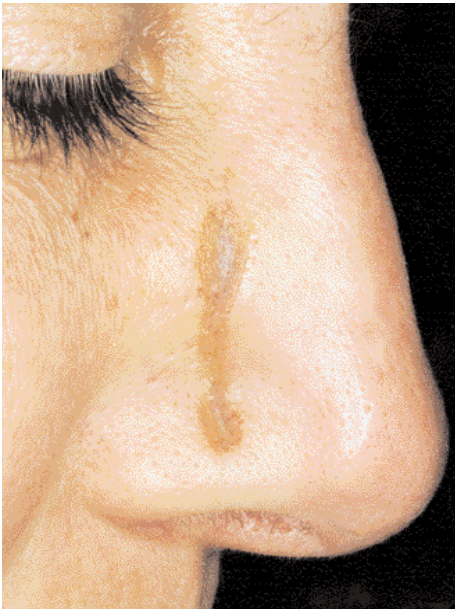
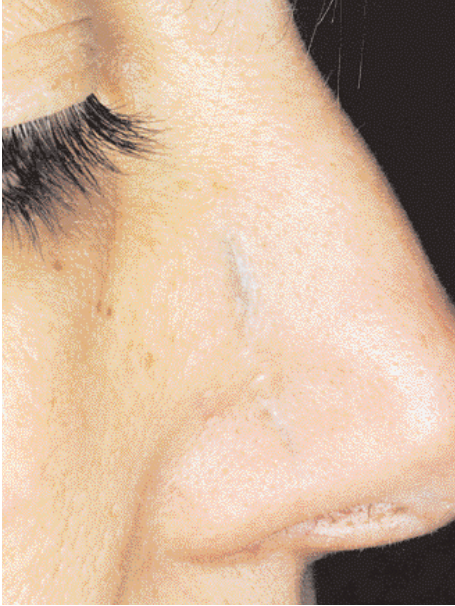Fig. 27.1.4 Traumatic tattoo removed by means of timesurgical resurfacing. Programme data: **coagulation with microelectrodes, pulsed 0.3/5.3 hundredths of a second, 38 Watts, EM 15** electromaniple. Local anaesthesia. Result after 3 sessions of resurfacing.

27.2 Electrosalting

Electrosalting consists of timed surgical de-epithelialisation followed by the application of sodium chloride. De-epithelialisation of the skin serves only to allow penetration of the salt.

Timed surgical de-epithelialisation

Programme data

Large-size tattoos

Direct - Coag microelectrodes - 14 - 20 Watts - EM 15

Programme data

Small and medium-size tattoos

Direct - Coag microelectrodes - 1 Watts - EM 10 Yellow, (bent at an angle)

If the tattoo is of large size, after placing the neutral electrode in contact with the patient's skin and disinfecting the area, the operator sets the Timed apparatus to the **direct** mode, the function to **coagulation with microelectrodes**, the power to **14 or 20 Watts** and fits an **EM 15** electromaniple.

The electromaniple is passed in a rapid circular movement over the tattoo surface a few millimetres beyond the edges of the design.

The action is started by brushing the electromaniple against the tissue.

The operator continues the movement even if the electromaniple collects coagulated epidermis.

When the first session of electrosalting is carried out, the non-pigmented skin is also de-epithelialised to obliterate the outline of the tattoos. Indeed, electrosalting often alters the texture and colour of the skin, and the original design has to be rendered unrecognisable.

For small and medium size tattoos and those situated on the hands or feet, it may be deemed more appropriate to carry out de-epithelialisation with the edge of the tip of an **EM 10 Yellow** electromaniple, at a power of **1 Watt**.

After elimination of the epidermis, the area is salted.

Salting

The operator puts a little fine table salt into a container and adds sterile water to produce a thick liquid (**Fig. 27.2.1**) with which the tattoo is gently massaged, using a gauze, for about one minute, to allow the salt to be absorbed. With small tattoos the salting is carried out with a cotton-wool pad.

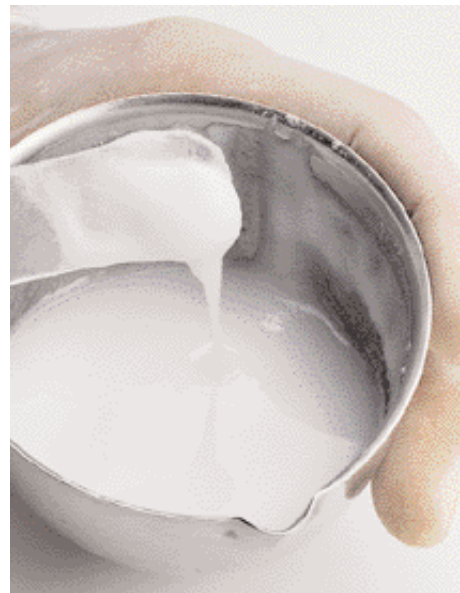

Fig. 27.2.1 Sodium chloride precipitates from the salting solution; during application to extensive tattoos it may therefore be necessary to re-mix the solution.

The more uniform the paste, the more rapid and uniform is the absorption. During electrosalting the application of sodium chloride must not be aggressive or abrasive (**Fig. 27.2.2**); indeed, as a few authors have suggested (Shelly 1984), only the chemical action of the salt is used.

The term "salting" has been introduced to distinguish this technique from the abrasive effect of "salt abrasion".

In this way even large tattoos can be treated. At the end of the procedure the area will appear pink and the tattoo more evident than before treatment, because removal of the epidermis renders the residual pigment of the tattoo more visible (**Fig. 27.2.3-5**).

A gauze is applied to the treated area, without removing the sodium chloride. After a minimum of 15 minutes and a maximum of 1 hour, the patient removes the salt by washing thoroughly with water. The wound is then painted with a dilute povidone-iodine solution and covered with a layer of non-adherent gauze followed by a dressing of sterile pads and gauze wrap.

The dressing is changed daily and the area repainted with the solution until a crust forms. It is very important to avoid infection, as this will hinder healing and jeopardise the results of electrosalting.

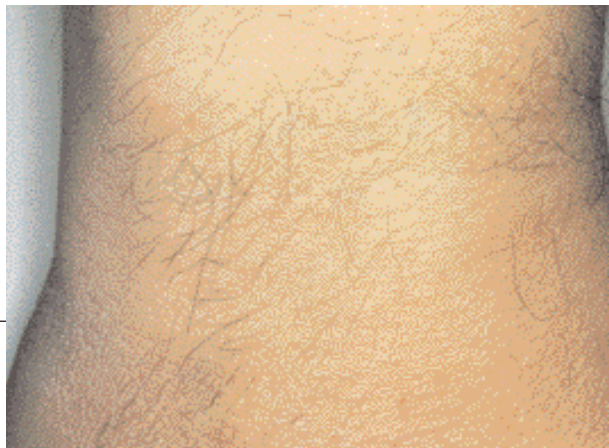
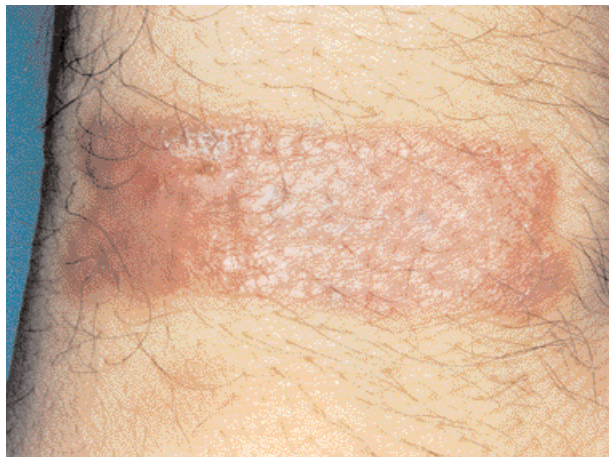
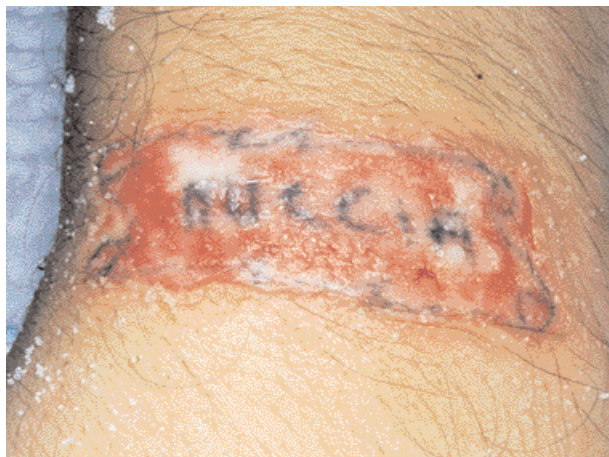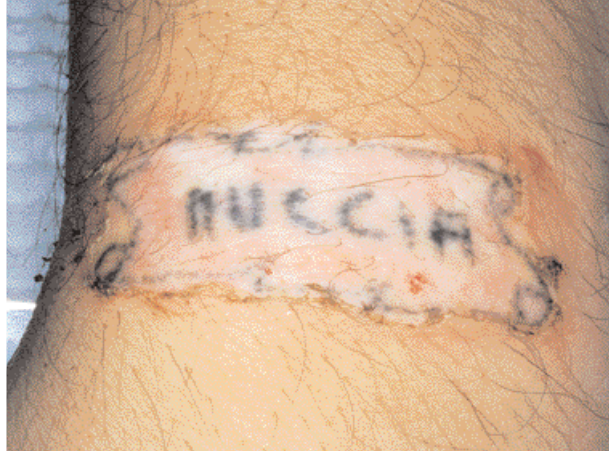Fig. 27.2.2 Electrosalting of a tattoo on the wrist. Timesurgical de-epithelialisation and salting for 1 hour. The tattoo has been masked. Programme data: **coagulation with microelectrodes, 1 Watt, EM 10 Yellow** electromanipule (bent at an angle). Local anaesthesia. When the crust drops off, the skin is red. Result after one session of electrosalting.

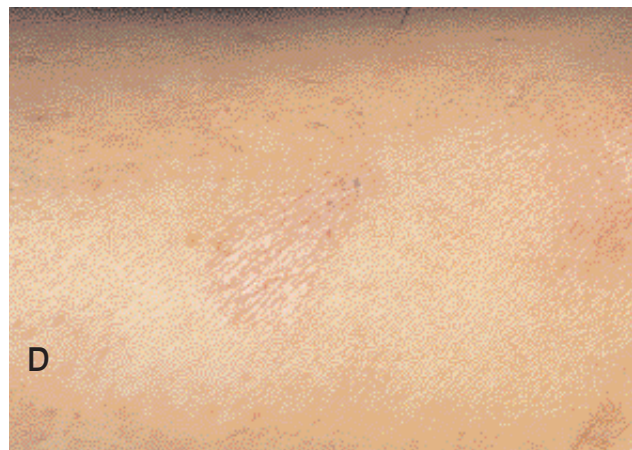
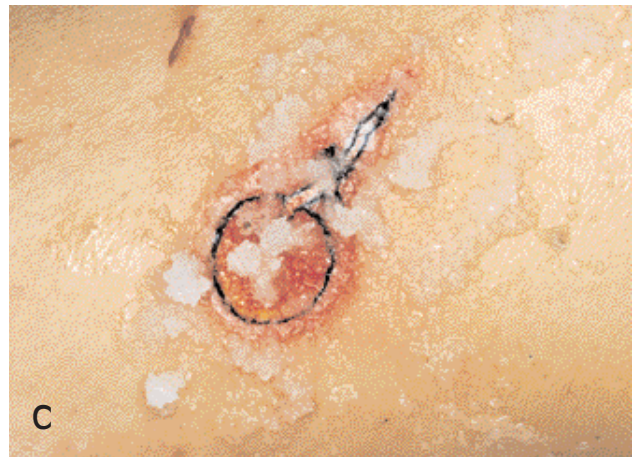
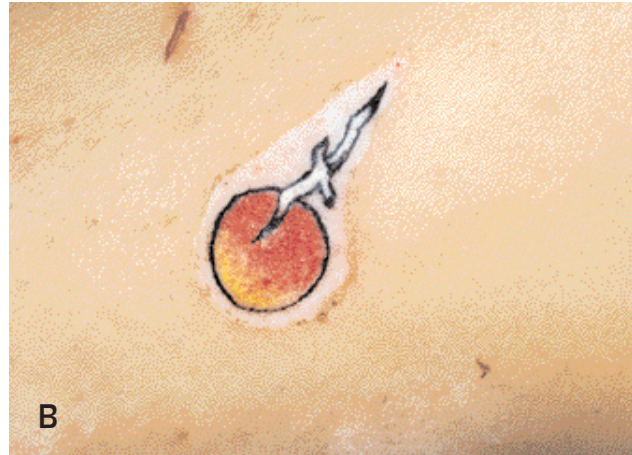
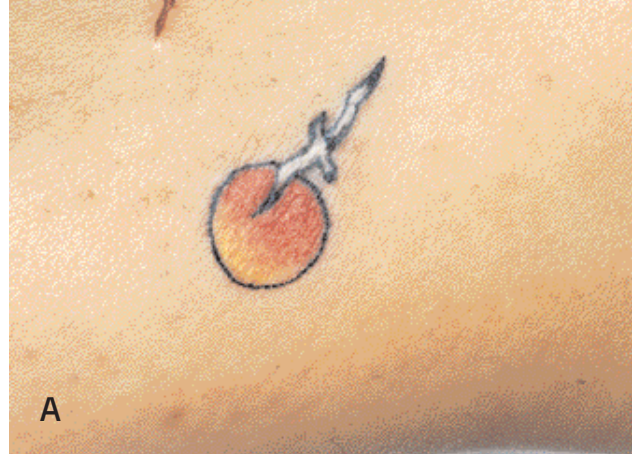Fig. 27.2.3 Electrosalting. **A)** Small tattoo on the ankle. **B)** Timedsurgical de-epithelialisation. Programme data: **coagulation with microelectrodes, 1 Watt, EM 10 Yellow** electromanipule (bent at an angle). Local anaesthesia. **C)** Salting for 30 minutes. **D)** Result after two sessions of electrosalting.

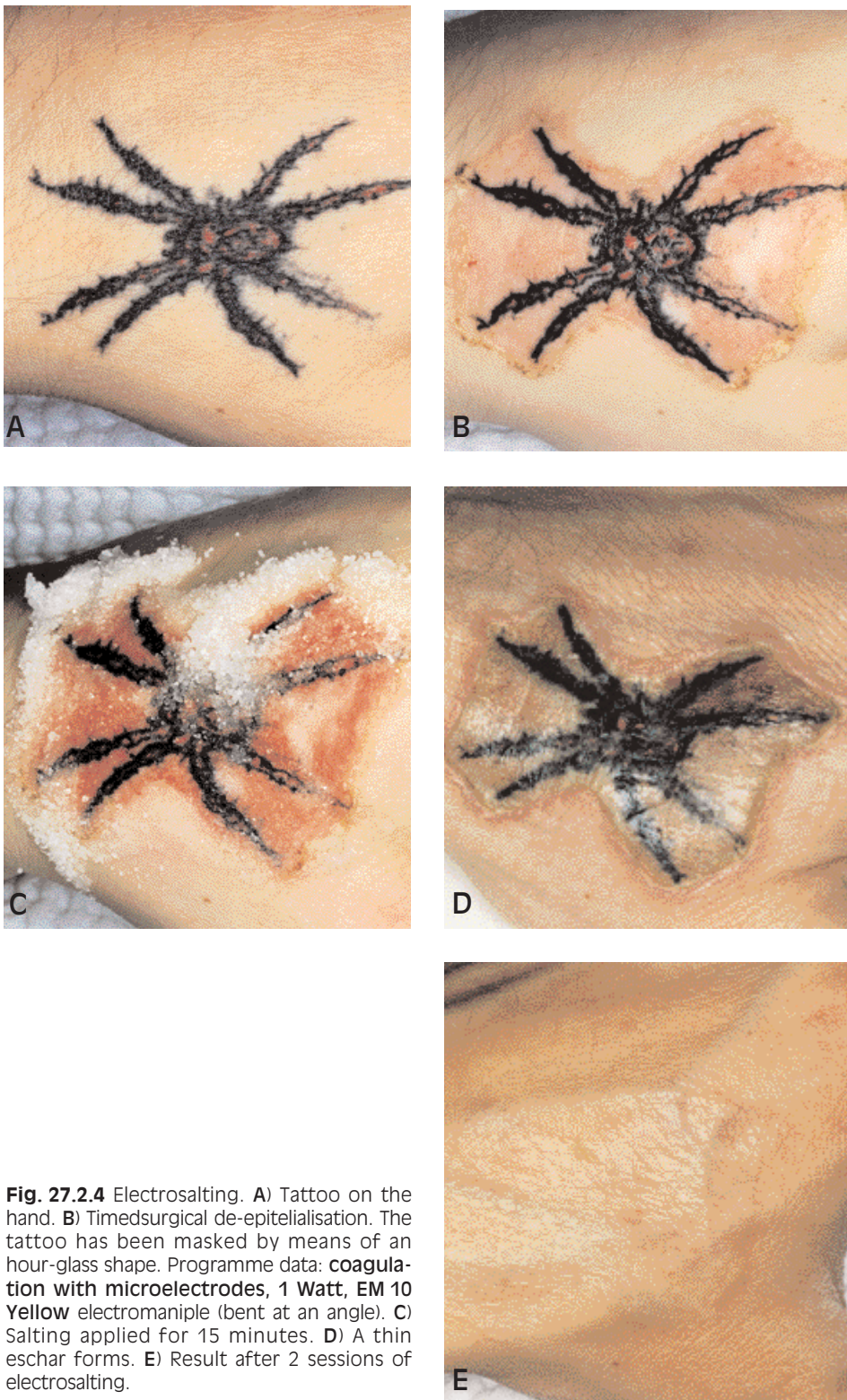

Fig. 27.2.4 Electrosalting. **A)** Tattoo on the hand. **B)** Timedsurgical de-epithelialisation. The tattoo has been masked by means of an hour-glass shape. Programme data: **coagulation with microelectrodes, 1 Watt, EM 10 Yellow** electromaniple (bent at an angle). **C)** Salting applied for 15 minutes. **D)** A thin eschar forms. **E)** Result after 2 sessions of electrosalting.

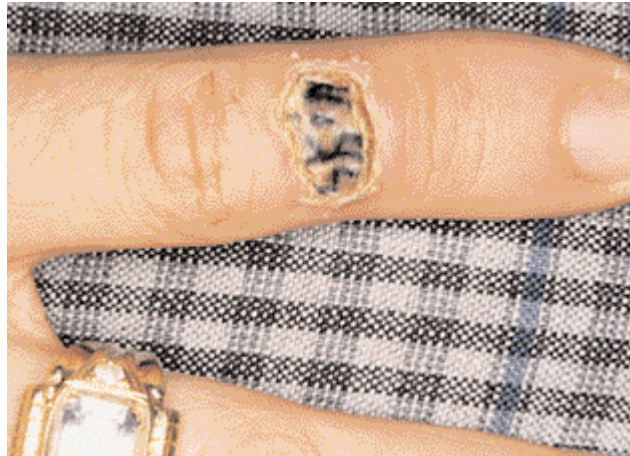
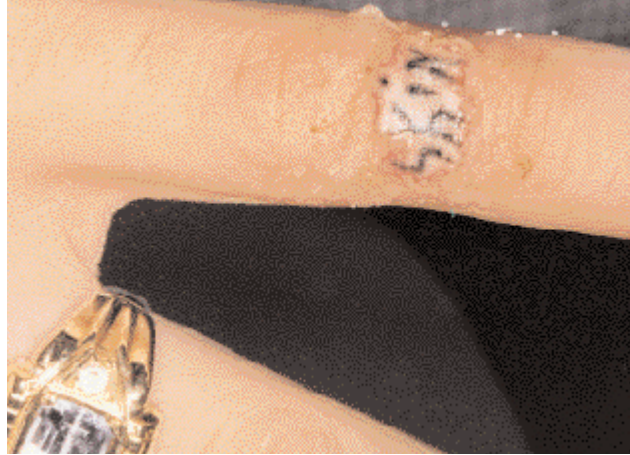
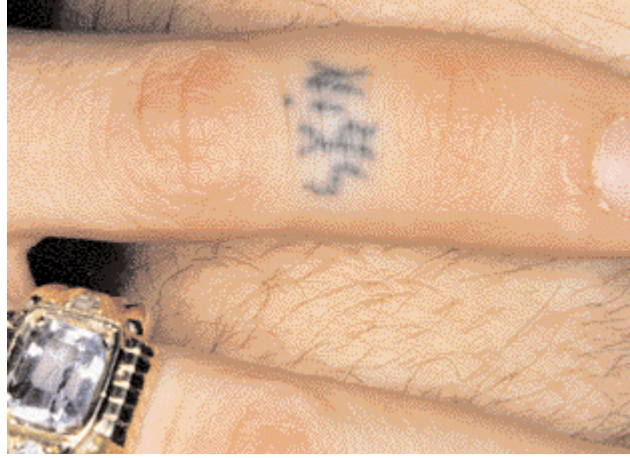Fig. 27.2.5 Electrosalting. Timesurgical de-epithelialisation and salting for 15 minutes. Programme data: **coagulation with micro-electrodes, 1 Watt, EM 10 Yellow** electromaniple (bent at an angle). Local anaesthesia. Result after one session of electrosalting.

Frequent post-operative check-ups will be needed in order to achieve the best possible result.

If the tattoo is large, it is divided into smaller areas and salt is applied to each of these for around one minute, in order to obtain a uniform action.

It is necessary to tell the patient the salt will not have an immediate effect and he must not be surprised if, immediately after the first treatment sessions, the tattoo appears more evident than before treatment. The eschar takes up the pigment and spontaneous detachment of the eschar, which may be encouraged by the application of an ointment such as soft white paraffin, occurs after 4 or 5 weeks, when re-epithelialisation is complete.

Salt is maintained in contact with the wound for longer in areas in which the skin is thick, such as the back, or in highly vascularised areas. The salting causes superficial necrosis, pigment wash-out by osmosis and a phagocyte reaction, which eliminates 60% to 90% of the tattoo in the first sitting.

Professional tattoos, which have a more superficial and uniform distribution of pigment, are eliminated in fewer sittings than amateur tattoos. After the first sitting, pigment normally remains at the points where it was introduced more deeply, or in greater quantities.

Subsequent sittings are carried out after three months to treat any residual pigment.

Subsequent treatment sessions are carried out in the same way as the initial session, though treatment of the intact skin to obliterate the outline is no longer performed.

The majority of tattoos are elimina-

ted in two or three sittings. In rare cases, up to five may be required. This almost always involves amateur tattoos in which pigmentation is very deep or in which an original tattoo has been subsequently modified.

Electrosalting produces good results even when only a small part of the tattoo is to be modified. (**Fig. 27.2.6**).

Electrosalting is also used to remove tattoos from the eyebrows (**Fig. 27.2.7**).

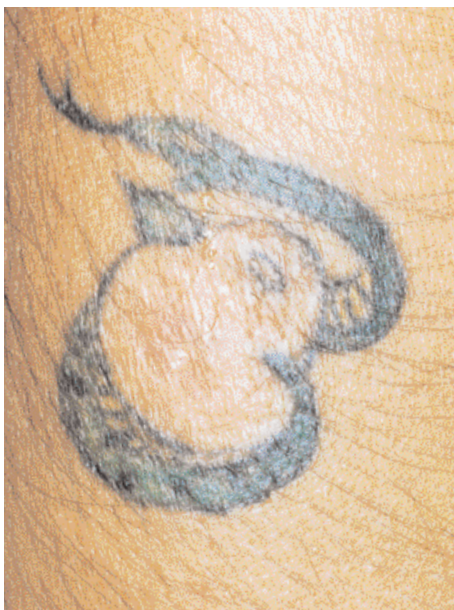
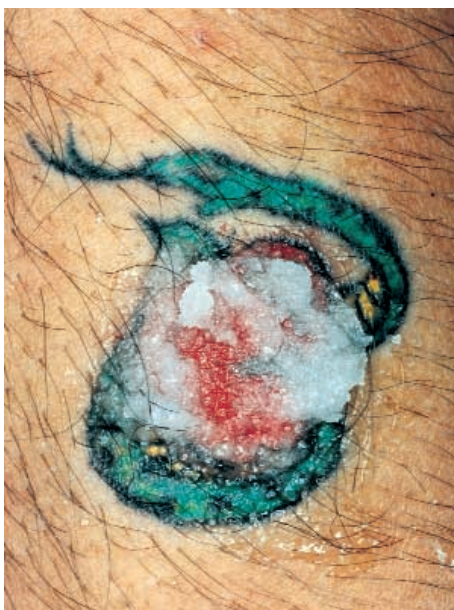
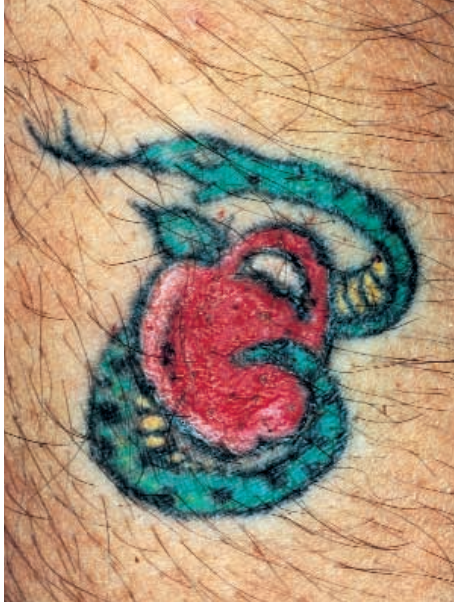Fig. 27.2.6 Electrosalting. Removal of a detail of a tattoo. Timesurgical de-epithelialisation. Programme data: **coagulation with microelectrodes, 1 Watt, EM 10 Yellow** electromanipule (bent at an angle). Local anaesthesia. Salting for 40 minutes. Result after one session of electrosalting.

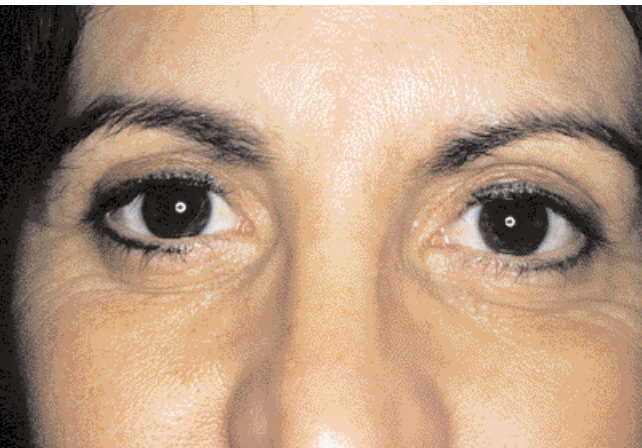
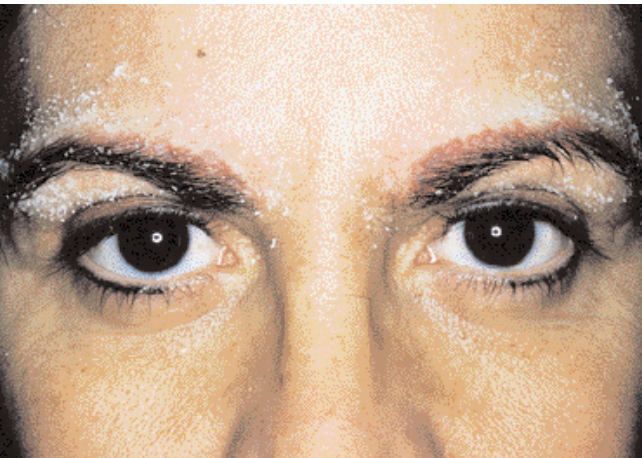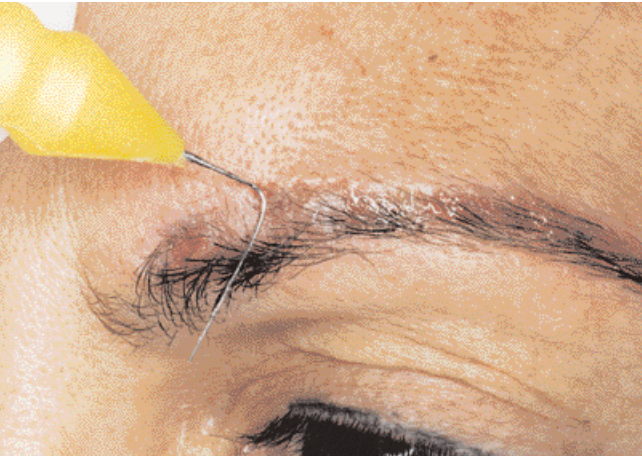

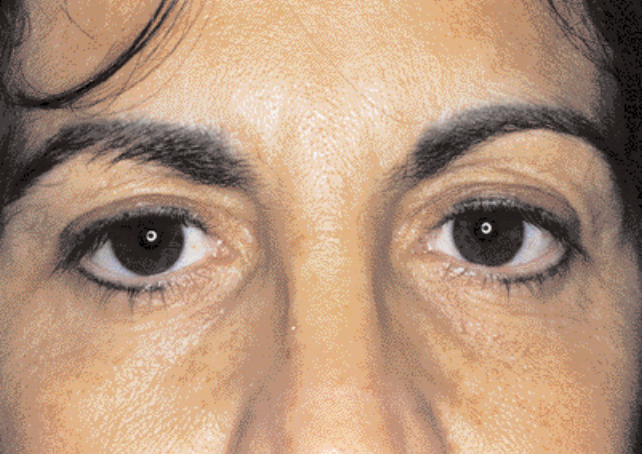
Fig. 27.2.7 Electrosalting. Removal of a tattoo from the eyebrow. Timedsurgical de-epithelialisation and salting for 30 minutes. Programme data: **coagulation with microelectrodes, 1 Watt, EM 10 Yellow** electromaniple (bent at an angle). Local anaesthesia. De-epithelialisation is carried out while keeping the eyebrow intact. Two sessions of electrosalting have been performed.

28

ELIMINATION OF WRINKLES

Facial wrinkles are eliminated by means of mixed peeling.

28.1 Mixed peeling

Programme data

Direct - Coag microelectrodes -

1 Watt - EM 10 Yellow (bent at an angle)

Timedsurgical de-epithelialisation of the skin at 1 Watt (see section 24.1), followed by the application of resorcin solution, eliminates wrinkles (Capurro 1993). Mixed peeling with resorcin is as effective as that using phenol, without the associated risks. When applied to a de-epithelialised area resorcin has a safe and constant action, as the epidermis has been removed.

The results are excellent and remain stable for years (**Fig. 28.1.1-2**).

In addition to the elimination of the wrinkles, the re-organisation of the dermal structure is evident (**Fig. 28.1.3**).

The technique is used mainly to remove wrinkles of the lip (**Fig. 28.1.4-8**) and eyelid, but it may also be applied to other regions of the face.

Sometimes, these areas are treated with timedsurgical resurfacing.

To eliminate wrinkles of the upper lip, the whole of the lip is de-epithelialised, up to about 5 mm beyond

the nasolabial folds. The saturated solution is prepared by placing a small amount of resorcin powder in a sterile container and dissolving it in a few drops of sterile water. The solution is applied to the dermis using a cotton wad, starting with the area where the wrinkles are deepest and with the areas nearest to the vermilion border, in which the hair follicles are most densely concentrated. Afterwards, the solution is rapidly applied to the remaining area.

Whitening occurs immediately. Application time, from 60 to 120 seconds, depends on the depth of the wrinkles. The area is then washed with physiological saline solution. After a few hours a crust forms, which thickens in the following days and detaches in 8 to 12 days. No medication or anti-herpes prevention is required.

The treated area is pink and must not be exposed to the sun. In order to accelerate keratinisation, it is better not to apply cream until at least one week after complete re-epithelialisation.

The patient must be informed that the new skin will be different in colour and texture. The patient must be prepared to accept a slight hypopigmentation in exchange for a skin which seems younger and smoother.

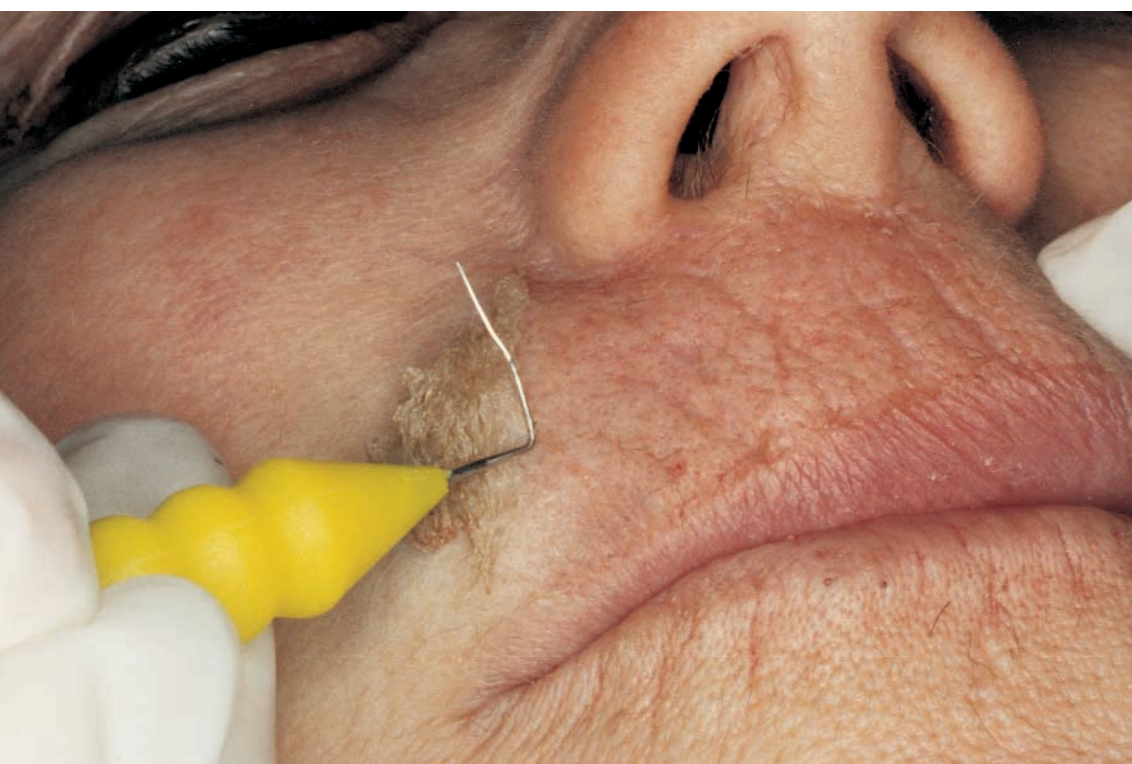
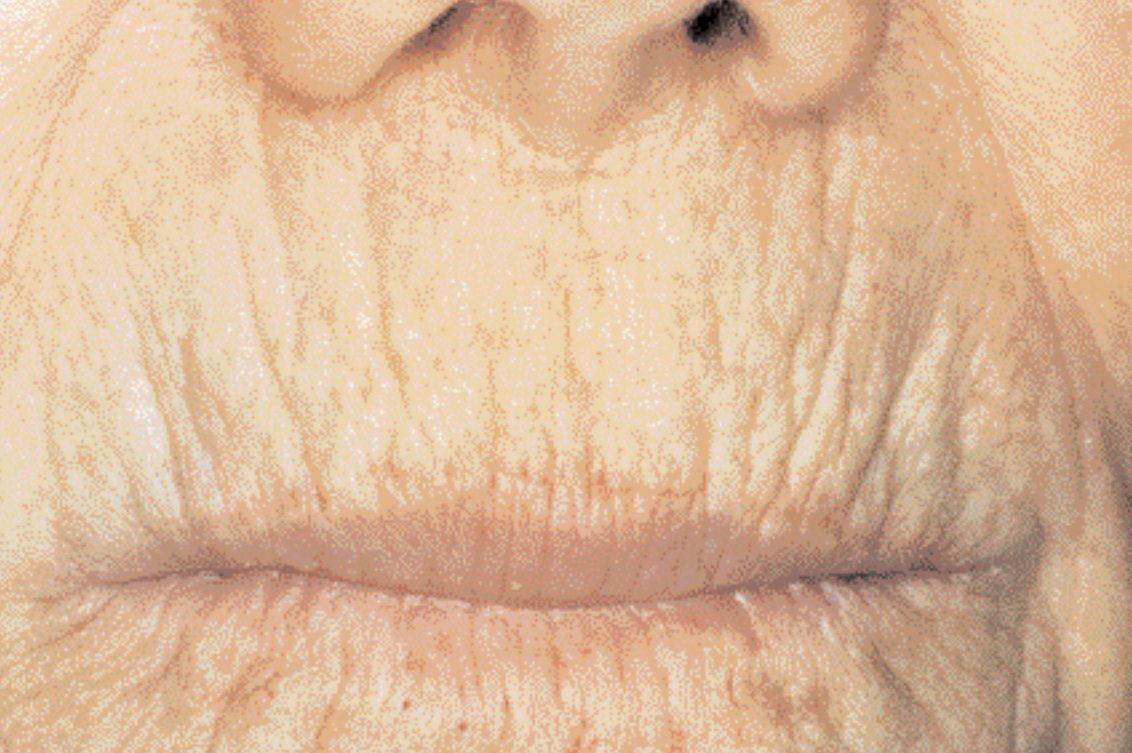


Fig. 28.1.1 Mixed peeling. Timedsurgical de-epithelialisation. Programme data: **coagulation with microelectrodes, 1 Watt, EM 10 Yellow** electromaniple, bent at an angle. Regional anaesthesia.

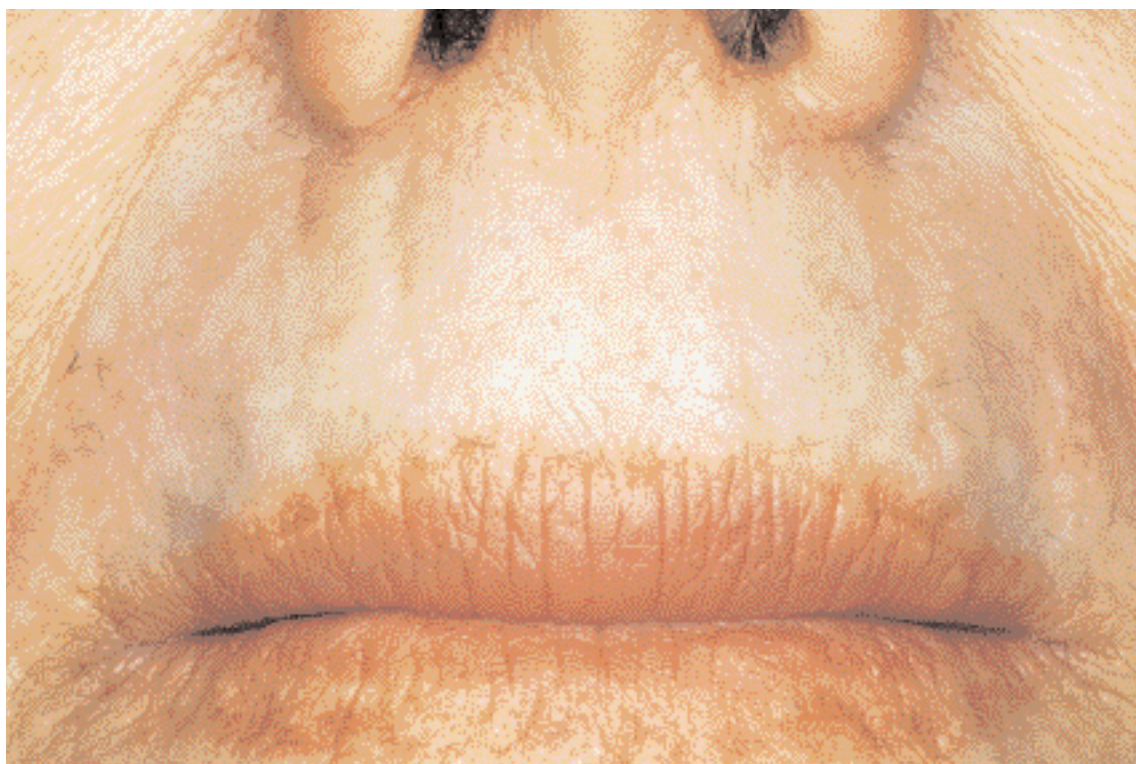
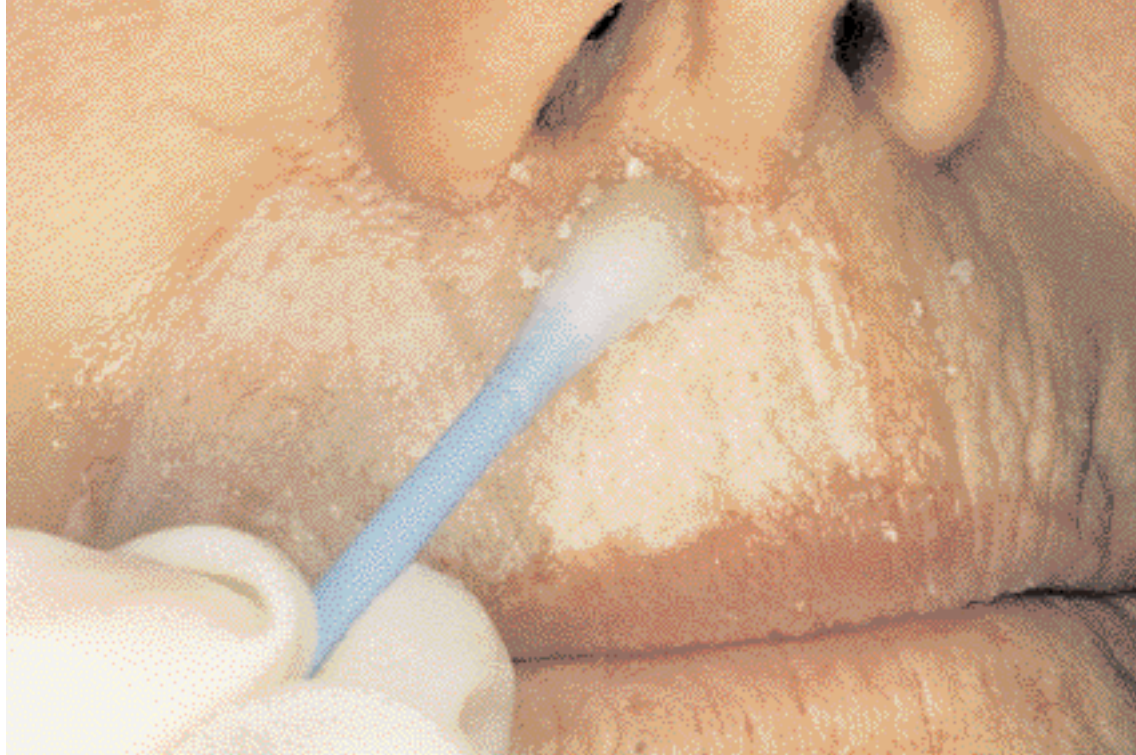
Fig. 28.1.2 Application of saturated resorcin solution, which is washed off after 120 seconds. The result is stable after seven years.

The shorter the application time of resorcin and the richer the area of application is in hair follicles (which contain a reserve of melanocytes), the more rapid re-pigmentation is and the more similar the colour will be to the surrounding skin.

If some wrinkles remain after mixed pelling (**Fig. 28.1.9**), they can be re-treated singly after six months. The efficacy of mixed peeling, in

terms of re-organisation and contraction of the dermis, is manifested by the increase in the vermilion border of the upper and lower lips.

Pulsed timed surgical de-epithelialisation is used to eliminate wrinkles on the eyelids (see section 24.3). When the area has been de-epithelialised, resorcin solution is applied for a few seconds.

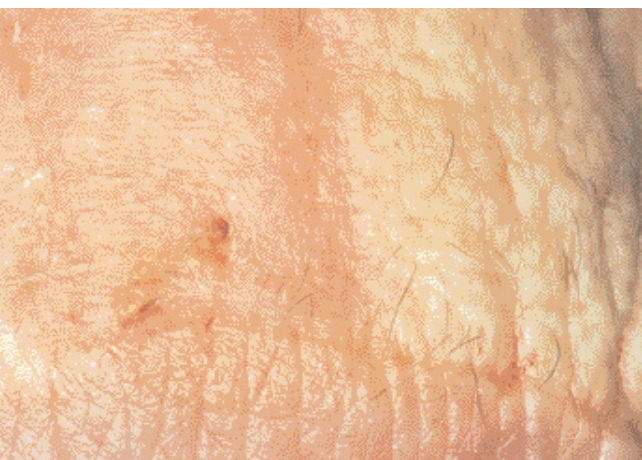

Fig. 28.1.3 Right: untreated area. Left: area treated with timed surgical mixed peeling, immediately after the crust has fallen. Note the dermal reorganization and consequent increase of the vermilion border.

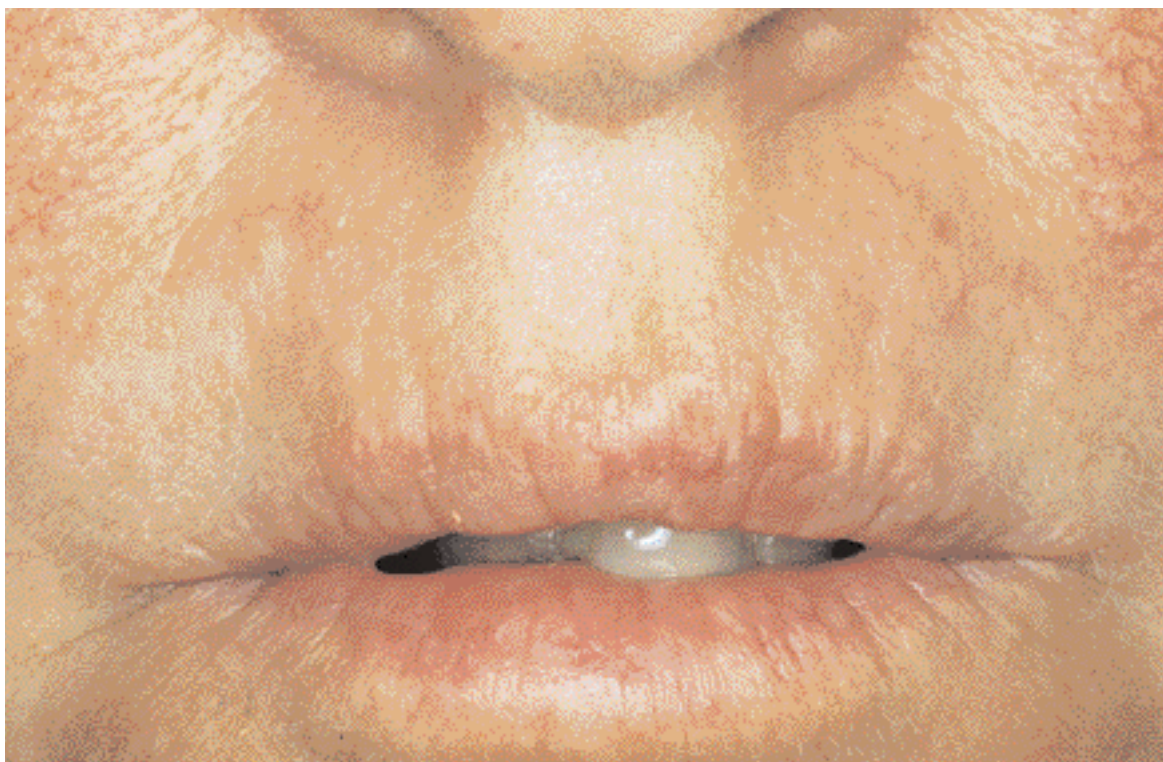
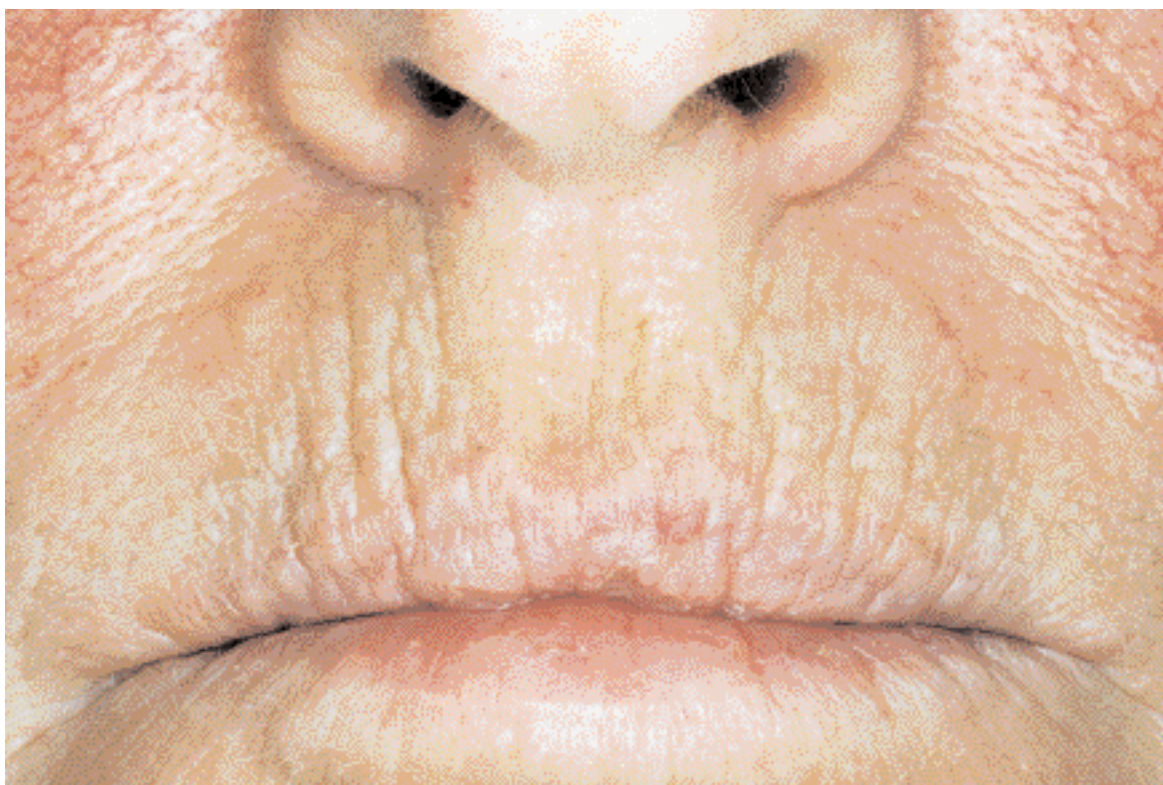
Fig. 28.1.4 Mixed peeling. Timedsurgical de-epithelialisation. Programme data: **coagulation with microelectrodes, 1 Watt, EM 10 Yellow** electromaniple, bent at an angle. Regional anaesthesia. The saturated resorcin solution is applied for 120 seconds.

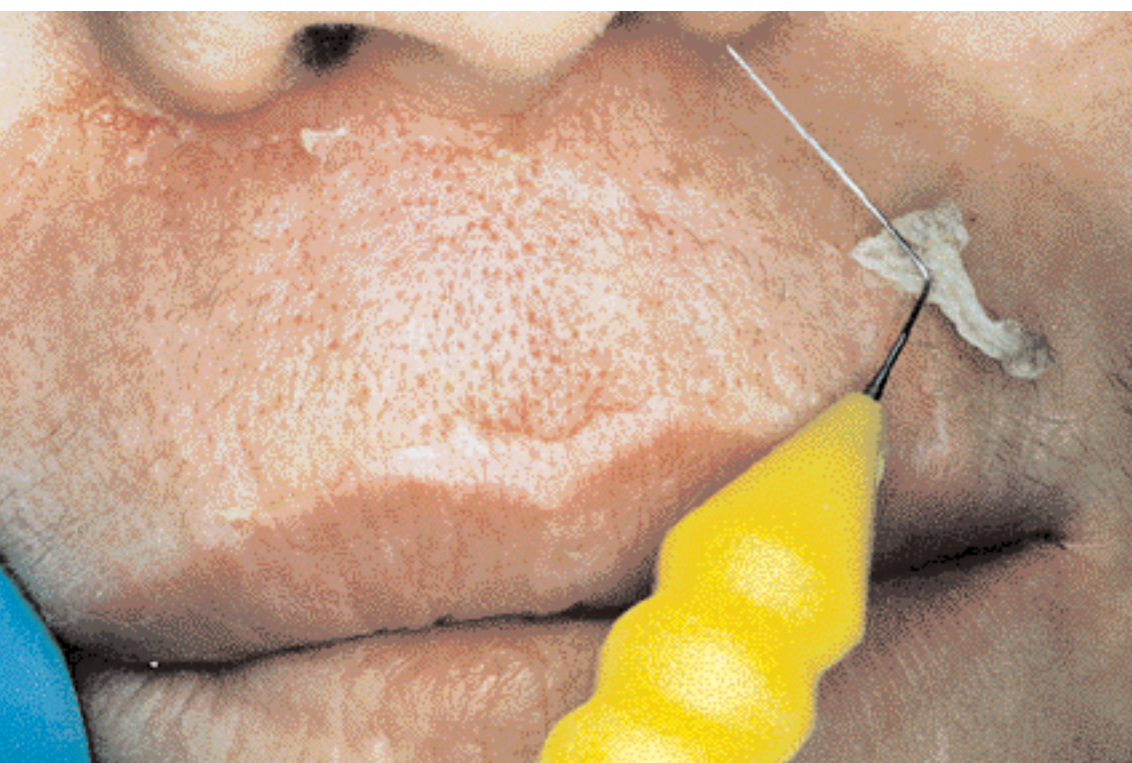
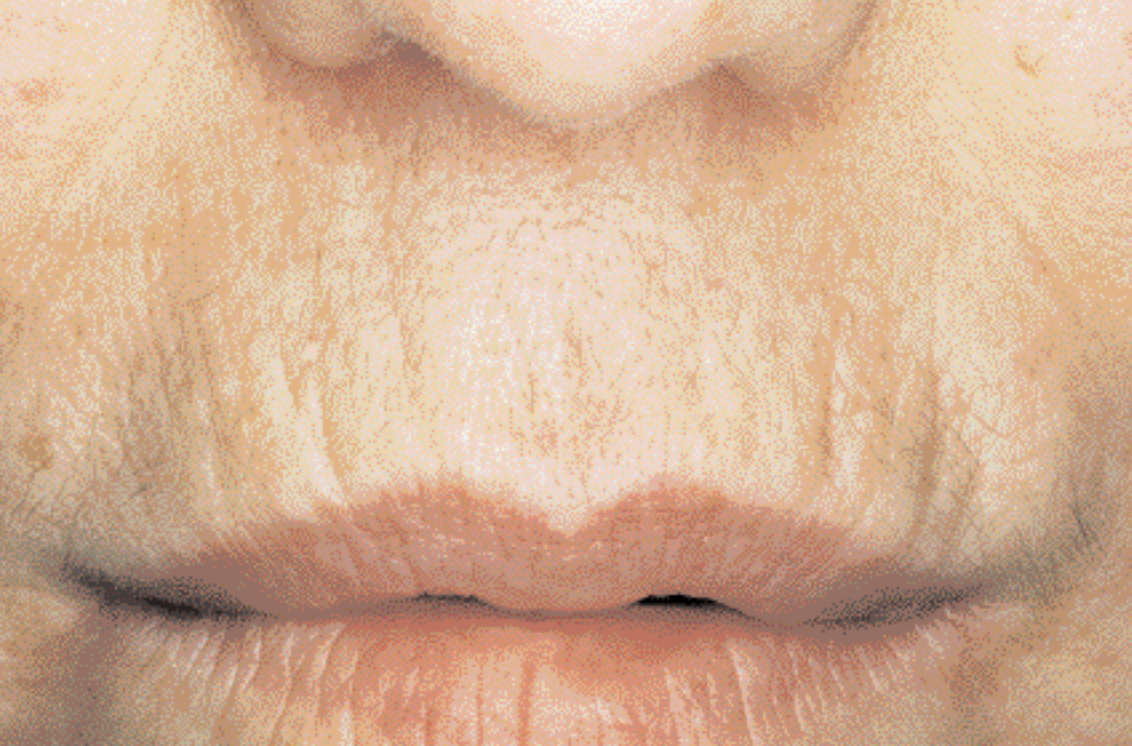

Fig. 28.1.5 Mixed peeling. Timesurgical de-epithelialisation at **1 Watt**. De-epithelialisation extend **5 mm** beyond the nasolabial folds.

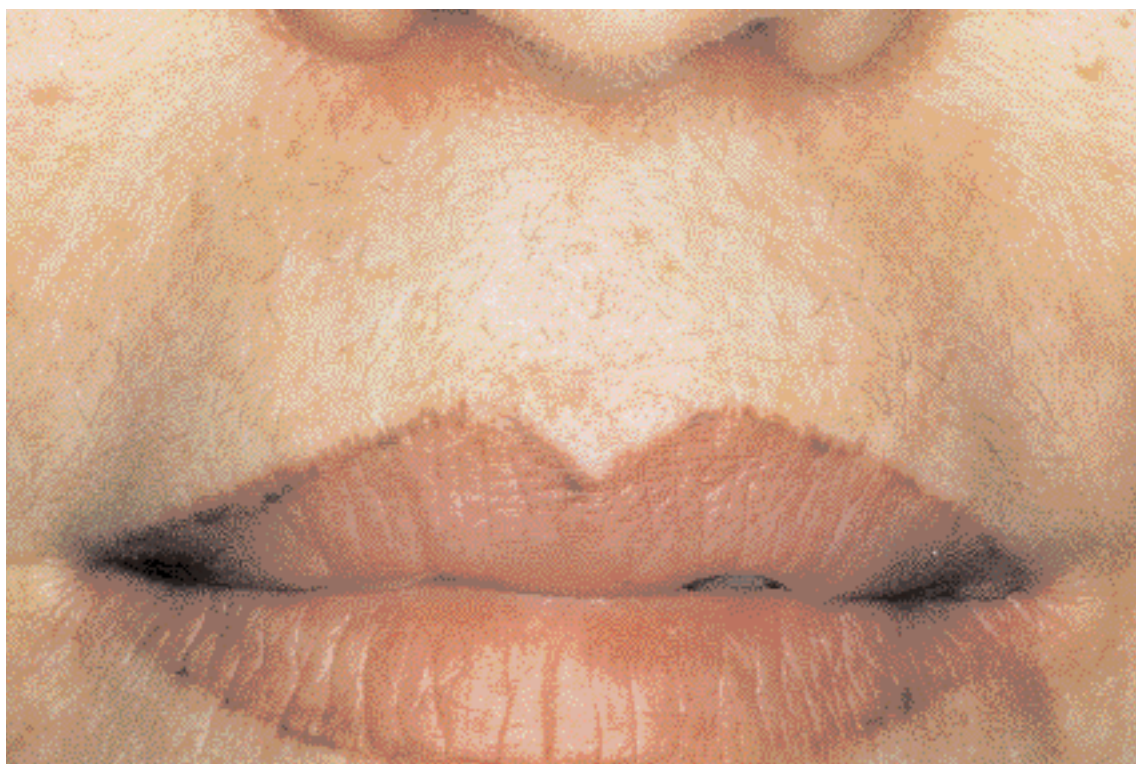
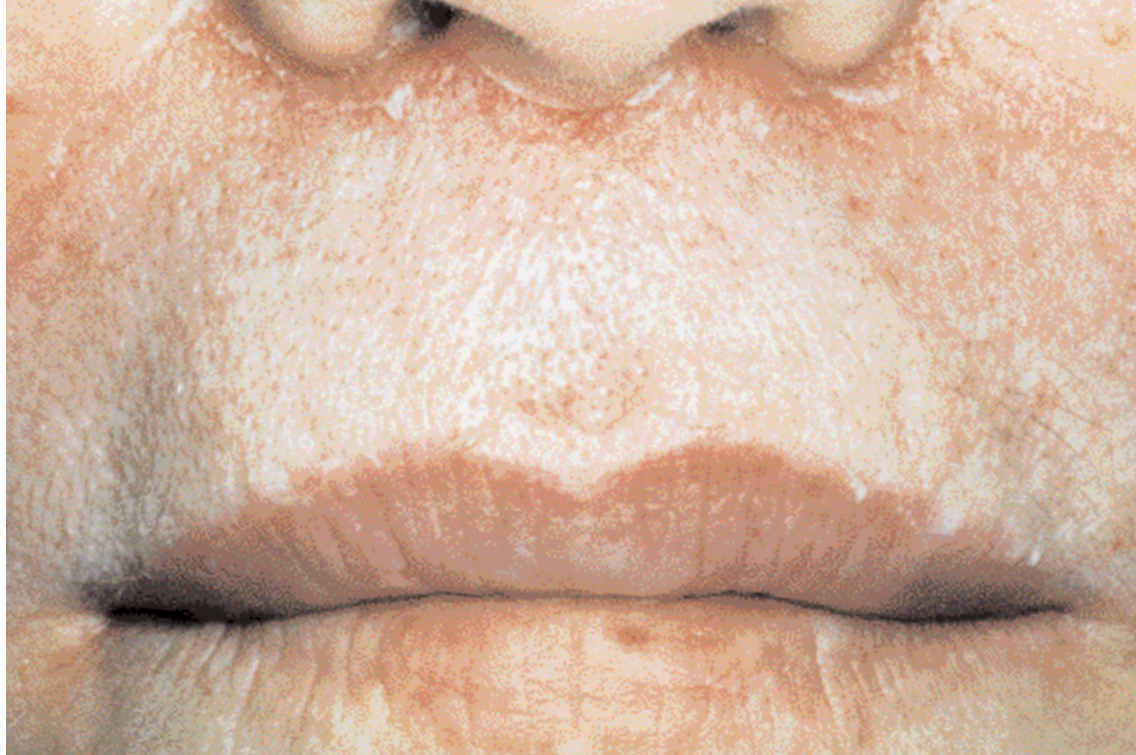
Fig. 28.1.6 On completing the de-epithelialisation, a saturated resorcin solution is applied, which is washed off after 120 seconds. Result after three months.

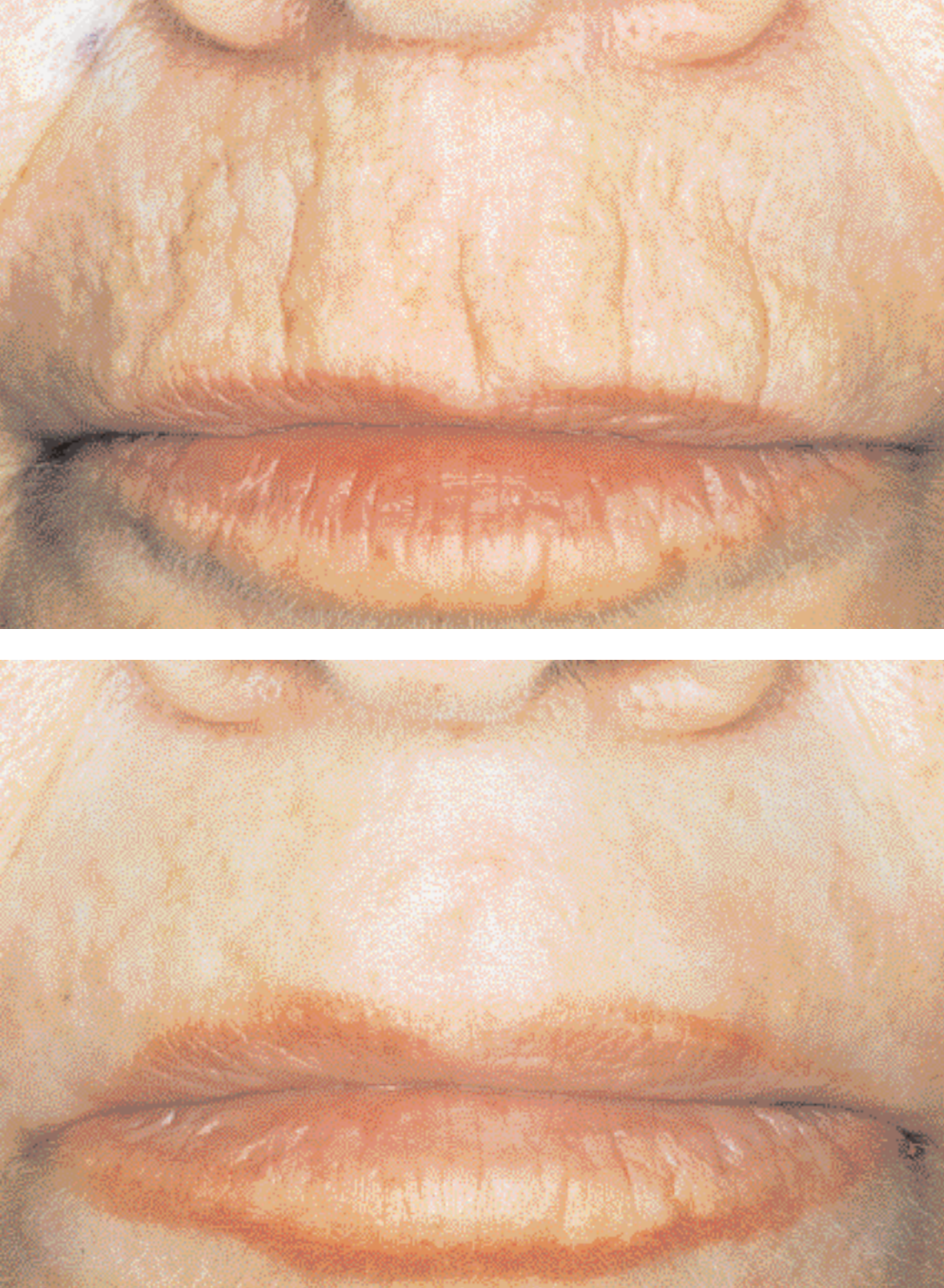

Fig. 28.1.7 Pronounced wrinkles. Mixed peeling. Timedsurgical de-epithelialisation at 1 Watt. The saturated resorcin solution is applied for 120 seconds. Result after three months.

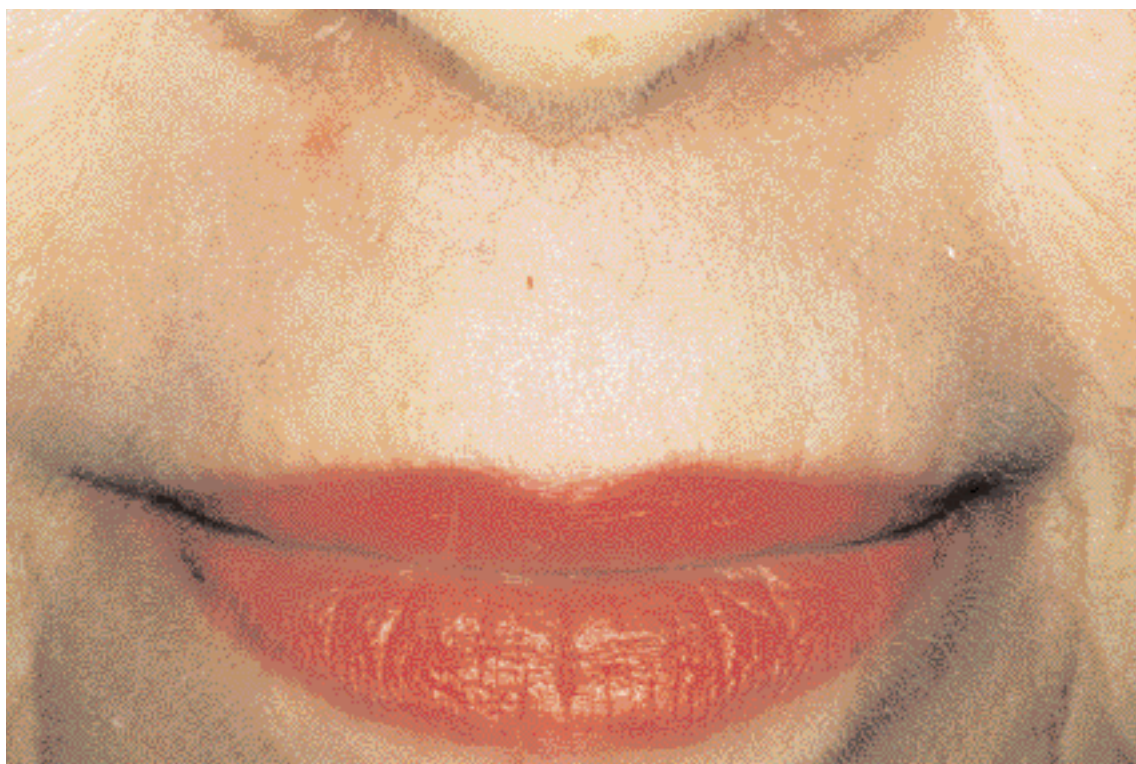
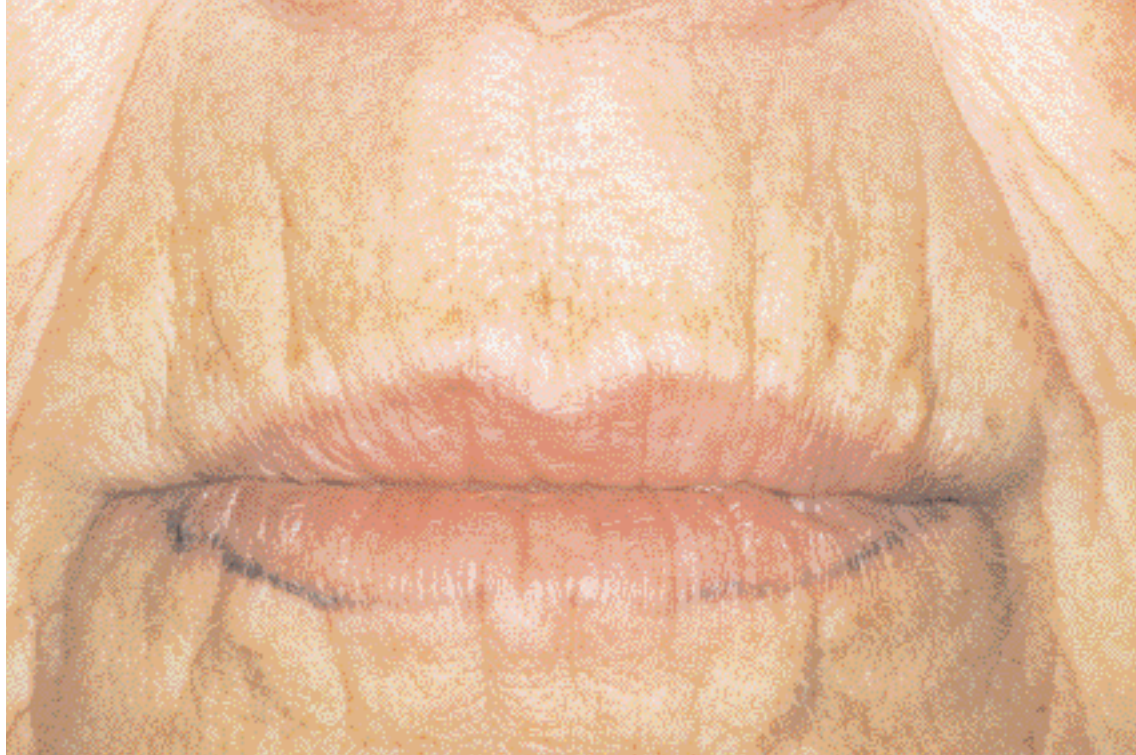

Fig. 28.1.8 Timsurgical mixed peeling. Result after two months.

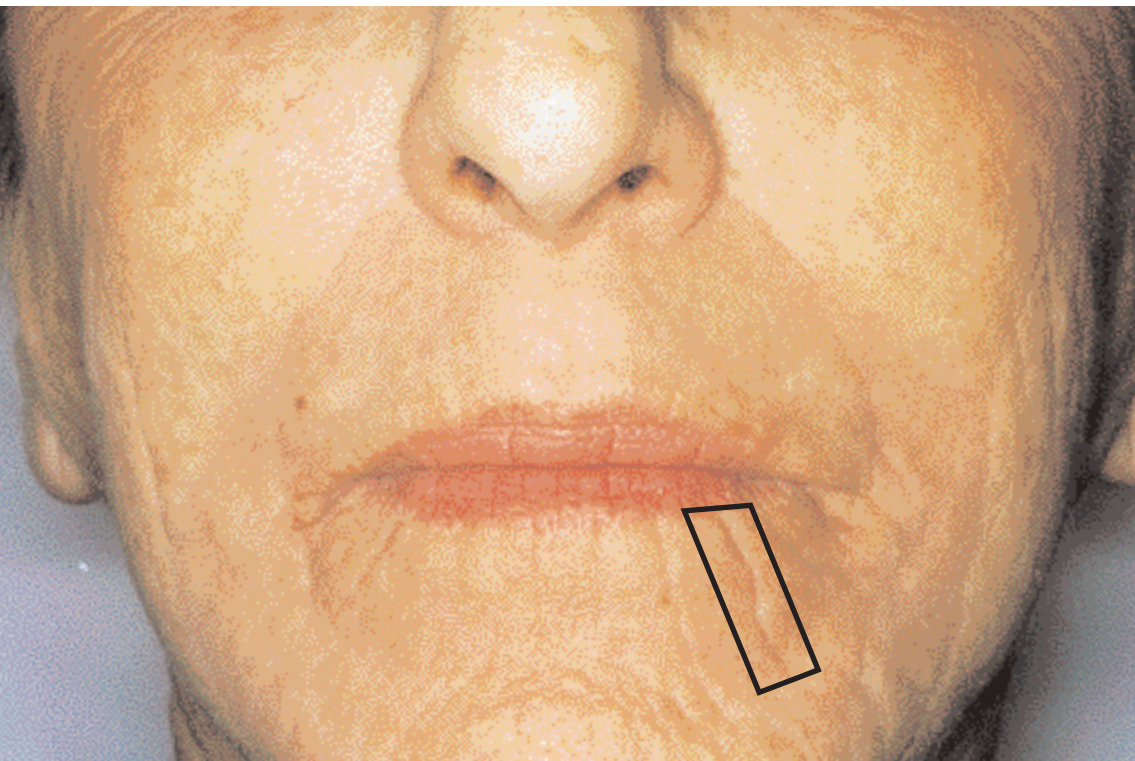
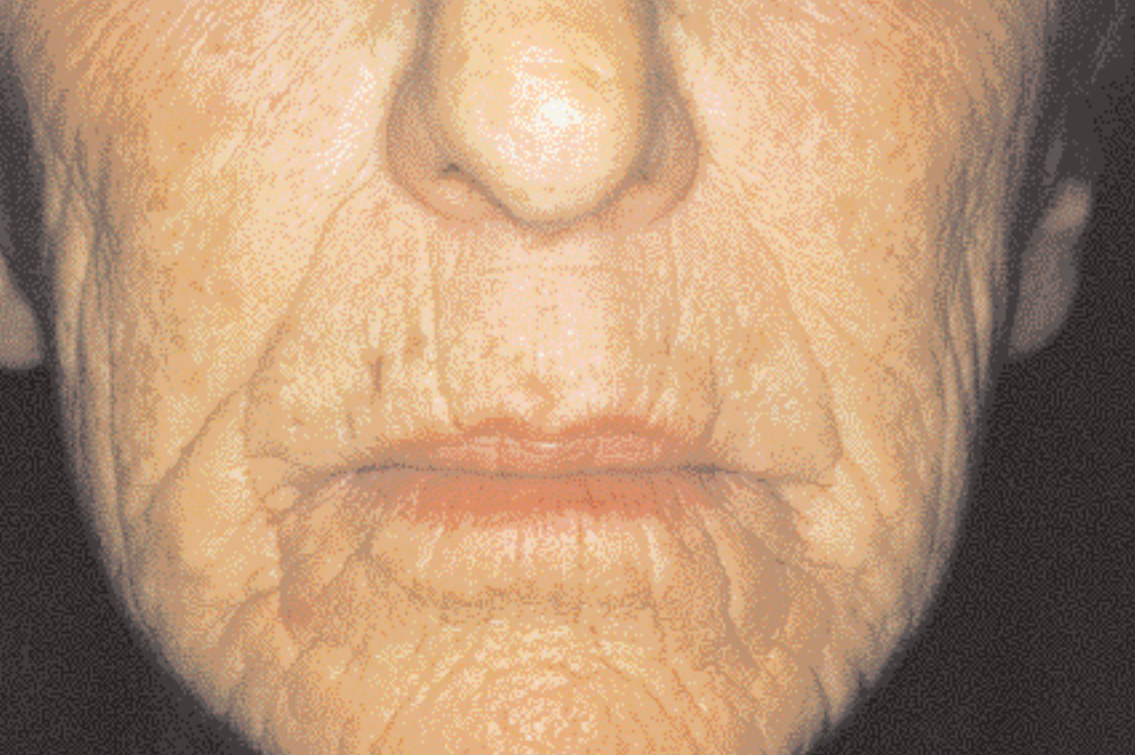


Fig. 28.1.9 Persistence of a few wrinkles after timesurgical mixed peeling. The wrinkles may be retreated individually after six months.

29

TREATMENT OF BIRTHMARKS

Naevi flammei are purple to red congenital marks which are flat or, in the elderly, slightly raised. They do not tend to regress spontaneously. They are often situated on the face. Treatment alternatives to lasersurgery consist of sclerotherapy with Bisclero and of mixed peeling or recently of timed surgical resurfacing at 50 or 100 Watts.

29.1 Bisclerotherapy

The 8% or 10% Bisclero sclerosing solutions (see section 20) may be injected into the vessels and venous lakes of the angioma at the beginning of treatment. In these patients the ectatic vessels are often deeper under the skin, in the sub-cutaneous tissue, where they can only be attacked with sclerosing solution (**Fig. 29.1.1**).

Eliminating a superficial vascular network by means of mixed peeling often exposes larger ectatic vessels, which can be injected with Bisclero.

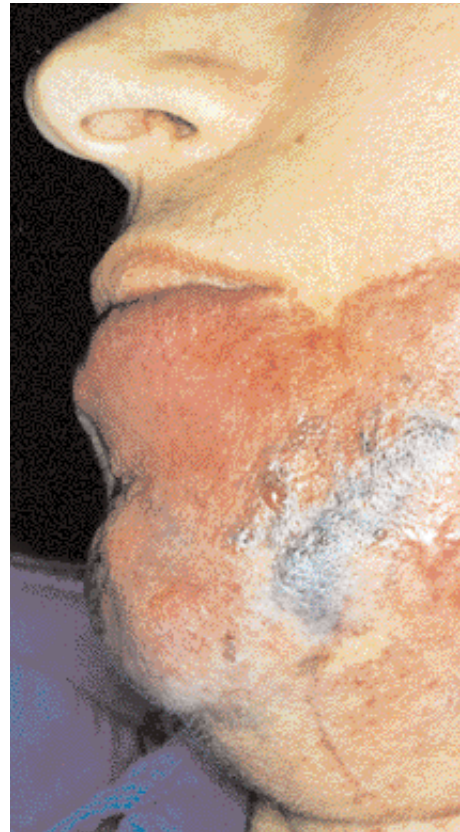
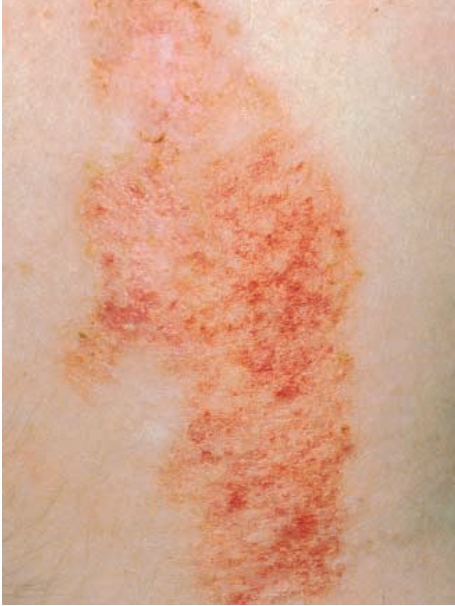
Fig. 29.1.1 Naevus flammeus. The treated area blackens immediately after the 8% Bisclero solution has been injected.



29.2 Mixed peeling

Programme data

Direct - Coag microelectrodes - 1 Watt - EM 10 Yellow (bent at an angle)

By means of timed surgical de-epithelialisation followed by the application of resorcin solution, it is possible to treat every type of naevus flammeus (**Fig. 29.2.1**). The procedure is particularly suited to the treatment of raised naevi flammei, which are not amenable to laser surgery.

After positioning the return electrode and disinfecting the area, the operator administers a local anaesthetic. The Timed apparatus is set to the direct mode and the function to **coagulation with microelectrodes**. Power is set to **1 Watt**. An **EM 10 Yellow** electromanipule, bent at an angle, is used. De-epithelialisation is carried out gently by skimming the skin with the angle of the electromanipule in small circular movements.

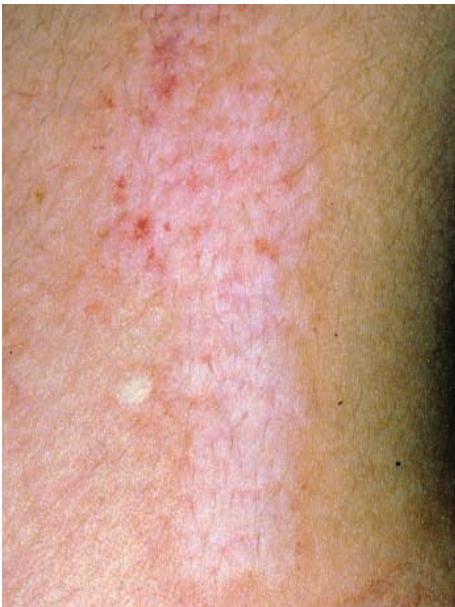
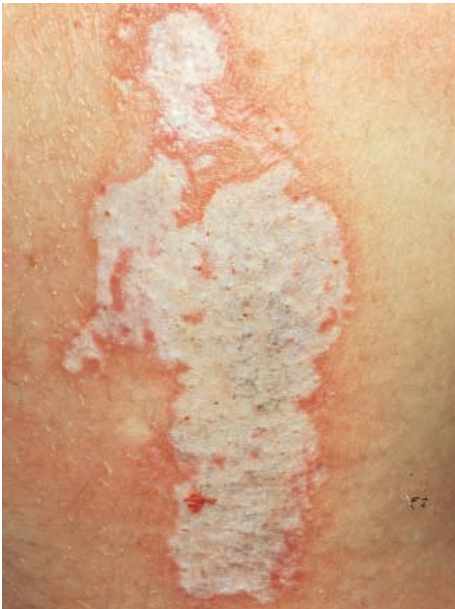
Fig. 29.2.1 Mixed peeling of a naevus flammeus. Timed surgical de-epithelialisation. (top). Application of a saturated resorcin solution, which is rinsed off after 1 minute (middle). Result (bottom).

On the face, a large area may be de-epithelialised (**Fig. 29.2.2**). It is necessary to consider, though that, after treatment, a crust will form, which will impede movement. It is therefore preferable to divide the area into smaller zones, separated by intact skin.

When the de-epithelialisation is finished, a small quantity of resorcin powder is dissolved in a few drops of sterile water and this solution is applied to the de-epithelialised area with a cotton wad. After 30 seconds the resorcin is washed off with physiological saline solution. The treated area is dried with a gauze and the resorcin solution is re-applied for another 30 seconds and then washed off again with physiological saline. The process is repeated for a total of 2 minutes. The resorcin must come into contact with the vessels of the angioma that have become dark (**Fig. 29.2.3**). If the telangiectasia is deep, the operator can make hundreds of perforations in the treated area by setting the function to **rapid pulsed** cutting at **14 Watt** and fitting an **EM 10 White** electro-maniple.

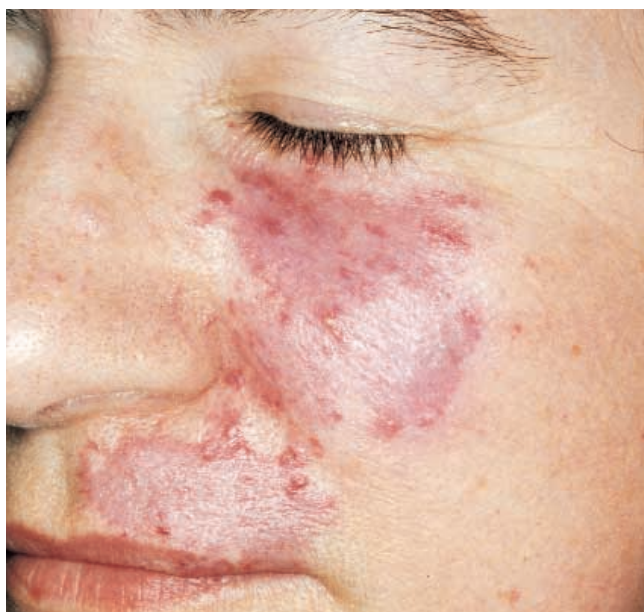
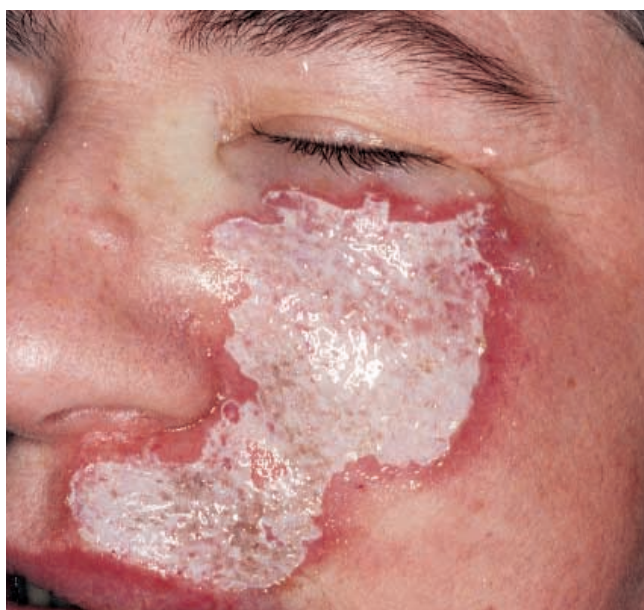
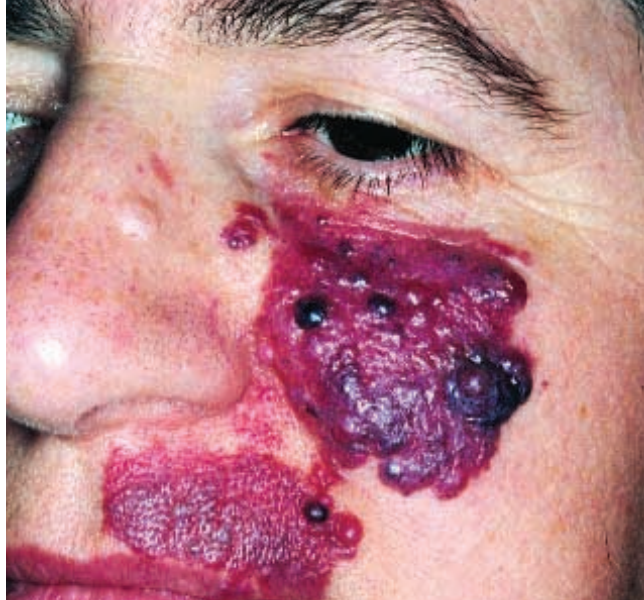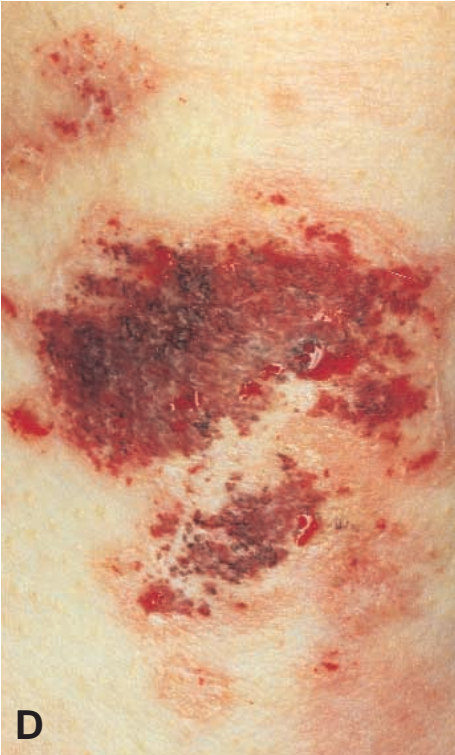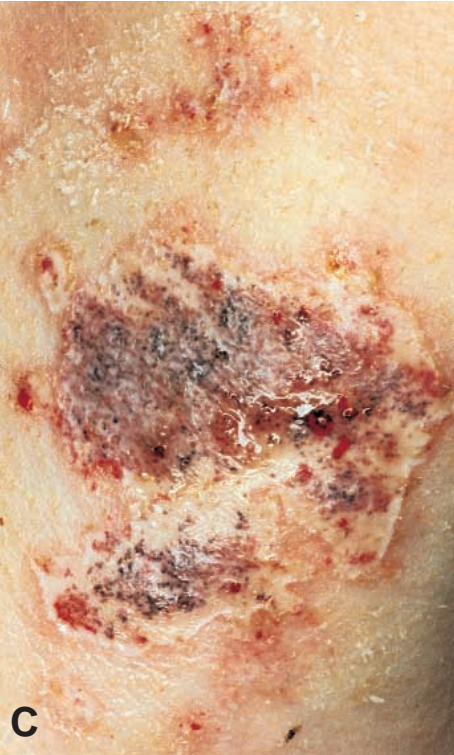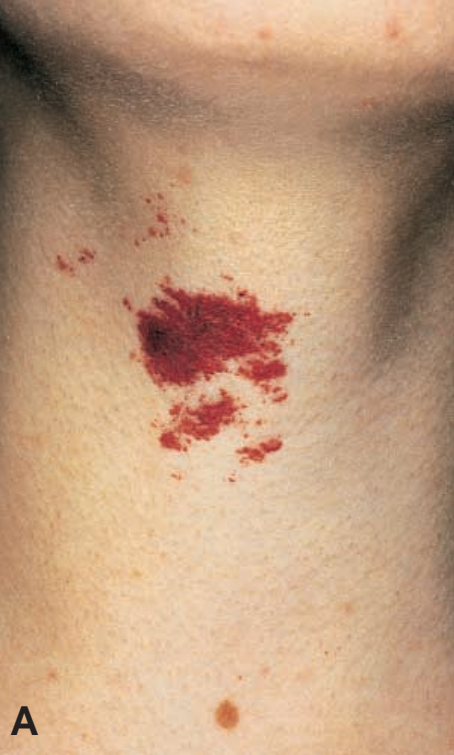Fig. 29.2.2 Timedsurgical mixed peeling of a naevus flammeus. Timedsurgical de-epithelialisation and application of a saturated resorcin solution for 2 minutes. Programme data: **coagulation with microelectrodes, 1 Watt, EM 10 Yellow** electromaniple, bent at an angle. Local anaesthesia. Result after three sessions.

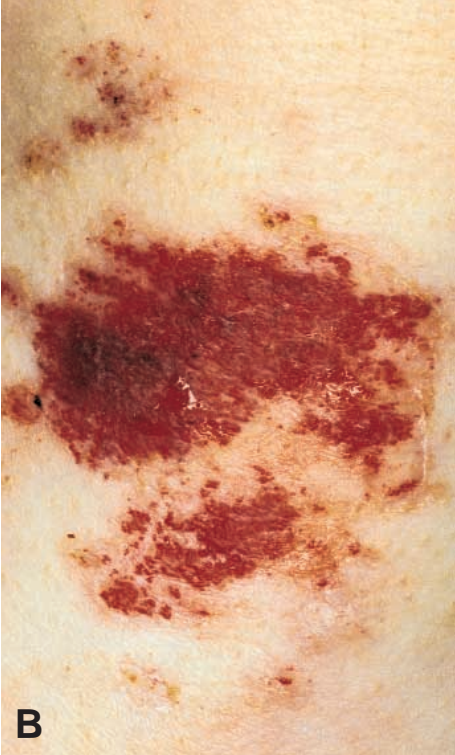

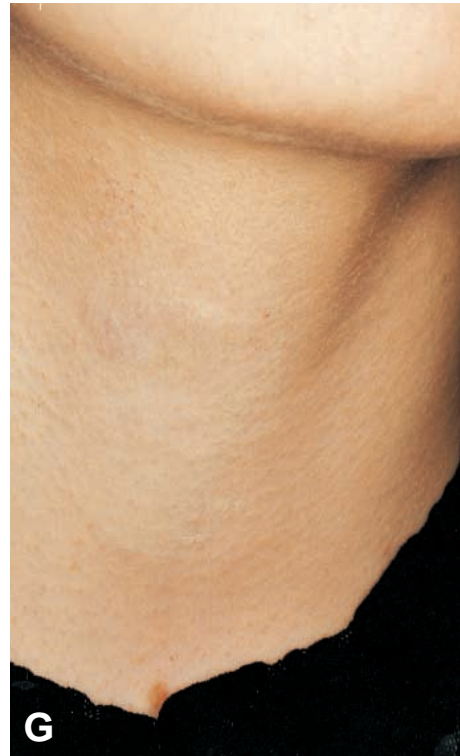
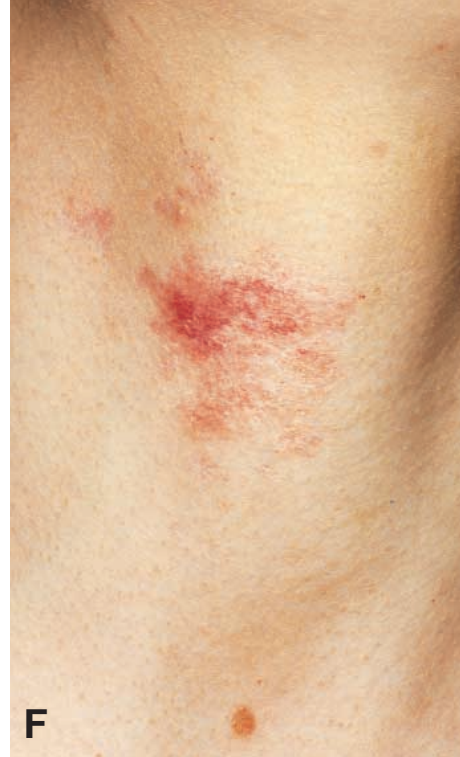
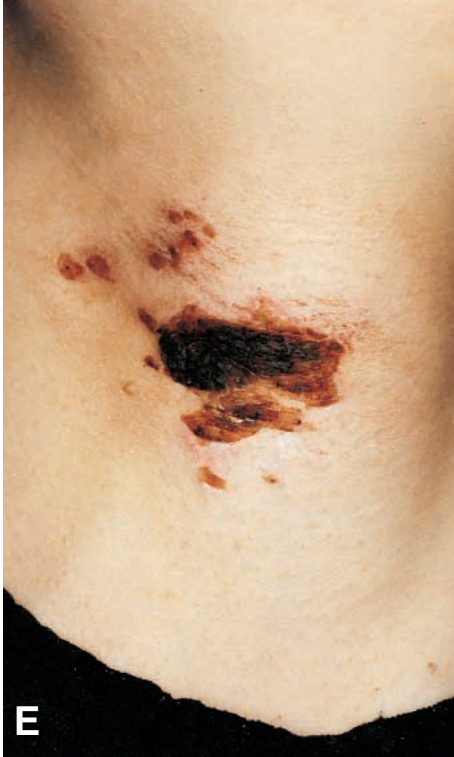
Fig. 29.2.3 A) Naevus flammeus. B) Timedsurgical de-epithelialisation. C) Application of the saturated resorcin solution. D) Rinsing. E) The crust forms. F) Result after the first application. G) Result after 4 sessions of mixed peeling.

The treated area will remain slightly swollen for a few days. On the face, a crust forms in a few hours and falls spontaneously in 9-11 days. The area must not be washed. The crust begins to detach at the edges and the patient may remove it with a pair of tweezers if it is already loose. During the night the crust must be protected with a gauze and a plaster. The rapid crust formation, which is due to the properties of resorcin, reduces the risk of infection. However, patients with acne in the active phase must not be treated with mixed peeling. After the crust falls, no creams should be applied for a week because the epidermis must become keratinised. After this period, the area must be protected from the sun. The area will remain pink for three or four months.

The number of sittings, from 1 to 15, depends upon the depth of the ectatic vascular network. To re-treat the same area it is necessary to wait for at least 2 months after the crust falls.

In more serious cases, the aesthetic result is improved because the subcutaneous telangiectasia is masked by the cutaneous fibrosis which occurs after a number of sittings.

Mixed peeling allows risk-free treatment of the most delicate regions of the face, for example the eyelids. In addition, hair, for example eyelashes, need not be removed (**Fig. 29.2.4**).

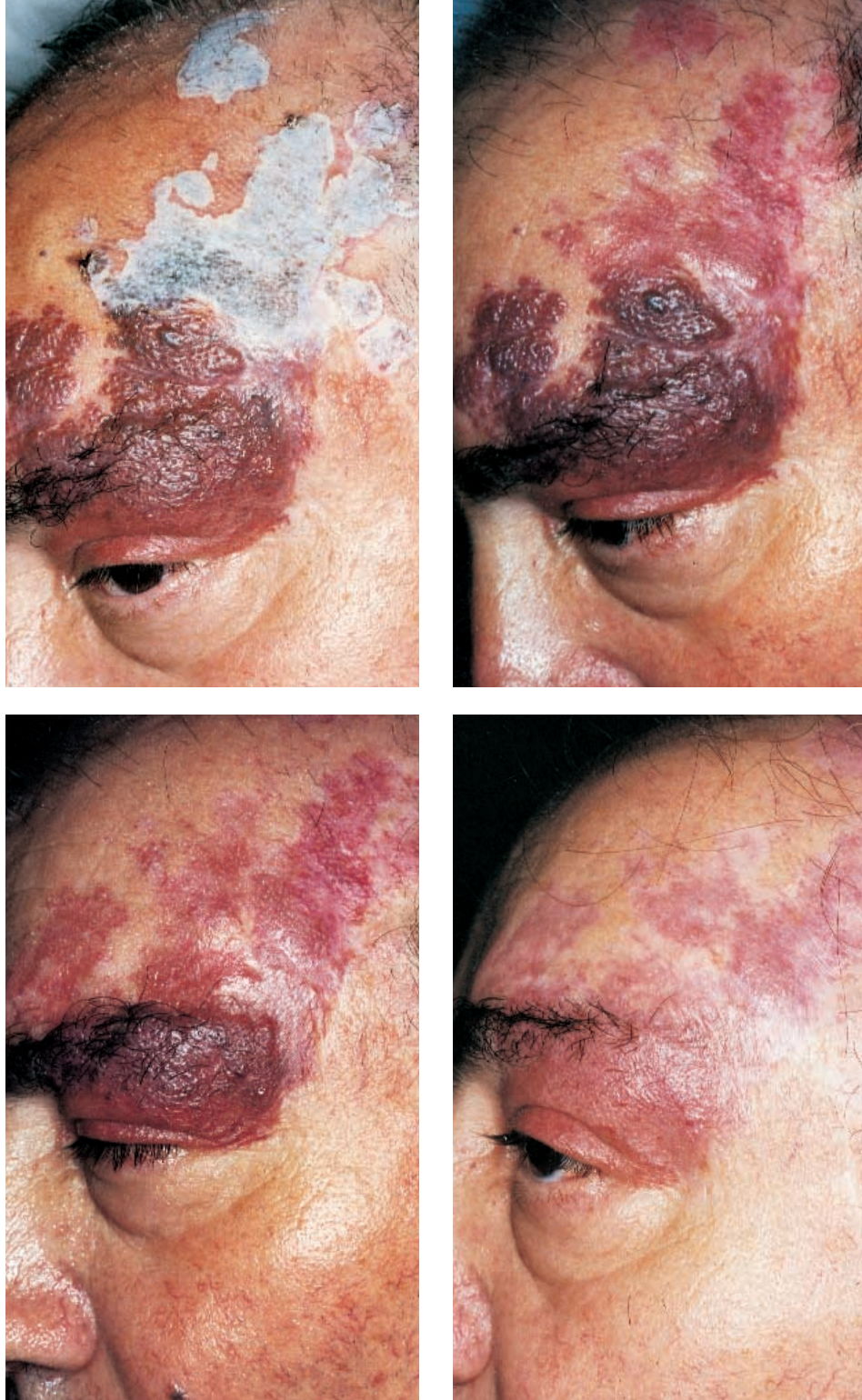

Fig. 29.2.4 Mixed peeling of a naevus flammeus. Timesurgical de-epithelialisation and application of a saturated resorcin solution for 2 minutes. Programme data: **coagulation with microelectrodes, 1 Watt, EM 10 Yellow** electromaniple, bent at an angle. Local anaesthesia.

Normally, this treatment is not recommended on the limbs or trunk. In these regions it is necessary to carry out a test on a 1 cm square area, and evaluate the result after 3 months; if the test is satisfactory, small areas, no more than 4 cm. square, spaced well apart, are treated. On the trunk and limbs, the resorcin solution must be applied for only a few seconds and immediately washed off with physiological saline solution. The area is covered with non-adherent gauze. An area may be retreated only after 6 months. Because of the effect of resorcin on melanocytes, it is necessary to avoid the treatment on patients with a dark complexion.

Intense research is still being carried out in order to find more effective techniques for the treatment of naevi flammei.

Timed surgical resurfacing in the cutting function at 50 or 100 Watts has recently been tested as means of removing angiomatous tissue. This new technique looks extremely promising on account of its speed and the quality of the results obtained, and we believe that in the near future it will be able to replace the technique described previously.

30 TREATMENT OF SMALL CAVERNOUS HAEMANGIOMAS

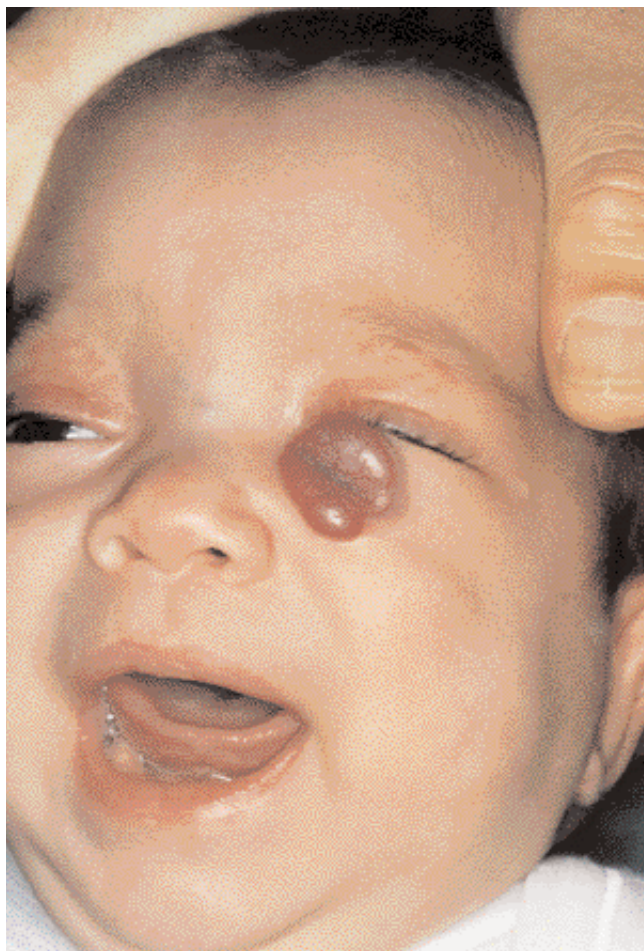Benign tumours of blood vessels can occur on tegument. These are frequently congenital as embryonic malformations, or may manifest themselves in the first few days of life. Depending on the proportions of the structure and extent of the vessel components, a histological distinction can be made between cavernous haemangioma, haemangiofibroma, fibrohaemangioma, lipohaemangioma and haemangiolymphangioma. From the point of view of the treatment, it is possible to divide these into two types: cutaneous cavernous haemangiomas and subcutaneous or submucosal cavernous haemangiomas.

30.1 Cutaneous cavernous haemangiomas

Programme data

Timed 99 hundredths of a second - Coag macroelectrodes - 14 Watt - Bipolar - Bipolar electrode.

After a phase of rapid development, cutaneous cavernous haemangiomas spontaneously regress in about 70% of patients. Treatment must be carried out if function is impaired by the location of the lesion (**Fig. 30.1.1**) or if recurrent haemorrhaging occurs. Another indication is



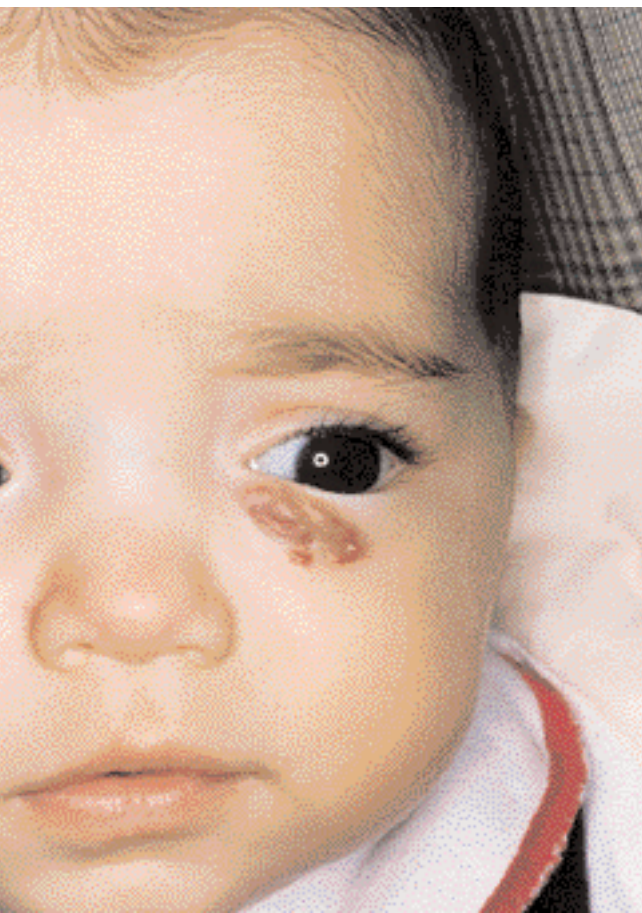
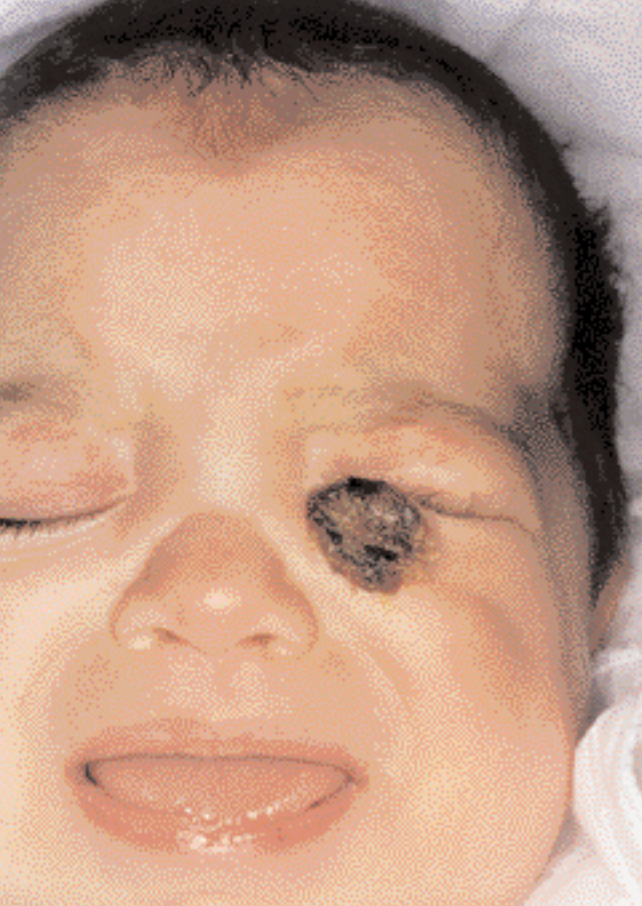
Fig. 30.1.1 Timed bipolar coagulation of cutaneous cavernous haemangioma. The rapid growth of the angioma impairs use of the left eye. Programme data: **coagulation with macroelectrodes, 14 Watts, 99 hundredths of a second**, bipolar electrode. General anaesthesia. A week after timed bipolar coagulations performed tangentially to the skin surface (top). Though still present, the haemangioma is reduced in volume (bottom). The timed bipolar coagulations have paved the way for spontaneous regression of the cutaneous cavernous haemangioma.

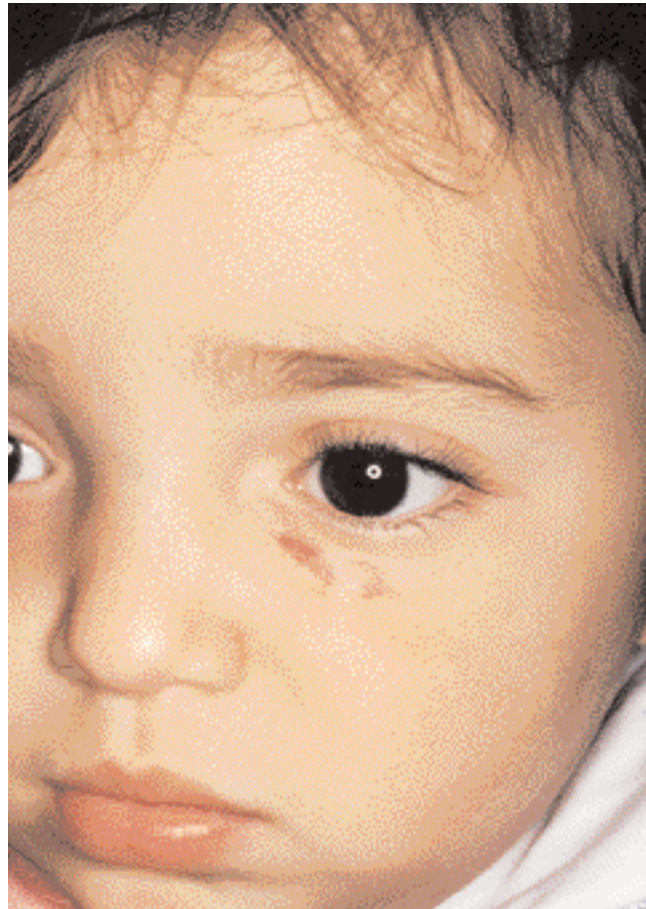cosmetic disfigurement caused by haemangiomas situated on the face which will not regress further. The haemangioma cannot be completely coagulated but only reduced with timed bipolar coagulation. The operation is very rapid and bloodless. Babies of a few months old may be treated.

After administering a general anaesthetic and disinfecting the area, the operator sets the Timed apparatus to timed **99 hundredths of a second, 14 or 20 Watts and coagulation with macroelectrodes.**

Bipolar electrodes, as used for the coagulation of nasal turbinates, are used (see fig. 42.0.1). The points of the bipolar electrode are inserted into the angiomatous mass parallel to the cutaneous surface and then a timed emission is generated. The electrode is then removed and re-inserted into an adjacent position and another emission is generated. During the emission, the characteristic sound of bipolar emission is heard and the tissue between the points of the electrode retracts and coagulates.

On extraction of the points, there is no bleeding. Coagulation of the surface of the mass will take only a few minutes. The treated area is covered with a non-adherent gauze; a few days later a crust forms, after which spontaneous reconstruction occurs. The cutaneous cavernous haemangioma is markedly reduced and the condition is monitored to verify rapid spontaneous regression (**Fig. 30.1.2**).

Fig. 30.1.2 Result after 6 months. Regression of the cavernous haemangioma is almost complete.



For good aesthetic results the treatment should not be aggressive: only a simple reduction of the tumour should be carried out. After the crust has fallen, a small portion of the haemangioma should be visible. This will disappear in the following months.

30.2 Subcutaneous cavernous haemangiomas

Programme data

Direct - Coag microelectrodes - 10 Watt - EM 10 Yellow

Small subcutaneous and submucosal haemangiomas do not have the tendency to spontaneously regress which characterises cutaneous cavernous haemangiomas. If they are situated on the face (**Fig. 30.2.1**) it may be necessary to use sclerotherapy. In this case, sclerosing solution is injected, starting with a less inflammatory solution (8% Bisclero). The treatment is completed with more potent sclerosing solutions. If venous lakes remain (**Fig. 30.2.2**), these may be coagulated by means of a monopolar emission. An **EM 10 Yellow** electromanipule is inserted into the vessel and a prolonged emission of **10 Watts** is generated (**Fig. 30.2.3-4**).

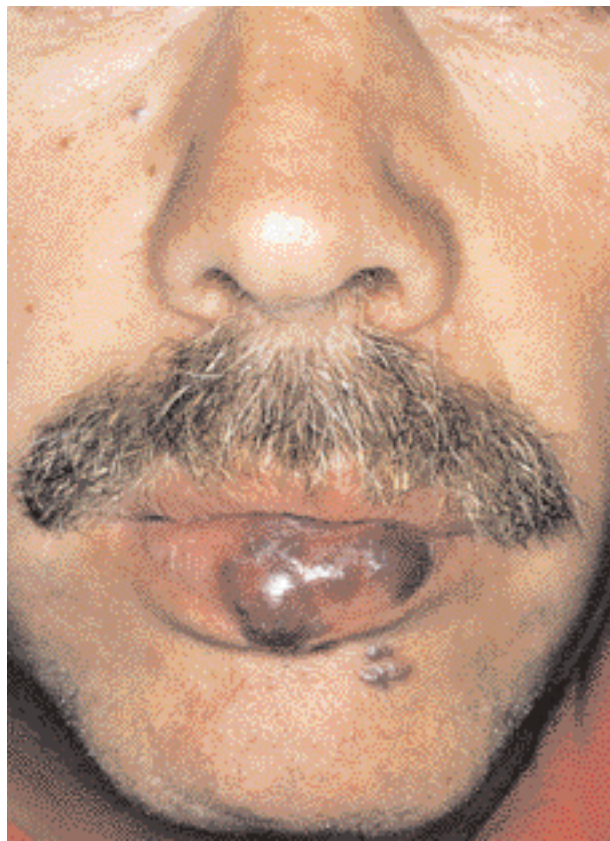

Fig. 30.2.1 Subcutaneous and submucosal cavernous haemangioma.

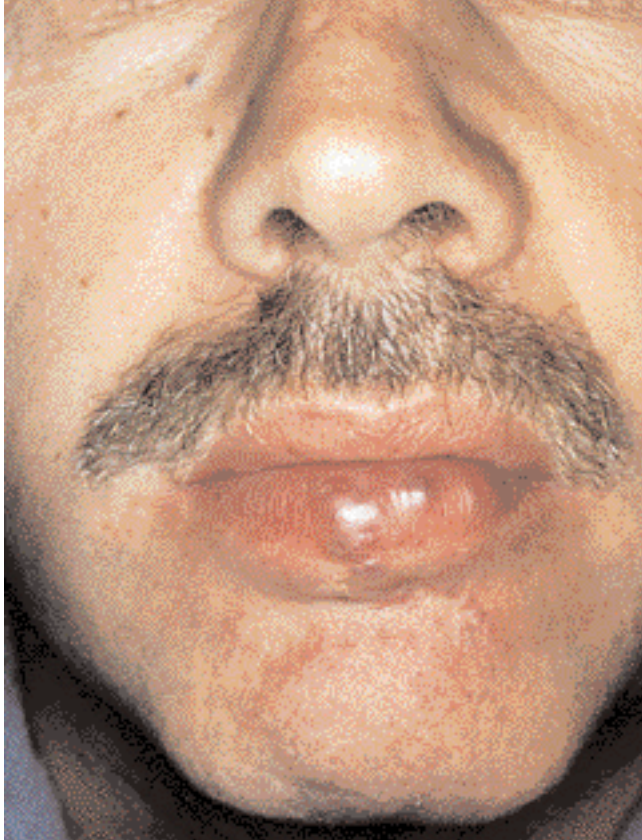


Fig. 30.2.2 A few venous lakes remain after sclerotherapy.

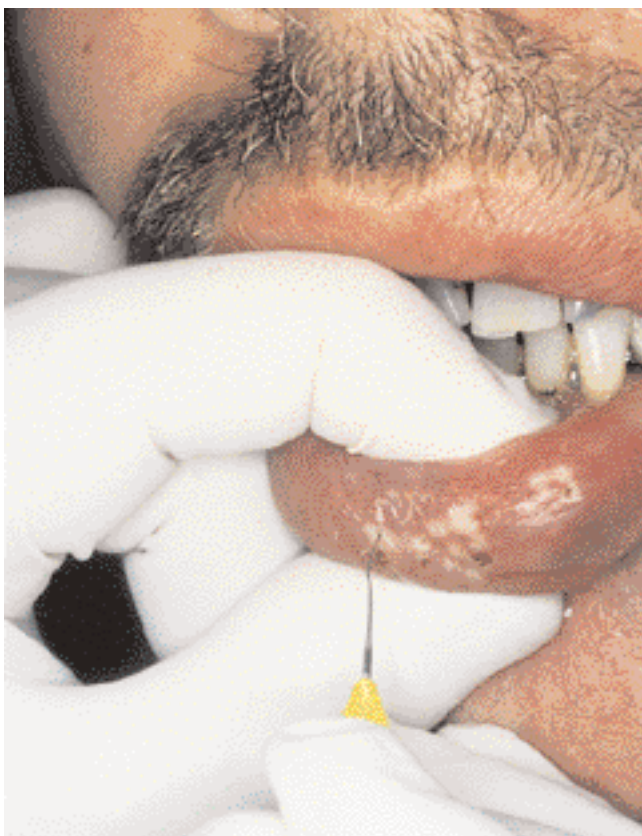


Fig. 30.2.3 Coagulation of the venous lakes. Programme data: **coagulation with microelectrodes, 10 Watts, EM 10 Yellow** electromaniple. Local anaesthesia.

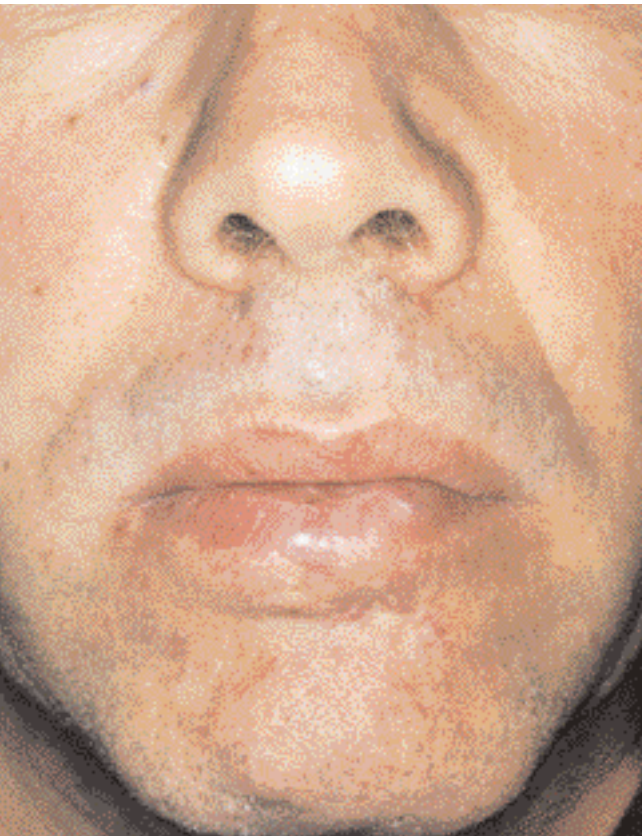


Fig. 30.2.4 Result.

31

INTRODUCTION TO TREATMENT OF BENIGN SKIN LESIONS

A number of techniques are suitable for the treatment of benign skin lesions, including excision, cryotherapy, acid destruction, thermocoagulation, lasersurgery, radiotherapy, electrosurgery and timed surgery.

31.1 Surgical excision

Surgical excision is the method of choice for undiagnosed lesions, for lesions requiring full histological diagnosis and for potentially malignant melanocytic lesions. Excision also allows the adequacy of the treatment to be verified. Viral warts, however, may recur after excision, owing to residual virally infected cells and, with small superficial benign lesions, the scar left by a full-thickness excision may be more evident than the original lesion. Surgical excision may be performed by means of timed or pulsed slow or rapid cutting (see section 43).

31.2 Cryotherapy

Cryotherapy with nitrous oxide or liquid nitrogen is used mainly for superficial lesions, as the circulation of blood impedes deep penetration of the cold. It has the advantage of seldom requiring local anaesthetic,

but causes considerable post-operative pain. Cryotherapy is slow and imprecise and often needs to be repeated. Its main value is in the treatment of viral warts. Common warts situated on the load-bearing areas of the soles of the feet and in the area around the nails are treated after removal of the superficial layer of horny material which covers them. Cryotherapy has applications in other fields, for example cardiology, where it is used to treat drug-resistant tachycardia by destroying alternative conduction pathways; high-frequency current has also been used for this purpose (Pace 1988).

31.3 Acids and caustic salts

Acids and caustic salts are used to treat viral lesions. The treatment is neither aggressive nor painful, but often requires several applications. Because it does not leave scars, the technique is recommended for plane warts and, after eliminating any cornified superficial cells, for common viral warts and plantar warts.

The wart should be pared down with a scalpel blade until the hyperplastic tissue has been removed and the small papillary vessels are seen as punctate bleeding points (**Fig.**

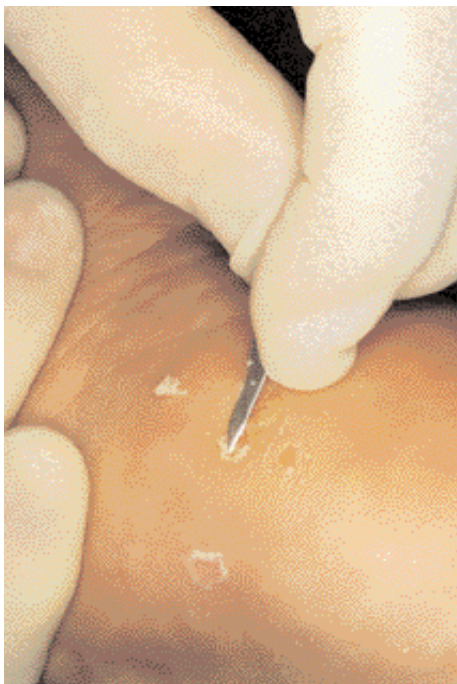

Fig. 31.3.1 Plantar wart. Removal of cornified layer with a number 15 scalpel blade.

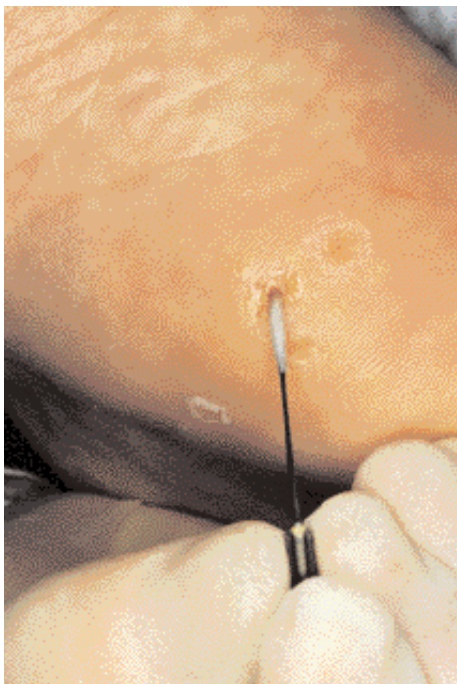

Fig. 31.3.2 Application of 70% trichloroacetic acid

31.3.1). After the bleeding has been stopped, a caustic substance, such as potassium permanganate powder or 70% trichloroacetic acid is applied (**Fig. 31.3.2**).

The acid is applied with a small cottonwool bud fashioned by wrapping cottonwool around a small stick. The treated area turns white, and should be protected with an adhesive plaster. Treatment is repeated weekly until the wart disappears.

It is often helpful to apply 15% and 10% trichloroacetic acid after coagulation or timed surgical de-epithelialisation (see section 32).

The above-mentioned acids and caustic salts are only suitable for use by medical staff, while preparations of salicylic acid (10% to 60%) may be applied by the patient. The most common formula contains salicylic acid, lactic acid and flexible colloid. Every evening the patient must bathe the area in lukewarm water for at least five minutes, remove the superficial cornified layer with a blade or abrasive stone, dry well, then put a drop of the solution onto the remaining wart and cover it with adhesive plaster after it dries (Tomas 1988).

31.4 Thermocoagulation

Cauterisation has ancient origins. Cautery apparatuses consist of a transformer which supplies a low-voltage current to a fine wire electrode, which is thus heated to incandescence. A cherry-red colour indicates that the element has reached the correct temperature. Too low a temperature causes the coagulated tissue to adhere to the metal; too high a temperature

makes the electrode fragile and destroys too much tissue over too wide an area. A rheostat enables the current to be regulated. The metallic loop cannot maintain a constant temperature as it loses heat as soon as it comes into contact with the tissues. Coagulation with a cautery apparatus is indiscriminate and the extent of necrosis, which is the same as a burn, is not easy to predict. Lesions produced with this technique are slow to heal. Heat from the element is transferred by conduction and radiation. The burn produced by thermocautery is more painful than that produced by a diathermic current and the burning sensation remains for longer (see section 3.3). Residual scars from thermocoagulation may be unsightly and even hypertrophic. For these reasons the uses of thermocautery are limited.

31.5 Lasersurgery

Several types of laser are now available for skin treatment. One of the main areas of application is that of vascular malformations, and port wine stains. For the treatment of benign skin neoformations, the selective effect of lasersurgery depends upon the different absorption of the laser light by the lesion to be treated and the patient's skin. Unfortunately therefore, most lasers are of limited value in patients with deeply pigmented skin. Laser treatments have aroused considerable interest which, for many applications, may be unjustified. "Perhaps the prospects we foresee for laser surgery are excessive; reali-

stically, the future of the technology will be tempered by a more complete comprehension of the physical and chemical mechanisms by which light interacts with the organs and cellular organisms. This research will help us to understand when to use and when not to use a laser. Knowing that in some cases a simple scalpel or electrosurgery may be more appropriate and less risky and costly than complex laser apparatus will be essential for future success in the medical field." (M.W. Berns in "Le Scienze" No. 276, August 1991).

31.6 Radiotherapy

Radiotherapy is used on inoperable, radiosensitive, malignant skin lesions, in a few benign lesions, keloid scars and, occasionally, angiomias.

The dangers of irradiation and the chronic effects of radiodermatitis limit its use.

31.7 Electrosurgery

Electrosurgery (surgical diathermy) has several advantages. It uses cold electrodes (see section 4.2) which may be very fine and of numerous shapes. It is controllable, precise, powerful, able to work in depth and allows rapid execution with optimum and prolonged control of bleeding.

In unanaesthetised patients it produces little post-operative pain. Scars are of good quality, soft and rarely hypertrophic. It is economical, and its action is independent of the colour of the lesion. The generator is easily transportable and no routi-

ne maintenance is required apart from cleaning and sterilisation of the electrodes and their substitution when worn out. Apart from monopolar and bipolar coagulation, the high-frequency current allows other functions to be utilized: cutting, coagulating cutting (blend), fulguration and micro-arc.

31.8 **Timedsurgery**

With the development of timedsurgery and its associated technology, many of the drawbacks of traditional electrosurgery have been overcome, thus enabling many procedures to be performed which were formerly impossible.

Timedsurgery utilises operating techniques specific to each procedure. These techniques are standardised and yield consistent results. Timedsurgery is the simplest and most versatile operating system in the field of dermatological, plastic and aesthetic surgery.

32

COAGULATION OF WARTS

Warts are benign cutaneous skin lesions of viral origin, produced by hyperplasia of the epidermis.

They are contagious and may be spread to other sites by autoinoculation.

To avoid recurrences, all warts present must be coagulated in one single session.

Recurrent and recalcitrant warts are associated with immunosuppression, such as induced in patients with renal transplants.

There are three distinct types of wart: common warts, plantar warts and plane warts.

appear pedunculated and filiform.

They are also found on the scalp, lips, eyelids, legs and knees.

Coagulation carried out under local or regional anaesthesia (**Fig. 32.1.1**) is completed by applying 15% trichloroacetic acid. Healing is rapid and there are no recurrences.

32.1 Common Warts

Programme data

Direct - Coag microelectrodes - 10 or 14 Watts - EM 15.

Common warts are most prevalent on the back of the hand and on the fingers in the area around the nails.

They appear as small, hard, greyish papules or nodules.

They may be solitary or in groups of numerous lesions; occasionally they become confluent and form a plaque. On sites such as the face, they may

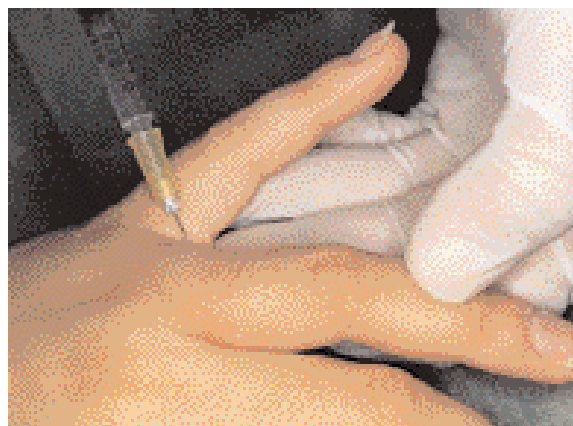
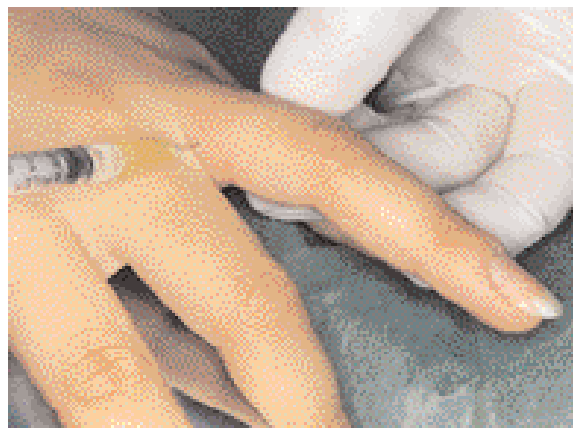
Fig. 32.1.1 With multiple warts on the finger and periungual areas, a digital ring block anaesthetic is carried out using 2% lignocaine without adrenaline.

Technique

After disinfecting the area, the operator connects the patient's return electrode and places it in contact with the skin, sets the Timed apparatus to the direct mode, in which emission time is controlled directly by means of the pedal, and the function to **coagulation with microelectrodes**.

An **EM 15** electromaniple is inserted and power set to **10 or 14 Watts**.

The power does not need to be higher; it must not destroy the wart, but slowly coagulate it.

Most viruses, including the papilloma viruses, are rapidly inactivated at temperatures above 60° C and the heat must reach an adequate depth to achieve this anti-viral action. Higher powers induce rapid dehydra-

tion at the point of contact and carbonisation of tissue, which limits the depth of penetration of the heat and increases the risk of scars and recurrence.

To improve conductivity, the cornified tissue should be moistened during the procedure with a gauze soaked in physiological saline or non-alcoholic disinfectant. Moistening the surface allows the passage of high-frequency current across tissue with a rich cornified layer, even at low power.

The tip of the activated electromaniple must slowly penetrate into the wart, where it executes a circular motion.

The activated electromaniple must remain in contact with the lesion (**Fig. 32.1.2**).

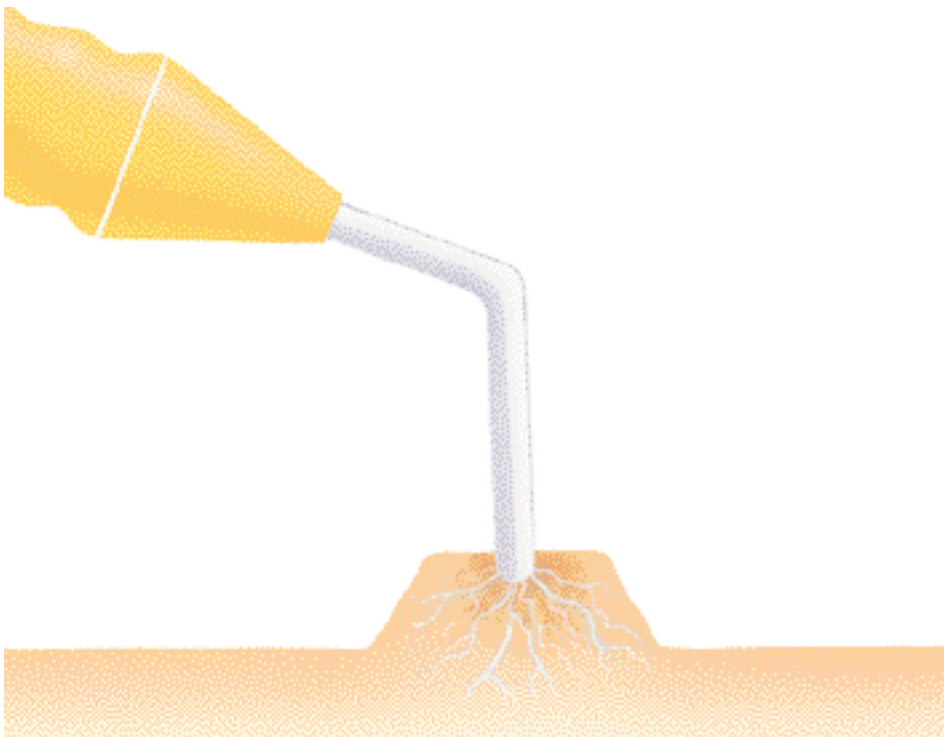


Fig. 32.1.2 The tip of the activated electrode slowly penetrates into the wart, where it executes a circular motion. Coagulation is complete when the wart is completely mobile on the plane of cleavage of the dermis.

If the wart is large, the tip of the electromaniple penetrates it in several places.

After being "heated", the wart detaches from the dermis and becomes mobile, remaining attached only to the surrounding epidermis. The operator removes it with scissors (**Fig. 32.1.3-4**).

If the wart has been properly coagulated, this manoeuvre does not cause bleeding.

The procedure is completed by dabbing with 15% trichloroacetic acid.

It must be borne in mind that the dermis does not need to be penetrated, as it is the antiviral effect of the heat which is exploited.

An antiseptic powder or cream is applied to the wound at the end of the operation.

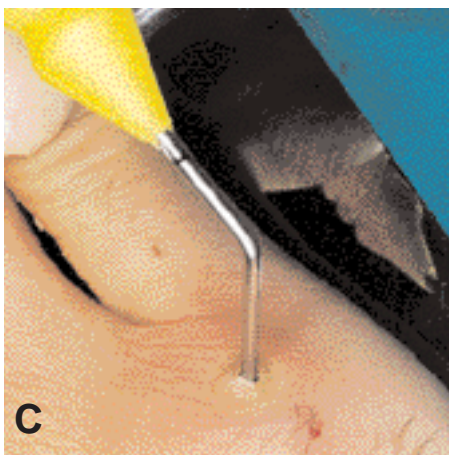
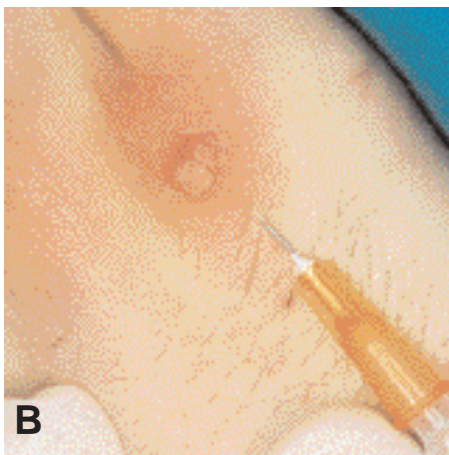
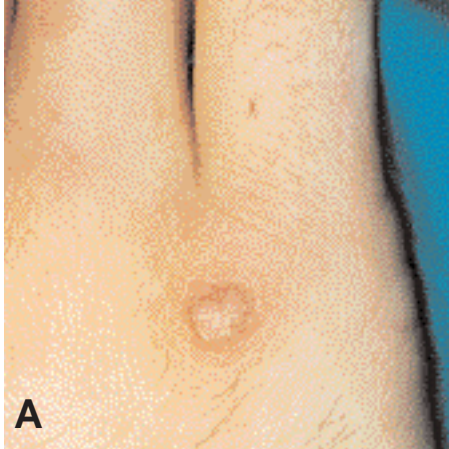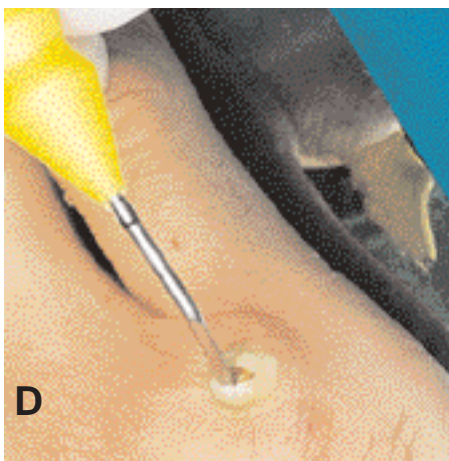
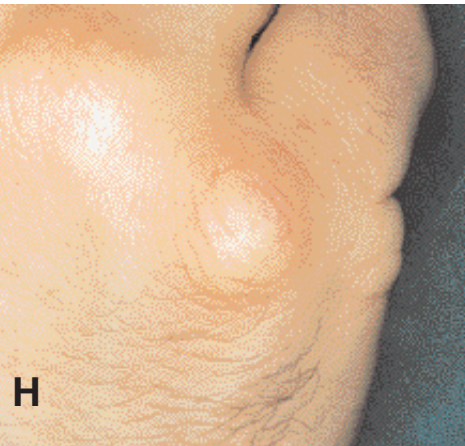
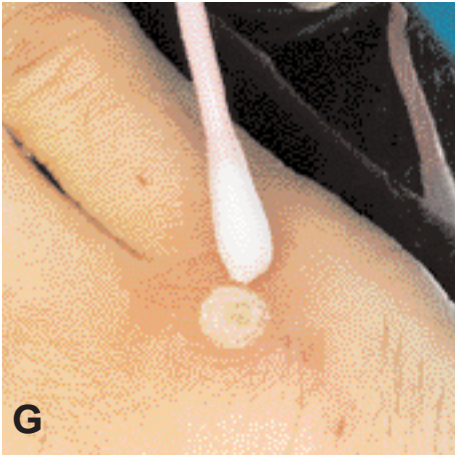
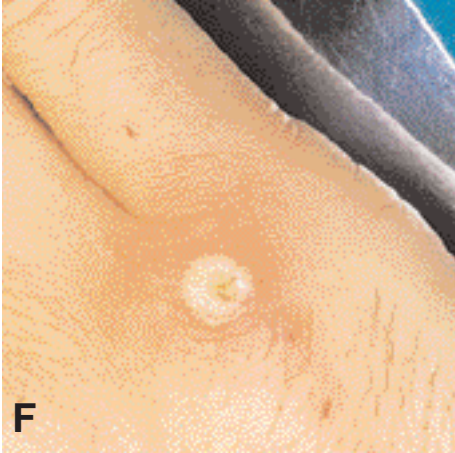
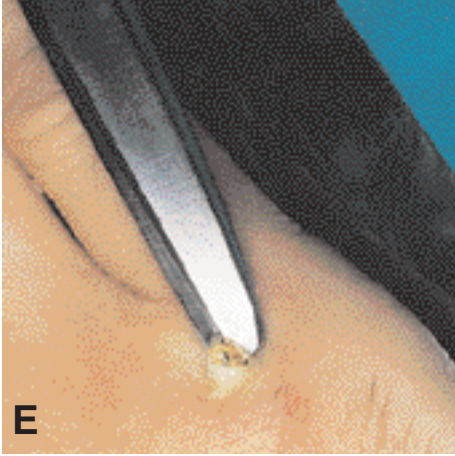


Fig. 32.1.3 A) Common wart. B) Local anaesthesia. C) Once the skin has been moistened, the tip of the activated electromaniple is slowly inserted into the wart. Programme data: **coagulation with microelectrodes, 10 Watts, EM 15** electromaniple. D) A small circular movement is carried out with the electromaniple, which remains activated and in contact with the wart until it becomes detached from the dermis . (see below)





E) Once the wart is completely detached from the dermis, it is removed with scissors. **F)** The absence of bleeding denotes that coagulation has been properly carried out. **G)** 15% trichloroacetic acid is applied. **H)** Result after 2 months.

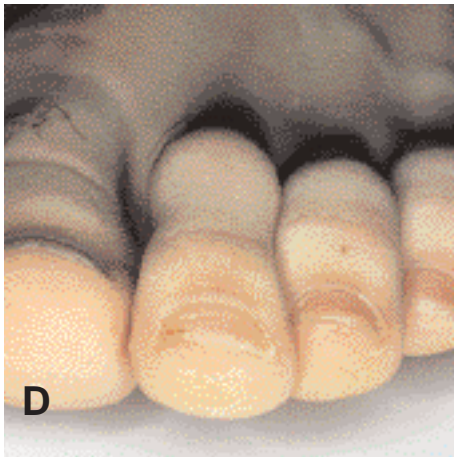
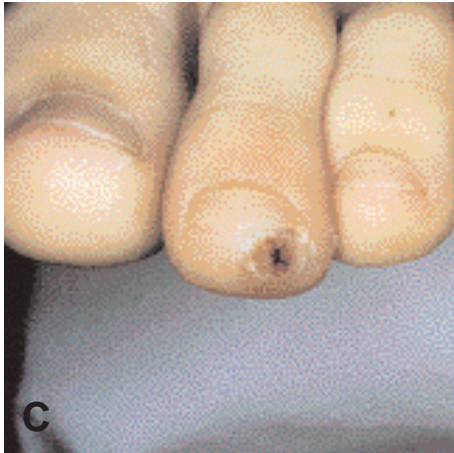
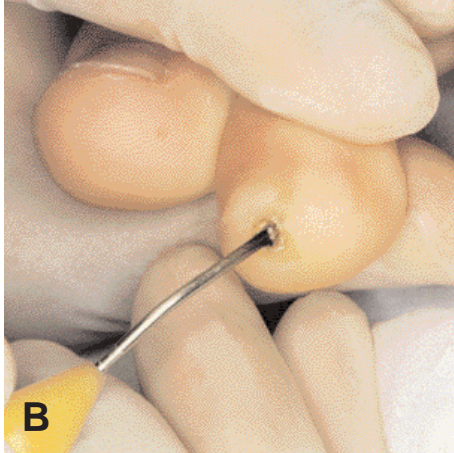
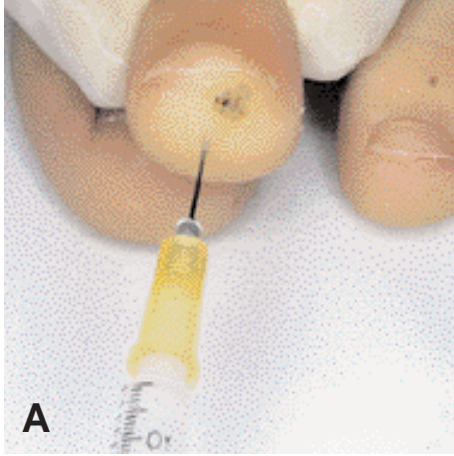


Fig. 32.1.4 **A)** Local anaesthesia without adrenaline. Injecting the tip of the finger incurs no risk of damaging the fine nerves of the third phalage. **B)** Once the skin has been moistened, the tip of the electromaniple slowly penetrates the wart and effects small circular movements. Programme data: **coagulation with microelectrodes, 10 Watts, EM 15** electromaniple. The procedure is completed by removing the wart with scissors and applying 15% trichloracetic acid. **C)** Healing takes place under the crust. **D)** Result.

32.2 Plantar Warts

Situated on the weight-bearing areas of the feet, plantar warts may be deep and may extend to the plantar aponeurosis.

They appear as characteristic keratotic lesions, of various dimensions, with a circular central core surrounded by a white keratotic edge. There is always considerable cornified tissue, which should be removed with a number 15 blade. This allows the precise extent of the wart to be seen. Removing the cornified tissue improves the electrical conductivity of the tissue. The procedure is carried out as described in the previous section (**Fig. 32.2.1**).

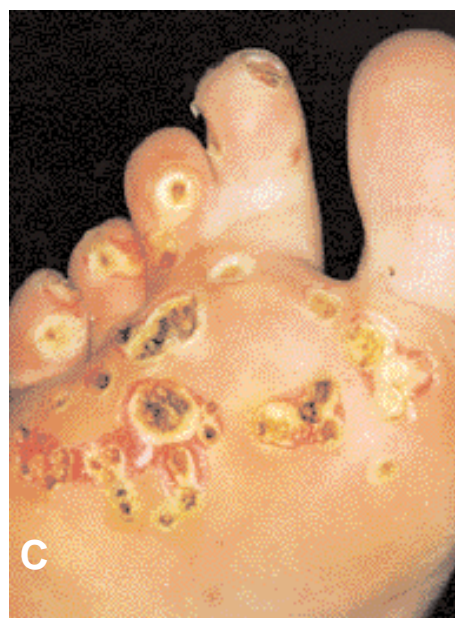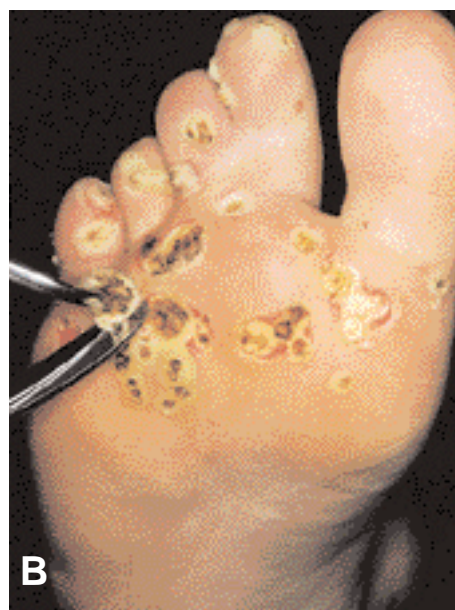
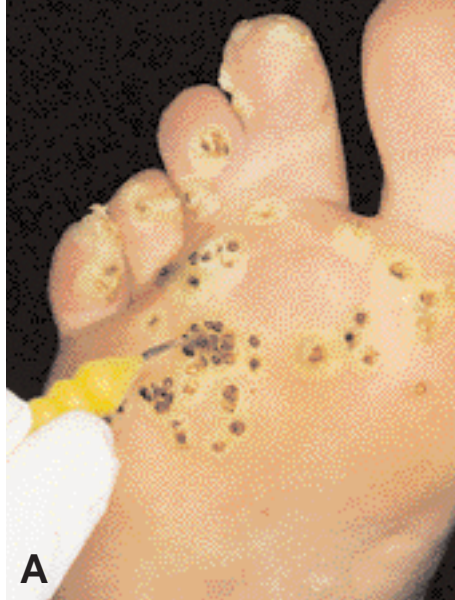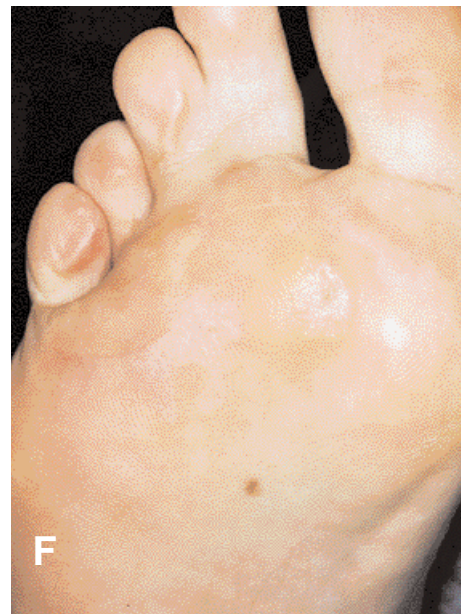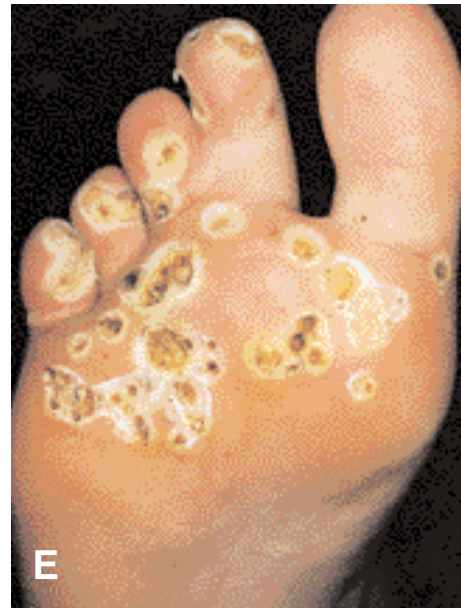


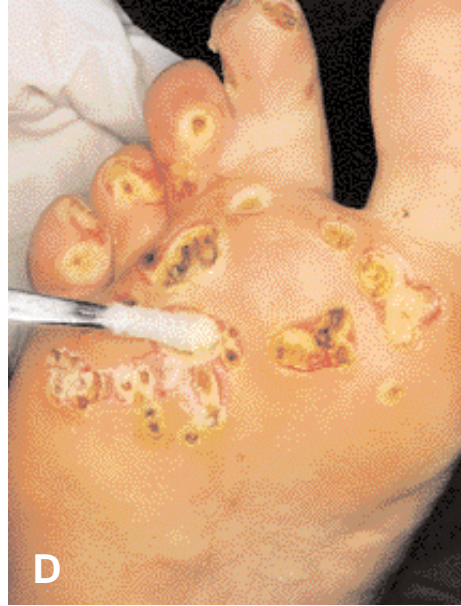Fig. 32.2.1 **A)** Plantar warts. Once the skin has been moistened, the tip of the activated electromaniple slowly penetrates the wart and effects small circular movements until the wart becomes detached from the dermis. Programme data: **coagulation with microelectrodes, 14 Watts, EM 15** electromaniple. Local anaesthesia. **B)** Once the warts are detached from the dermal plane, they are removed with scissors. **C)** The warts have been removed. All lesions have been treated. *(see below)*



D) 15% trichloroacetic acid is applied. **E)** The acid sterilises the treated area, making recurrence unlikely. **F)** Result a month after the crust has fallen off.

32.3 Small common Warts

Programme data

**Timed 9 hundredths of a second -
Coag microelectrodes - 50 Watts -
EM 15.**

Small common warts are eliminated without anaesthetic by means of a timed surgical emission.

The operating area of the intervention is disinfected and the patient's return electrode is placed on the skin. The operator sets the Timed apparatus to the timed mode, the emission time to **9 hundredths of a second** and the power to **50 Watts**.

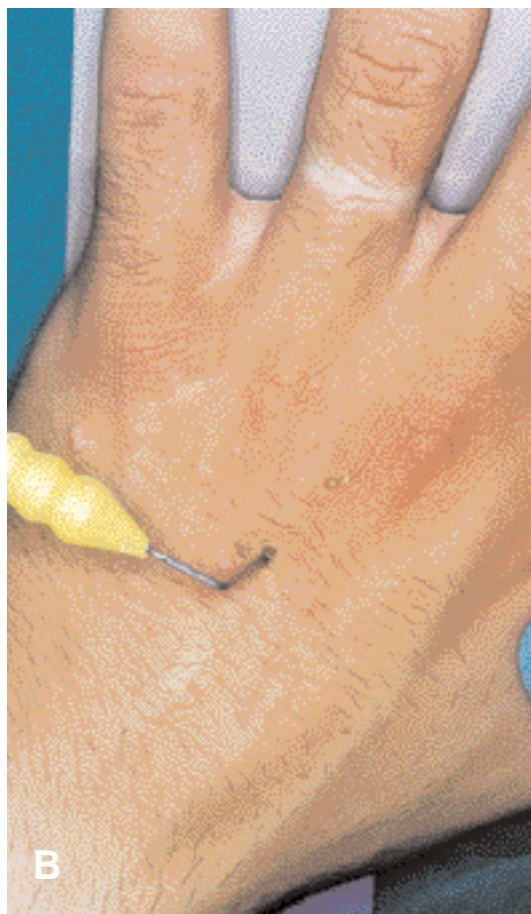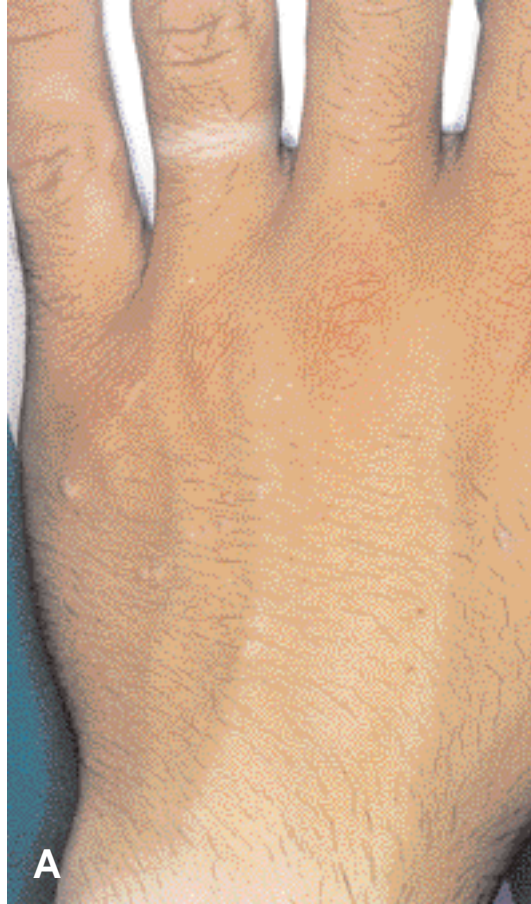The power must be high enough to destroy the wart with one emission.

An **EM 15** electromaniple is used. Before generating the timed emission, the operator places the tip of the electromaniple in contact with the wart and exerts slight pressure. In spite of the high power used in this procedure, it is helpful to moisten the skin to improve conduction of the current.

The current can then pass through the cornified layer covering the wart, which is only moderately conductive. The procedure may be completed by applying 15% trichloroacetic acid.

The patient is examined after the crust has fallen.

This technique allows rapid treatment of multiple small warts (**Fig. 32.3.1**).



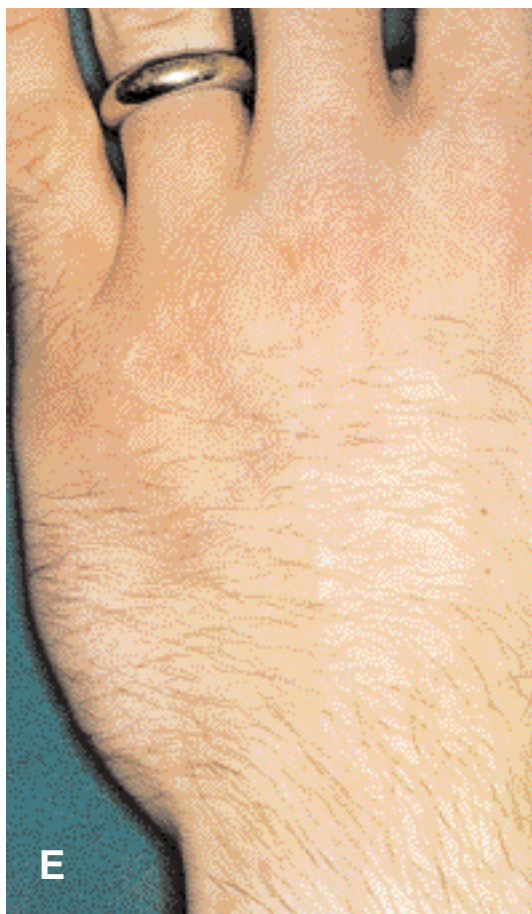
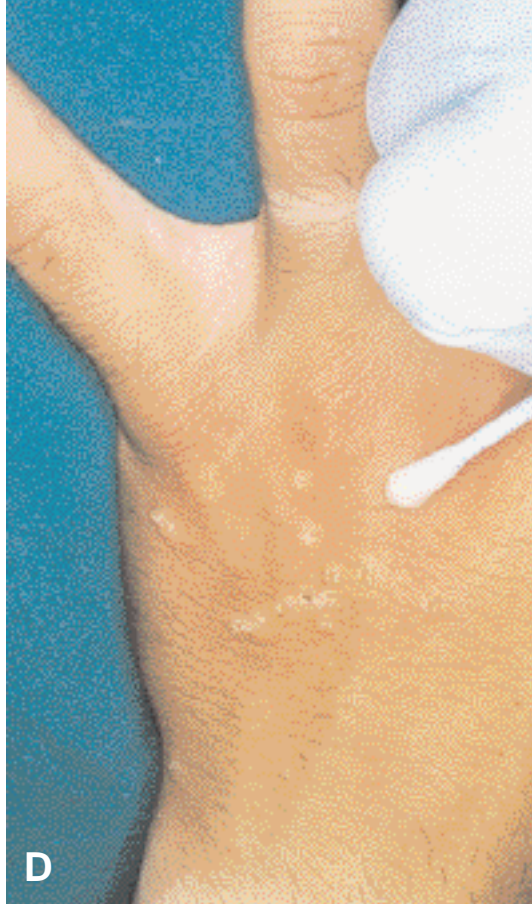
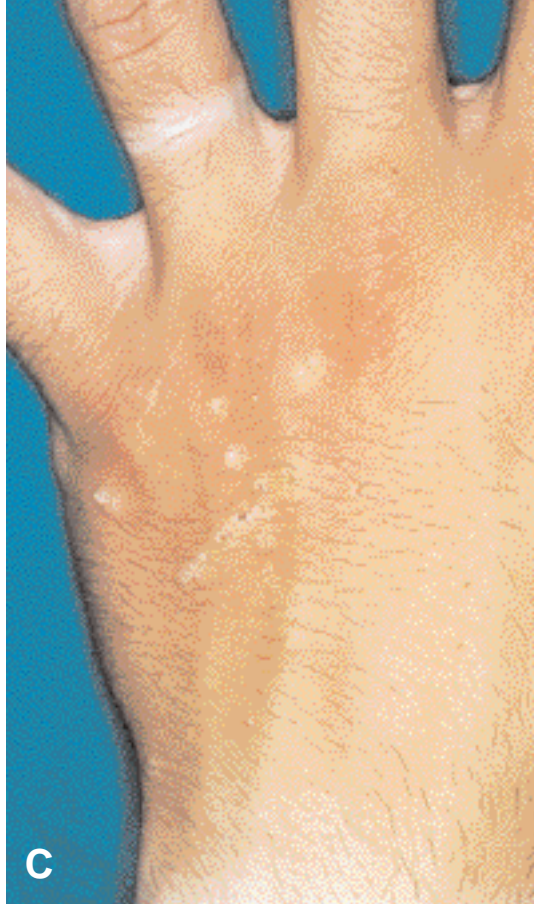Fig. 32.3.1 A) Multiple small common warts. B) Once the skin has been moistened, the tip of the electromaniple is pressed onto the wart and the timed emission is generated. Programme data: **coagulation with microelectrodes, 50 Watts, 9 hundredths of a second, EM 15** electromaniple. C) All the warts must be coagulated. D) 15% trichloroacetic acid is applied. E) Result.

32.4 Plane Warts

Programme data

Timed 25 hundredths of a second

- Coag microelectrodes - 5 Watts

- EM 15 .

Plane warts occur most frequently in children and female adults. They manifest themselves as numerous smooth superficial papules with a well-defined circular or polygonal border and rarely exceed 3 mm in diameter. They occur on the face, the backs of the hands and, less frequently, on the knees and elbows.

Plane warts on the face often regress spontaneously, and require delicate treatment if scar formation is to be avoided. It is also necessary to utilise the anti-viral effect of heat, with low power and a prolonged emission time.

Technique

The patient's return electrode is placed in contact with the skin, and the operating area disinfected.

An **EM 15** electromaniple is inserted and the Timed apparatus set to the timed mode, with an emission time **of 25 hundredths of a second**.

The device is set to **coagulation with microelectrodes** and the power to **4 or 5 Watts**. The skin is moistened with a gauze soaked in saline, to improve conductivity.

The treatment is carried out by placing the tip of the electromaniple in contact with each single wart and generating a timed emission.

There is no need to use a local anaesthetic solution, though an anaesthetic cream (Emla) may be applied if desired. In order to avoid scarring, the coagulation produced is very

superficial and the dermis is not breached. Only the superficial part of the wart needs to be coagulated (**Figs. 32.4.1-2**). It is sufficient to heat the formation .

For the treatment of locally recurring warts, a useful alternative to timed coagulation involves timed surgical de-epithelialisation of the lesion, followed by the application of 10% trichloroacetic acid.

The acid is neutralised by means of a bicarbonate solution immediately after frosting (whitening of the dermis).




Fig. 32.4.1 Coagulation must be superficial. The anti-viral effect of heat is utilised. The tip of the **EM 15** electromaniple is pressed against the plane wart before the timed emission is generated. The emission is of low power and long duration.

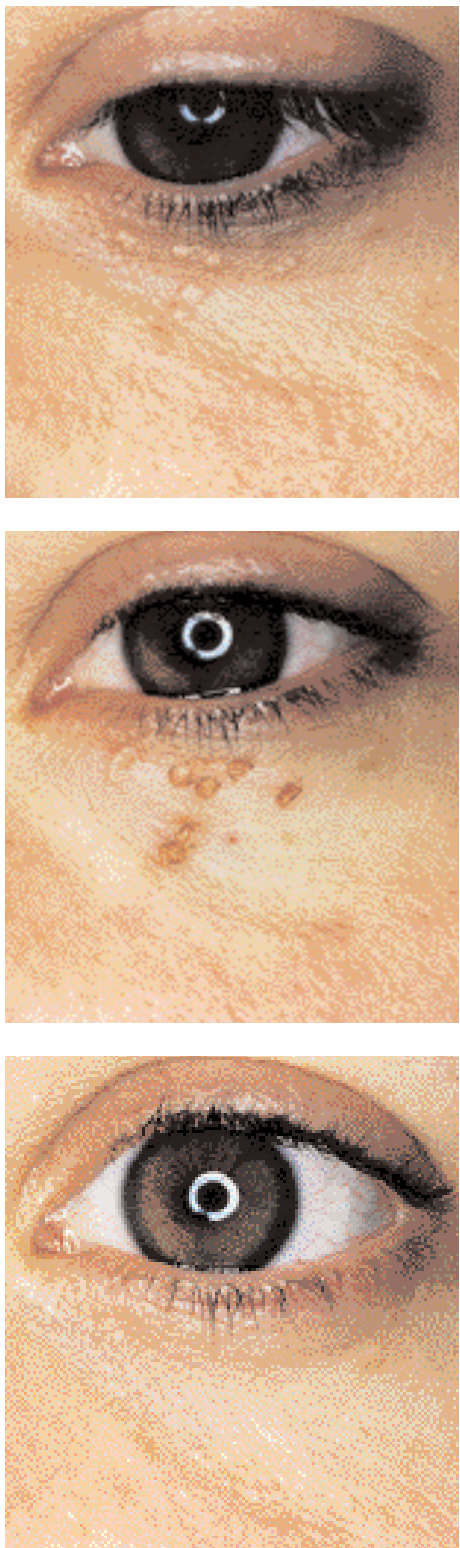

Fig. 32.4.2 Timed coagulation of plane warts. Programme data: **coagulation with microelectrodes, 5 Watts, 25 hundredths of a second, EM 15 electromaniple.**

33

TREATMENT OF CONDYLOMATA ACUMINATA

Programme data

**Direct - Coag microelectrodes -
10 or 14 Watts - EM 15.**

Various techniques may be used to eliminate viral warts of the mucosae, depending on their dimensions and location (Tab. 33.1).

The less severe forms may be eliminated under local or topical anaesthesia, but more extensive lesions on the genitals may require general or regional anaesthesia.

All infected areas should be treated.

The location of virally infected mucosae can be revealed by "acetowhiteening". A 5% acetic acid solution is applied to the mucosae for 2 to 5 minutes, thus revealing areas of viral infection otherwise difficult to identify.

Condylomata acuminata may also be found on extragenital mucous membranes.

Small lesions can be coagulated, or excised, using the cut or blend functions provided (**Fig. 33.0.1**).

The wound is sutured with absorbable suture material.

Alternatively, the condyloma may be cut tangentially to the skin surface and its base coagulated.

An **EM Yellow** electromaniple may be inserted into the wart and an emission of relatively low power, **10 or 14 Watts**, delivered for a relatively prolonged time, until coagulation is obtained (**Fig. 33.0.2**).

The electromaniple is inserted as many times as necessary to complete the coagulation of the base of the lesion (Au Y 1981). The bulk of the lesion may then be removed by means of the cutting function, followed by coagulation with an **EM 15** electromaniple.

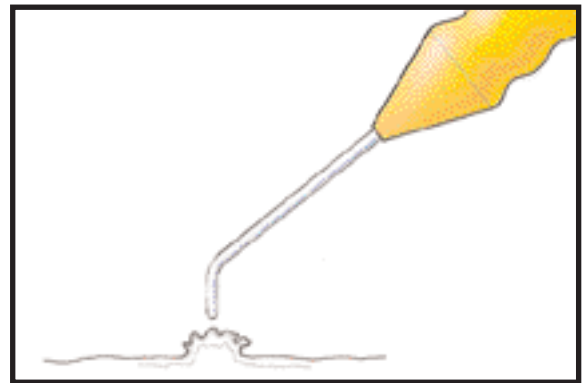


Fig. 33.0.1 Small condylomata acuminata are coagulated at **10 Watts** with the **EM 15** electromaniple.

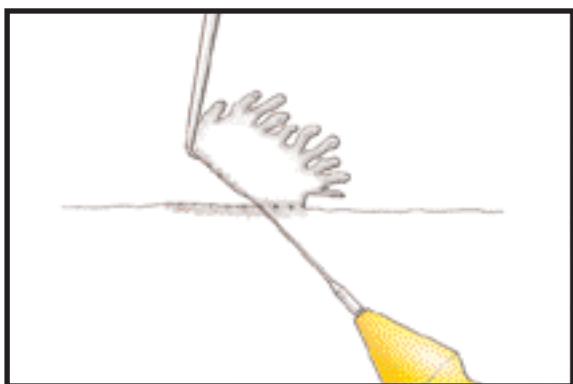
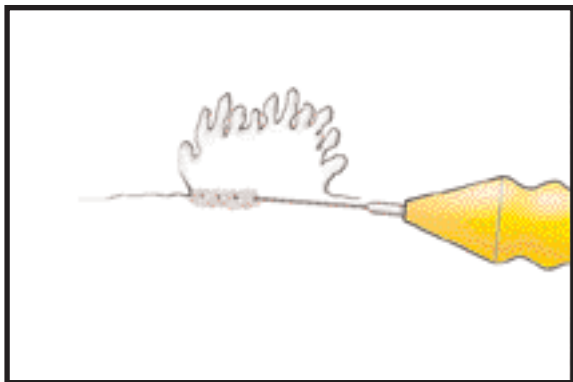
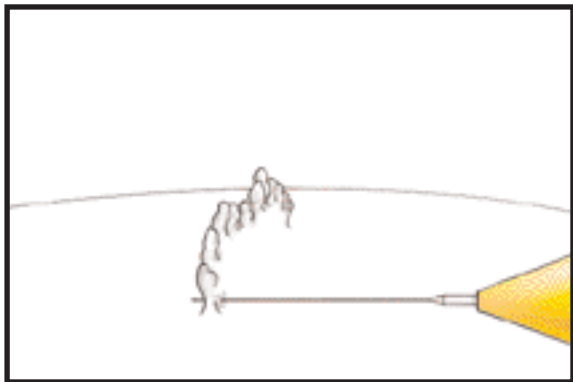


Fig. 33.0.2 Large condylomata acuminata are cut out or coagulated. One technique consists of carrying out a series of coagulations at the base of the viral formation before cutting (Au Y 1981).

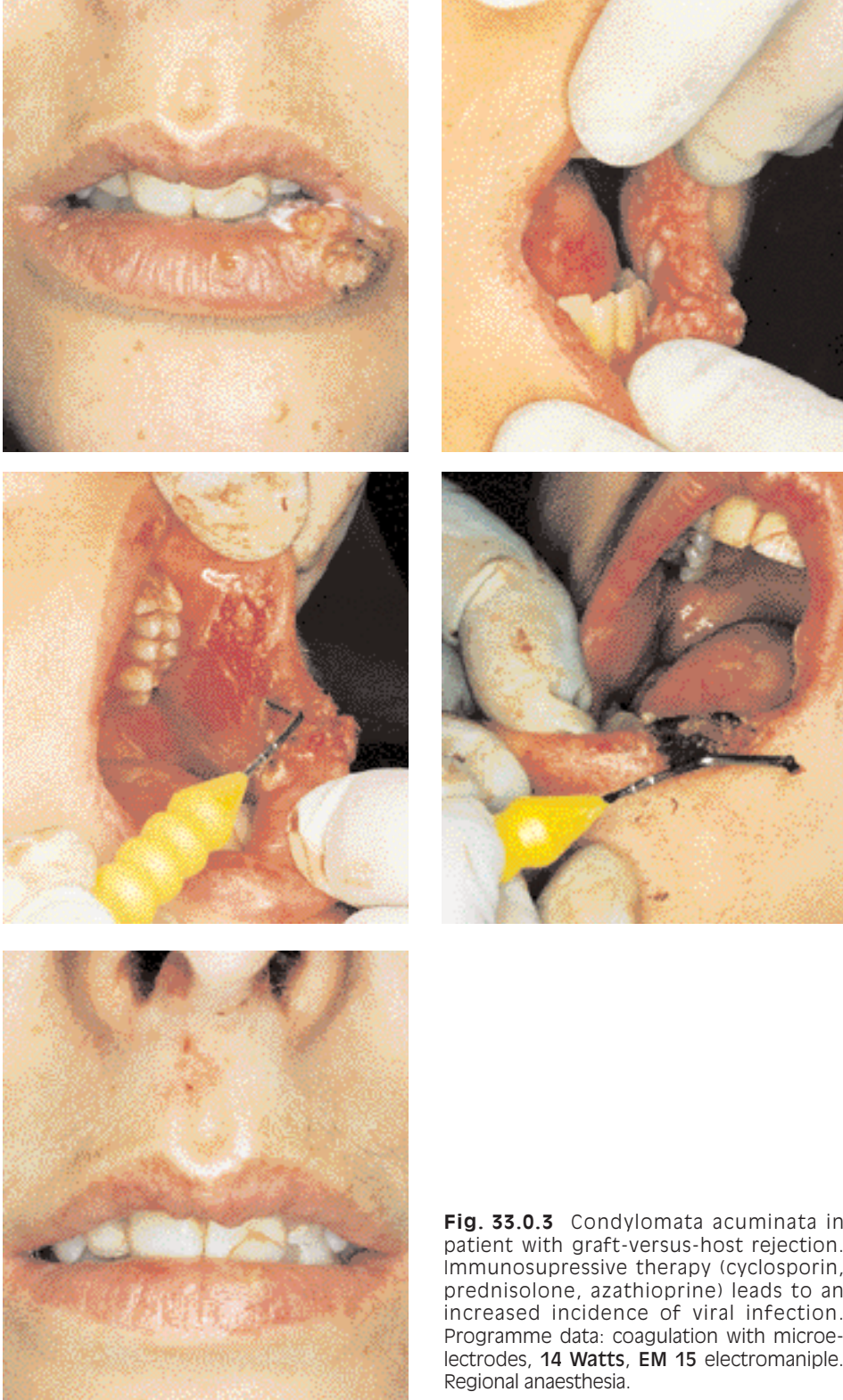


Fig. 33.0.3 Condylomata acuminata in patient with graft-versus-host rejection. Immunosuppressive therapy (cyclosporin, prednisolone, azathioprine) leads to an increased incidence of viral infection. Programme data: coagulation with microelectrodes, **14 Watts**, **EM 15** electromanipule. Regional anaesthesia.

As always, coagulation is carried out at low power to utilise the anti-viral effect of the heat.

The electromaniple must be held in contact with the condyloma acuminatum for as long as possible, execu-

ting small circular motions to allow adequate heating of the tissues (**Fig. 33.0.3**).

Immediately after the operation, antiviral drugs (alpha interferon) are injected or applied.

Tab. 33.1 Treatment of condylomata acuminata

Technique	Power	Electromaniple
Coagulation *	10 or 14 Watts	EM 15
Cutting	20 Watts	EM 10 Yellow
Cutting and Coagulation *	20 Watts	EM 10 Yellow
	14 Watts	EM 15
Coagulation * of base and Cutting	10 Watts	EM 10 Yellow
	20 Watts	EM 10 Yellow

* Coagulation with microelectrodes.

34

COAGULATION OF PYOGENIC GRANULOMAS

Programme data

**Direct - Coag microelectrodes -
38 Watts - EM 15.**

Pyogenic granulomas (**Fig. 34.0.1**) usually appear on the fingers or mucosae of the lips. They grow rapidly and, with few exceptions, consist of a single prominent dark red nodule, which is often ulcerated, surrounded by an epidermal collar.

These friable lesions, which bleed easily and cause considerable inconvenience, may be eliminated with timed surgery.

The skin is cleansed and a local or regional anaesthetic given. The operator sets the Timed apparatus to the direct mode, in which emission time is controlled directly with the pedal. The function is set to **coagulation with microelectrodes** and the power to **27 or 38 Watts**. An **EM 15** electromaniple is used. During the procedure there may be slight bleeding, which stops when the lesion is completely coagulated (**Fig. 34.0.2**).

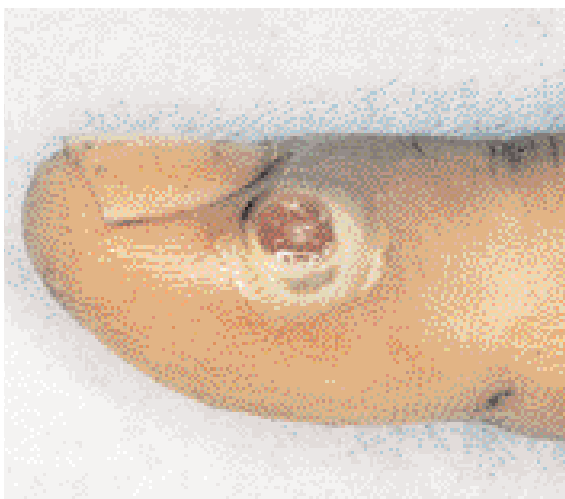


Fig. 34.0.1 Pyogenic granuloma.

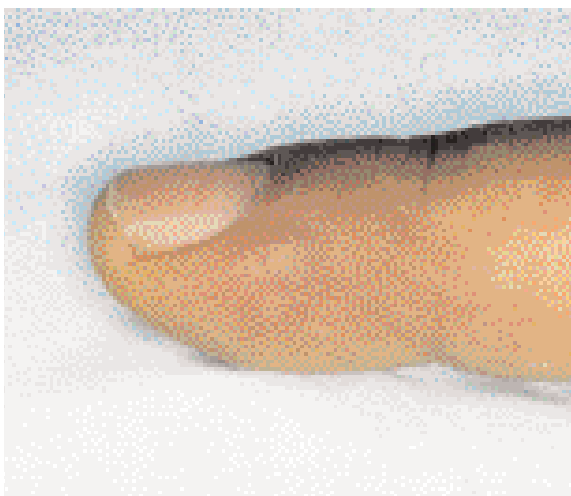
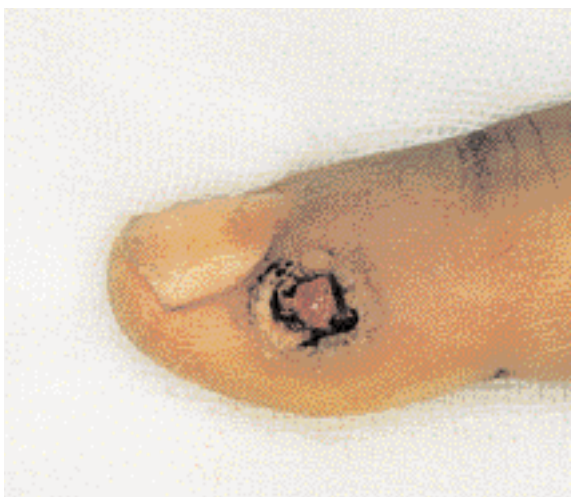
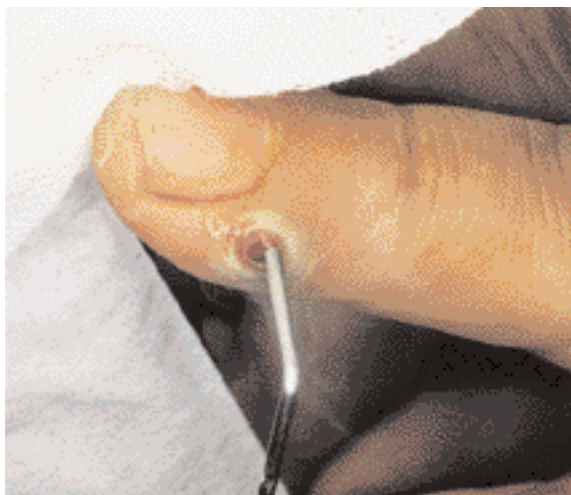
Fig. 34.0.2 Programme data: coagulation with microelectrodes, 38 Watts, EM 15 electromaniple. Digital ring block anaesthesia.

35

VAPORISATION OF RUBY ANGIOMAS

Programme data

**Timed 9 hundredths of a second -
Coag microelectrodes - 38 or 50
Watts - EM 15**

Ruby angiomas (also known as Campbell de Morgan spots) (**Fig. 35.0.1**) are small vascular formations

which do not empty under pressure. They do not usually exceed 4 mm in diameter, but may reach 2 cm in elderly people. Almost always multiple, they are situated mainly on the trunk and in areas of the limbs. Histologically, they consist of a convolution of newly-formed capillaries.

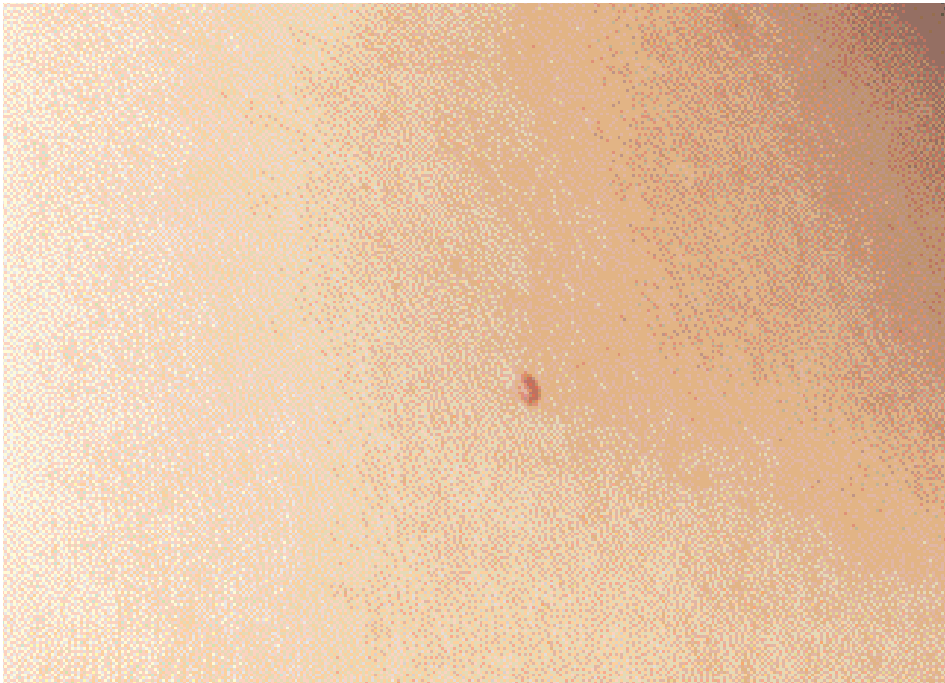

Fig. 35.0.1 Ruby angioma.

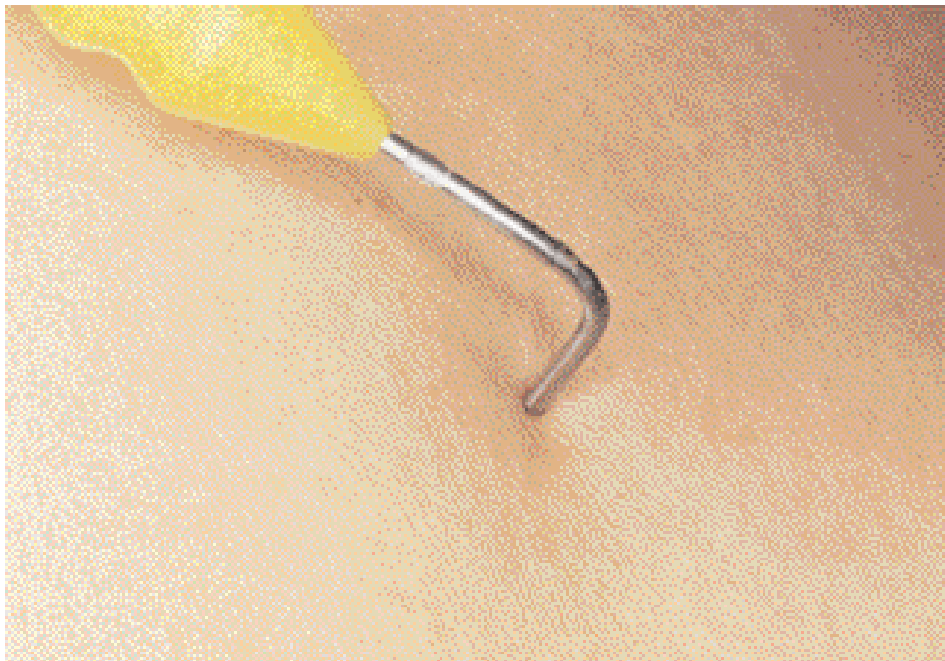


Fig. 35.0.2 The tip of the electromaniple is pressed onto the ruby angioma before generating the emission. Programme data: **coagulation with microelectrodes, 50 Watts, 9 hundredths of a second, EM 15** electromaniple.

After positioning the patient's return electrode and disinfecting the skin, the operator sets the Timed apparatus to the timed mode, the emission time to **9 hundredths of a second**, the function to **coagulation with microelectrodes** and the power to **38 or 50 Watts**. An **EM 15** electromaniple is used.

The operator presses the tip of the electromaniple onto the ruby angioma and generates the emission.

The high power and brief emission time completely destroy the lesion, without burning the surrounding tissue (**Fig. 35.0.2**). If the ruby angioma is of a greater diameter than the electromaniple, further emissions are required.

The procedure is rapid and does not require anaesthetic (**Fig. 35.0.3**).

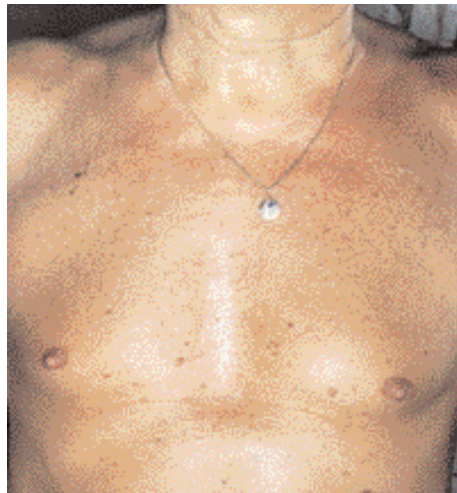
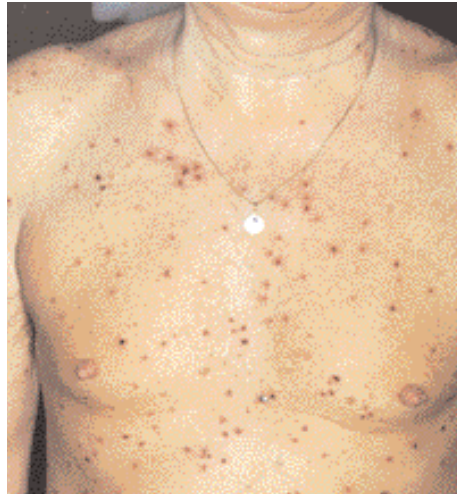
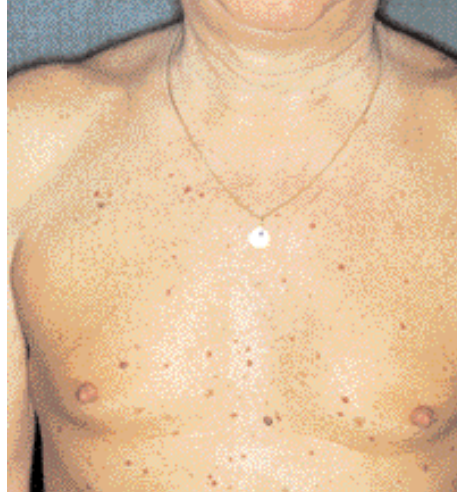
Fig. 35.0.3 All of the ruby angiomas present (around 400) were eliminated in one sitting. Programme data: **coagulation with microelectrodes, 38 Watts, 9 hundredths of a second, EM 15** electromaniple.

Large ruby angiomas (greater than 1 cm) can be coagulated with a direct emission, under local anaesthesia (**Fig. 35.0.4**).

For the elimination of puntiform ruby angiomas, see section 37.

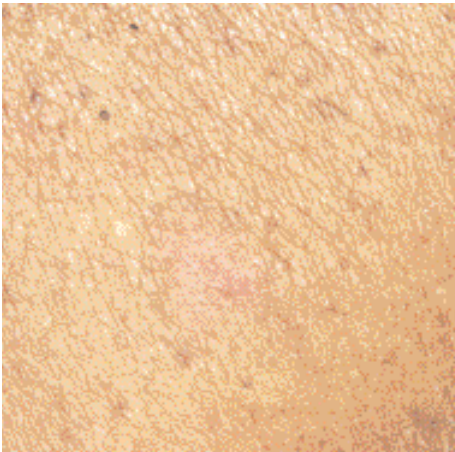
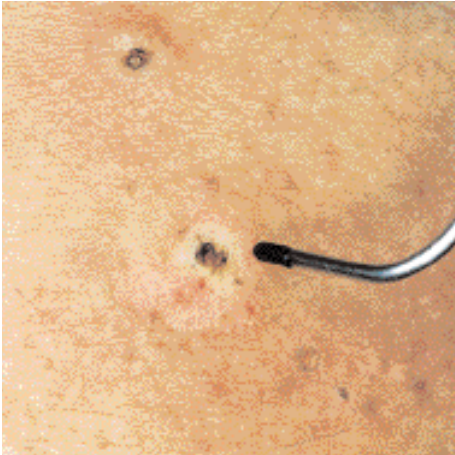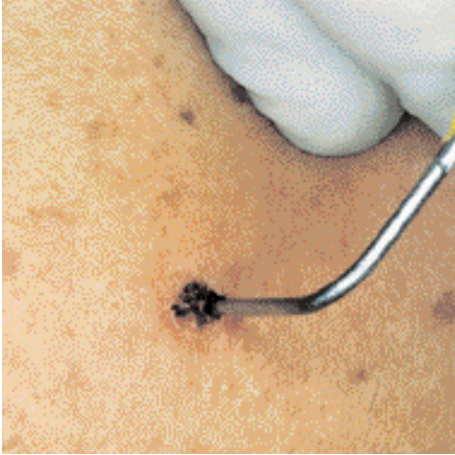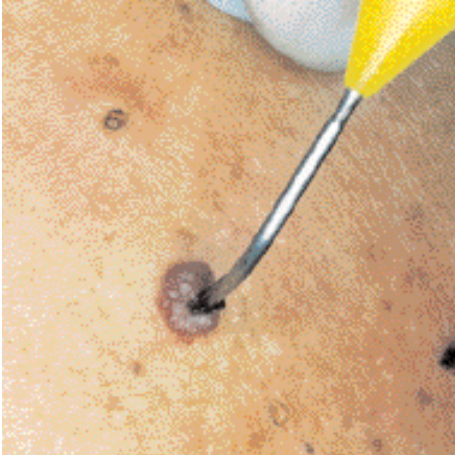


Fig. 35.0.4 Large ruby angiomas are coagulated with an emission time controlled directly by the operator by means of the pedal. Programme data: **coagulation with microelectrodes, 27 Watts, EM 15** electro-manipule. Local anaesthesia.

36

VAPORISATION OF SMALL NON-PEDUNCULATED LESIONS

Programme data

**Timed 9 hundredths of a second
Coag microelectrodes - 38 or 50
Watts - EM 15.**

Small non-pedunculated benign lesions, from 1 to 3 mm in diameter (adenoma sebaceum, condylomas,

fibromas, molluscum contagiosum, xanthomas, trichoepitheliomas (**Fig. 36.0.1**), xanthelasma, sebaceous hyperplasia, etc) are amenable to timed surgical treatment and may be vaporised without anaesthesia by appropriately programming the power and emission time (**Fig. 36.0.2-4**).

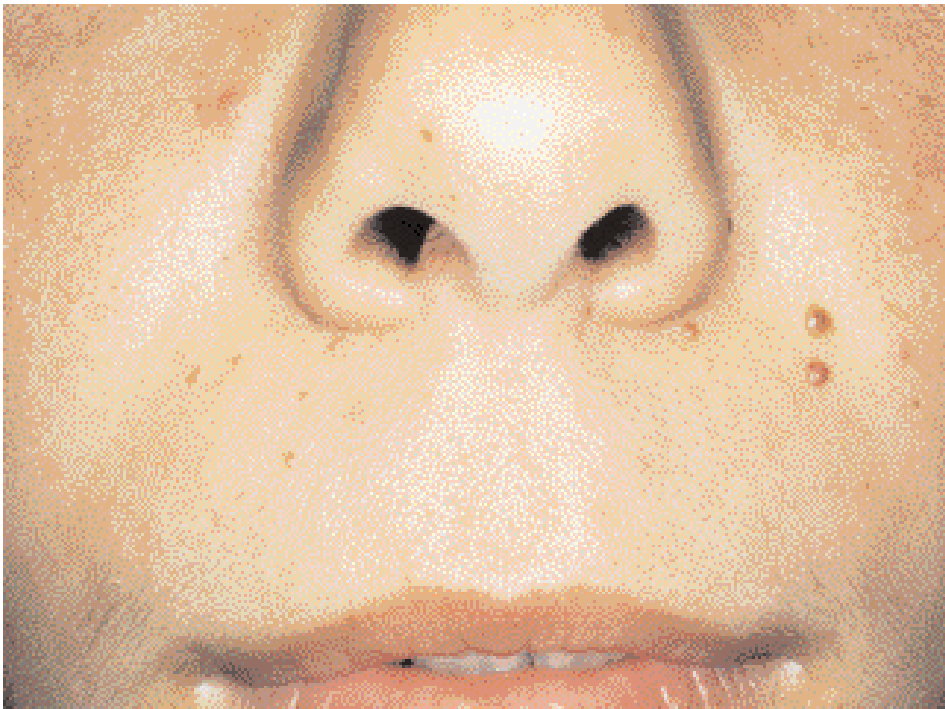

Fig. 36.0.1 Trichoepitheliomas.

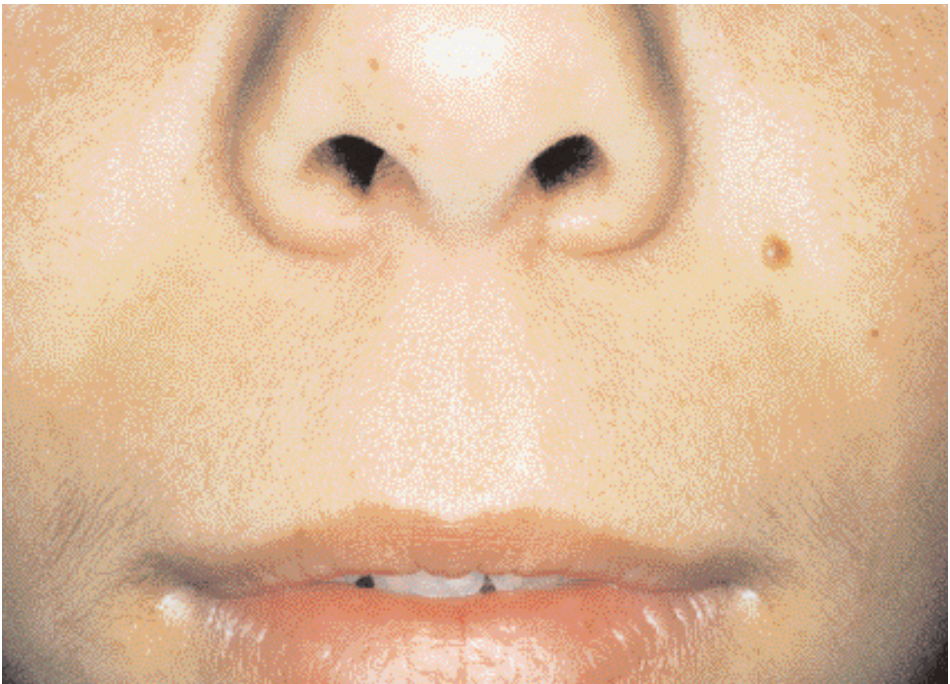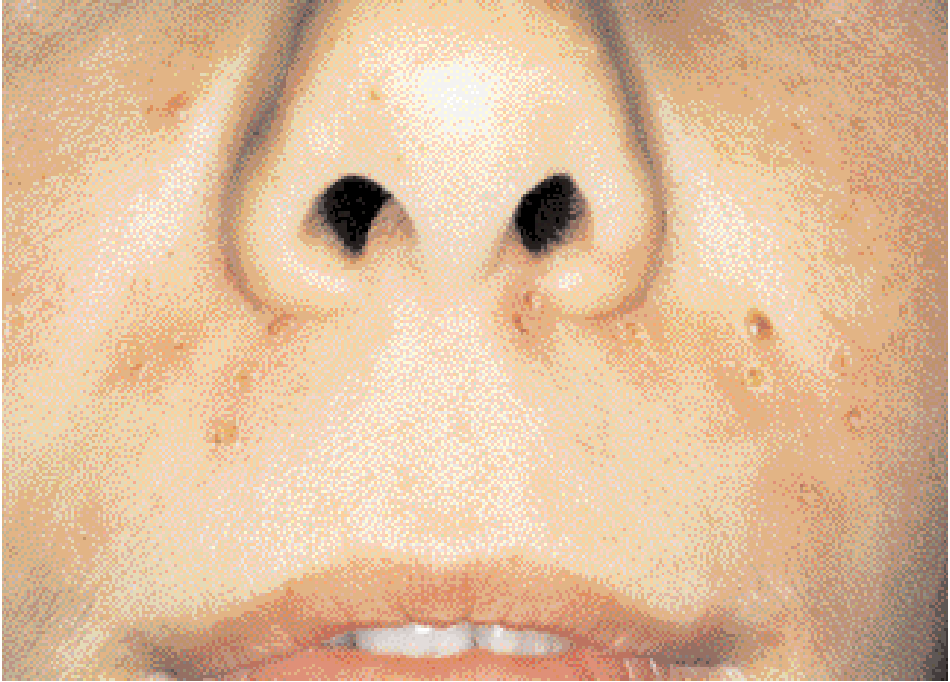


Fig. 36.0.2 Timed coagulation. Programme data: **coagulation with microelectrodes, 38 Watts, 9 hundredths of a second, EM 15** electromaniple. It is important not to coagulate any naevi that may be present in the area.

After positioning the patient's return electrode and disinfecting the skin, the operator sets the Timed apparatus to the timed mode, emission time to **9 hundredths of a second**, the function to **coagulation with microelectrodes** and the power to **38 or 50 Watts**. An **EM 15** electromaniple is used and the tip is placed on the lesion before generating the timed emission.

In the case of multiple small neoformations, a **pulsed** emission can be used, **pulsed 5/29 hundredths of a second**, in the **direct** mode.

Programming of a high power for a brief time is particularly suited to the treatment of deeply-rooted benign lesions, sebaceous hyperplasia and angiofibromas. If the lesion occupies the full thickness of the skin, it must be surgically removed by timed or slow pulsed cutting; the wound may then be sutured or left to heal spontaneously. With small lesions of viral origin and a small corneous component, the anti-viral effect of the heat is utilised by programming a low power and long emission time (see section 31.4).

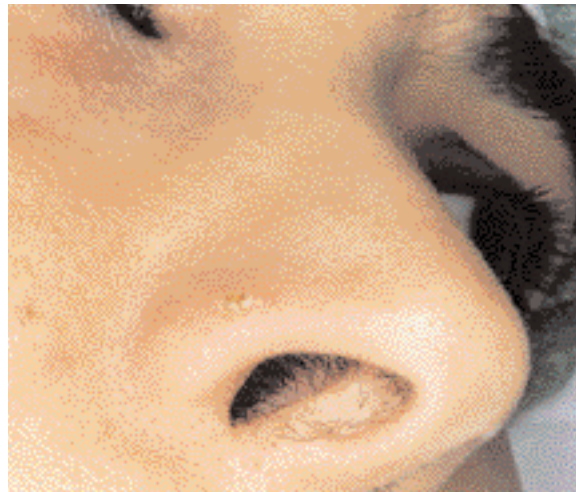
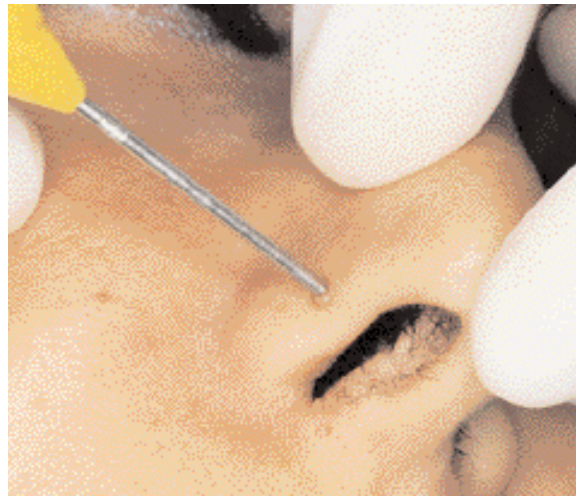
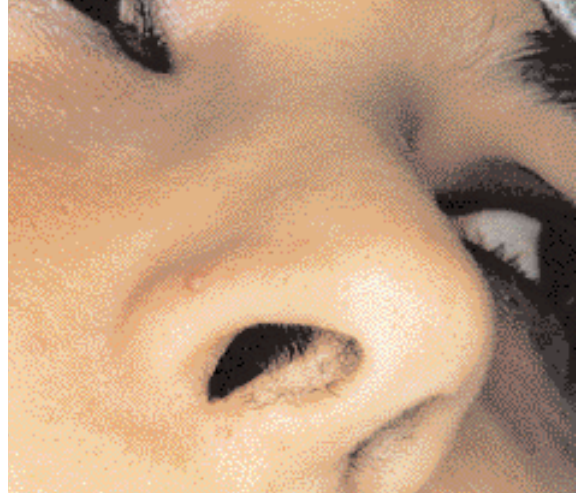Fig. 36.0.3 Fibrous papules of the nose. Programme data: **coagulation with microelectrodes, 38 Watts, 9 hundredths of a second, EM 15** electromaniple. Two timed emissions were carried out, repositioning the tip of the electromaniple over the lesion until coagulation was complete.

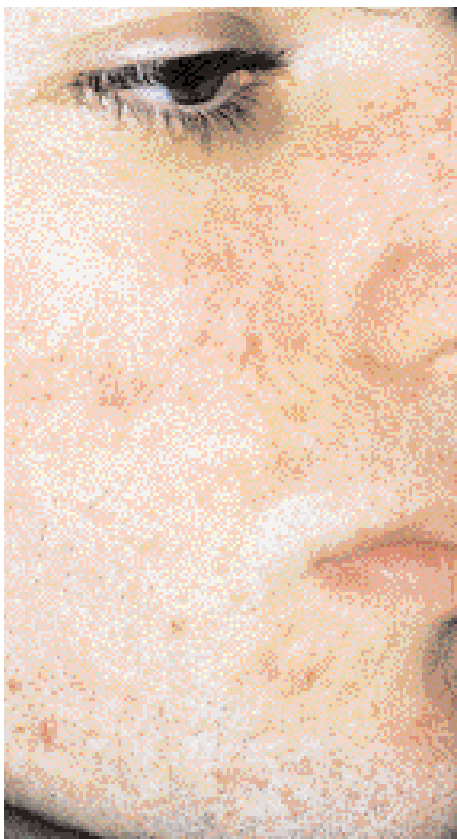
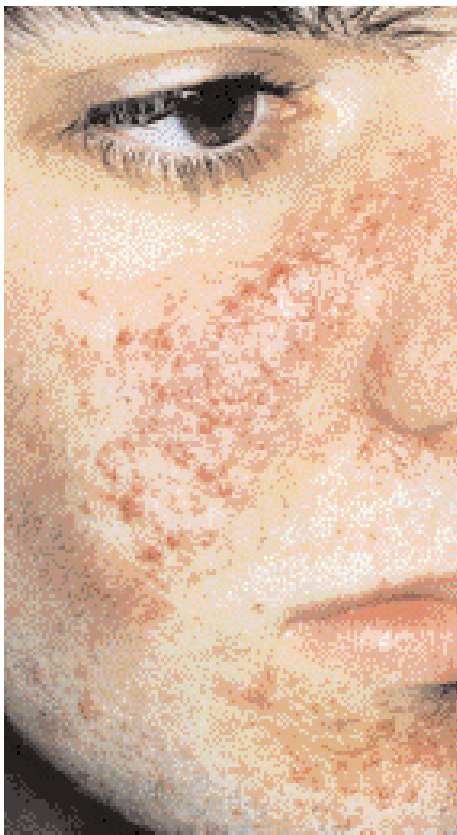
Fig. 36.0.4 Bourneville's disease. The angiobromas have been eliminated by means of a high-power timed emission. Programme data: coagulation with microelectrodes, 50 Watts, 9 hundredths of a second, EM 15 electromaniple. Local anaesthesia. Results after two sittings.

37

COAGULATION OF VERY SMALL LESIONS

Programme data

Timed 30 hundredths of a second - Coag microelectrodes - 7 Watts - EM 10 Yellow.

Punctiform ruby angiomas, fibromas which cannot be grasped with forceps, very small keratoses, microcysts of the lower eyelid and all other extremely small lesions (less than 1 mm in diameter) can be coagulated with a timed emission of low power and long duration, following insertion of the tip of an **EM 10 Yellow** electromaniple (**Fig. 37.0.1**).

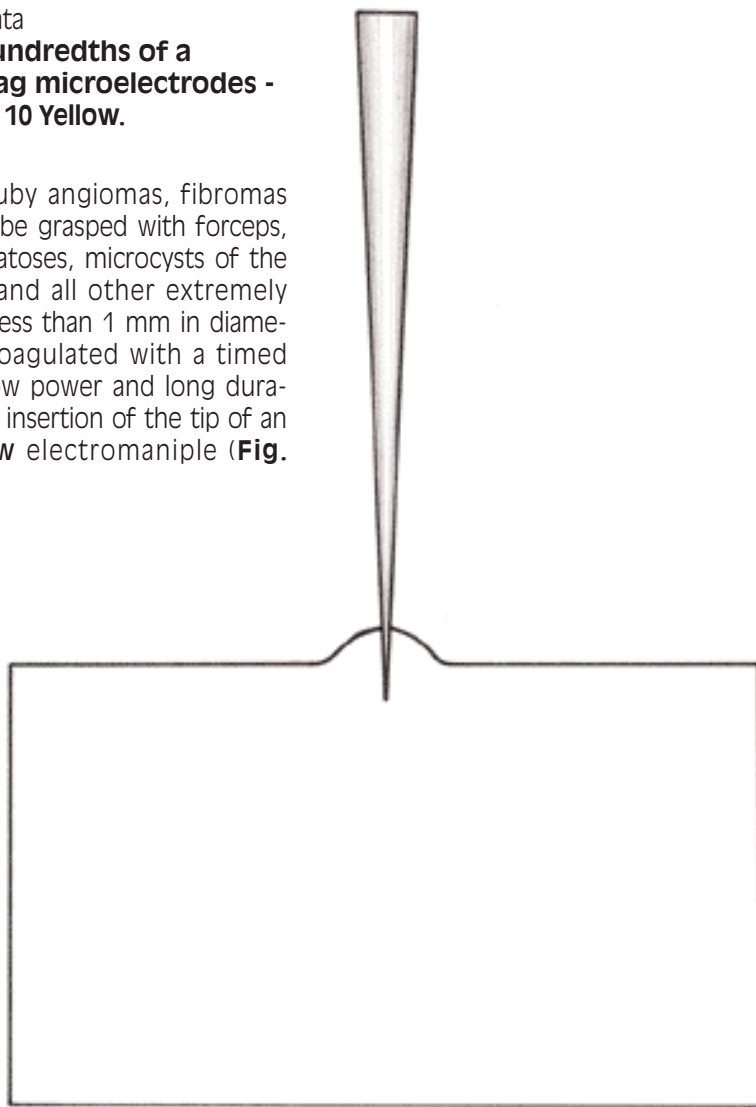


Fig. 37.0.1 Extremely small lesions are eliminated by inserting the point of the **EM 10 Yellow** electromaniple into them and generating a timed emission.

After positioning the patient's return electrode and disinfecting the operating field, the operator sets the Timed apparatus to the timed mode (emission from **15 to 99 hundredths of a second**), the function to **coagulation with microelectrodes** and the power to **7 Watts**; an **EM10 Yellow** electromaniple is used. Insertion of the point is facilitated by the emission. Low power and long emission time allow the heat to spread outside the electro-

maniple tip and thus coagulate the lesion (**Fig. 37.0.2**).

Another option is to use an **EM 10 Black** electromaniple at **20 or 27 Watts** and **9 hundredths of a second** (L. Montesana).

Cutaneous infections such as boils and folliculitis may also be treated in this way; the heat generated by the high frequency current has a sterilising action.

Very small neoformations are excised by means of slow pulsed cutting.

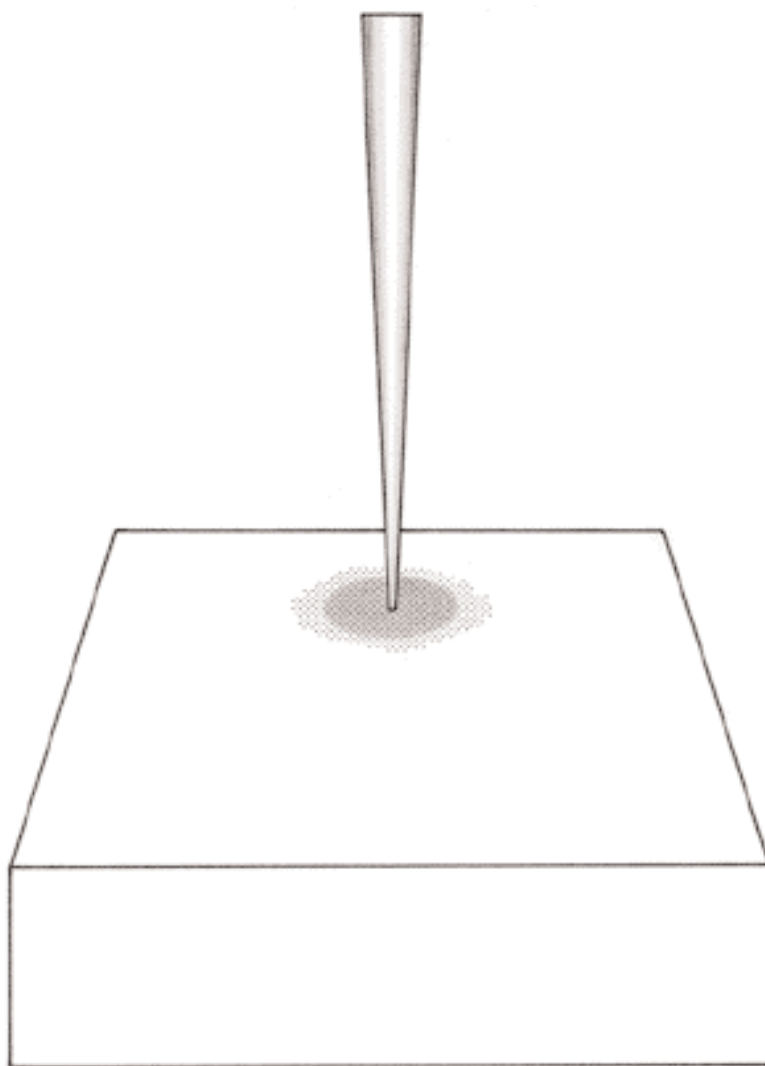


Fig. 37.0.2 The timed emission is of low power and long duration.

38

COAGULATION OF XANTHELASMAS

Programme data

**Direct - Coag microelectrodes -
20 or 27 Watts - EM 15.**

Xanthelasmas are fatty deposits commonly seen on the eyelids (**Fig. 38.0.1**).

Occasionally, especially when found elsewhere on the skin, they are a manifestation of underlying abnormalities of the lipid metabolism. These lesions may be removed by means of timed or pulsed cutting or treated with coagulation (**Fig. 38.0.2**).

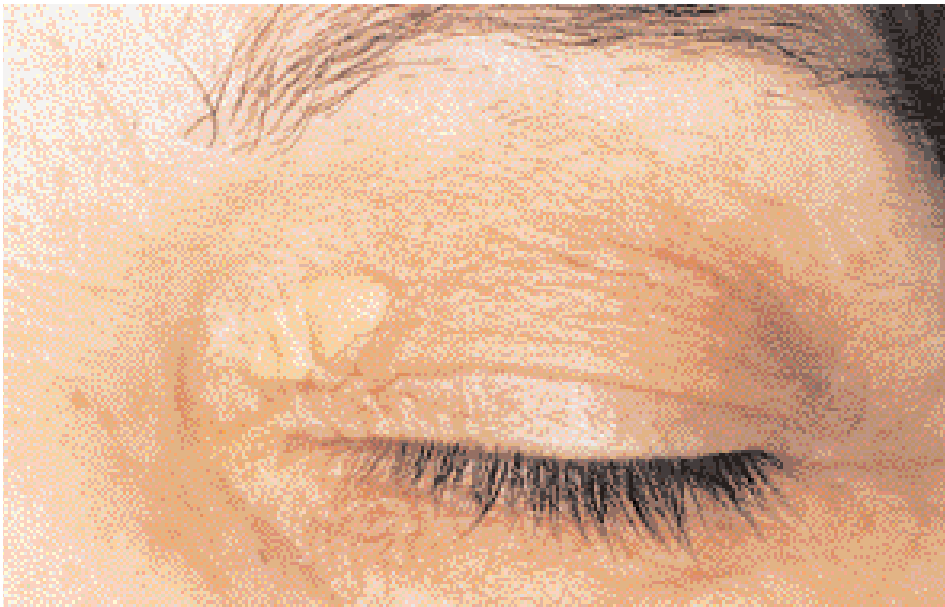

Fig. 38.0.1 Xanthelasma.

After positioning the patient's return electrode and disinfecting the skin, the operator injects local anaesthetic and sets the Timed apparatus to the

direct mode, in which emission time is controlled with the pedal, and the function to **coagulation with microelectrodes**.

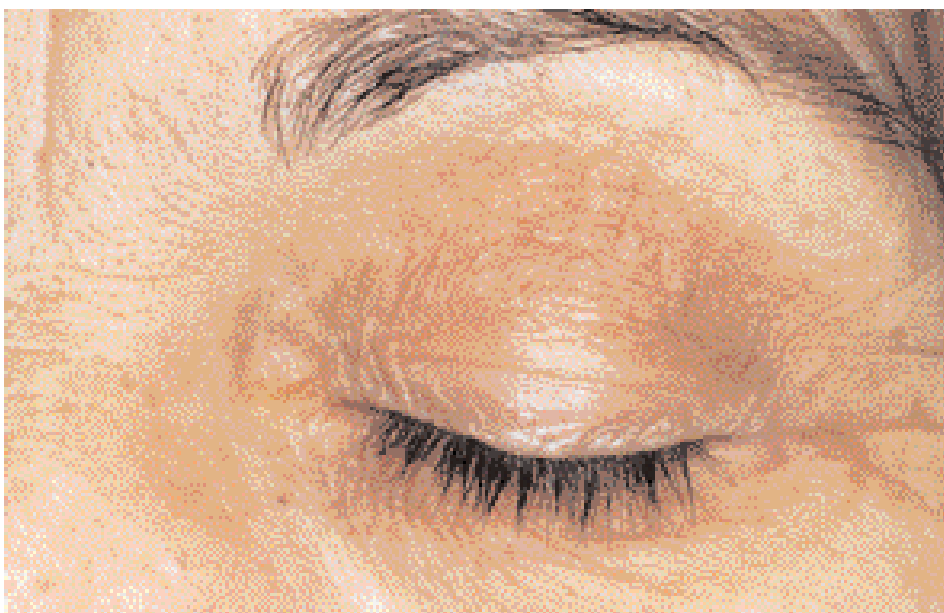
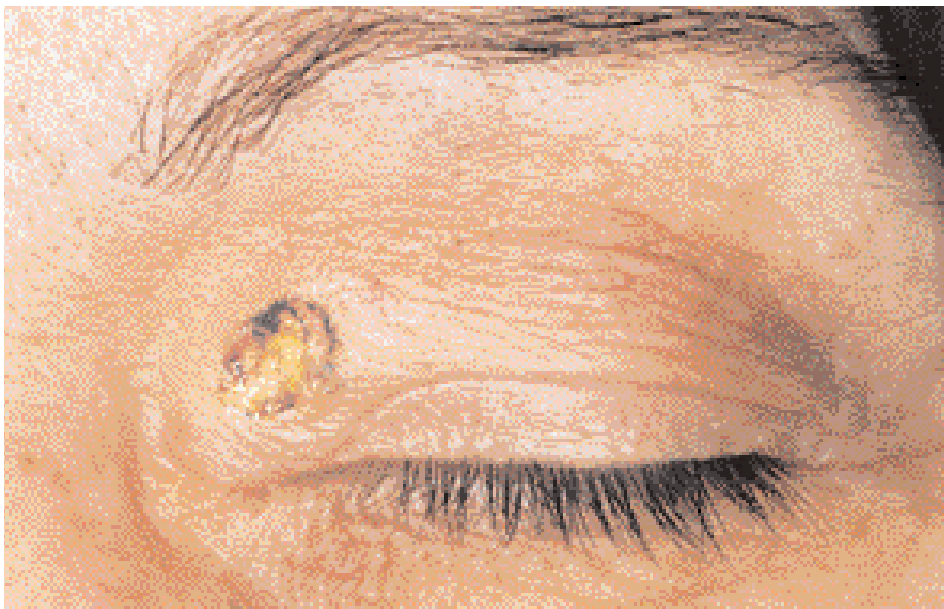


Fig. 38.0.2 Programme data: **coagulation with microelectrodes, 27 Watts, EM15** electro-manipule. Local anaesthesia. Results after one treatment session.

An **EM 15** electromaniple is inserted and the power is set to **14 Watts**; the power may then be increased to **20** or **27 Watts** if necessary. Each xanthelasma is gently coagulated,

without damaging the surrounding healthy tissue, until an eschar is formed which follows the edges of the lesion perfectly. Coagulation must not involve the entire thickness of

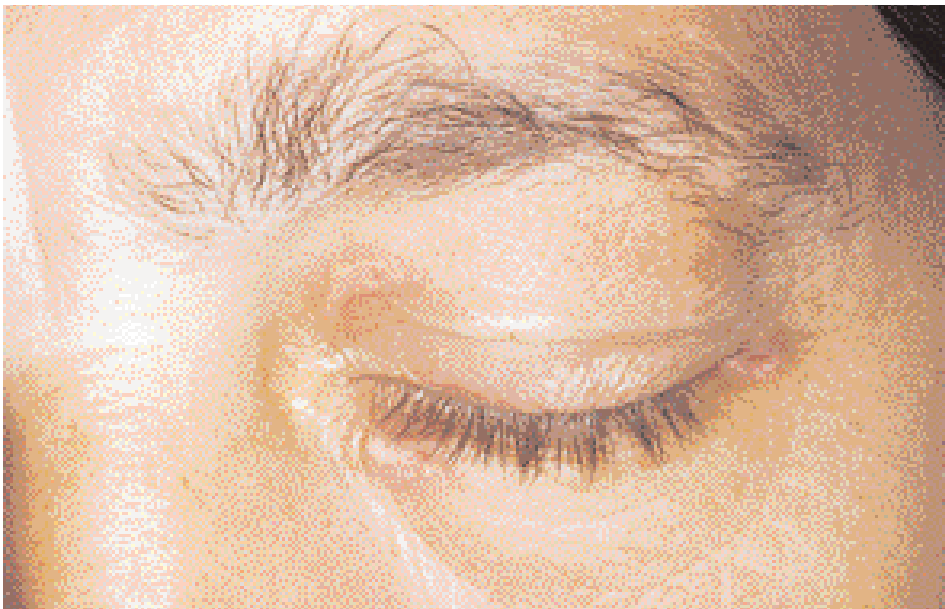
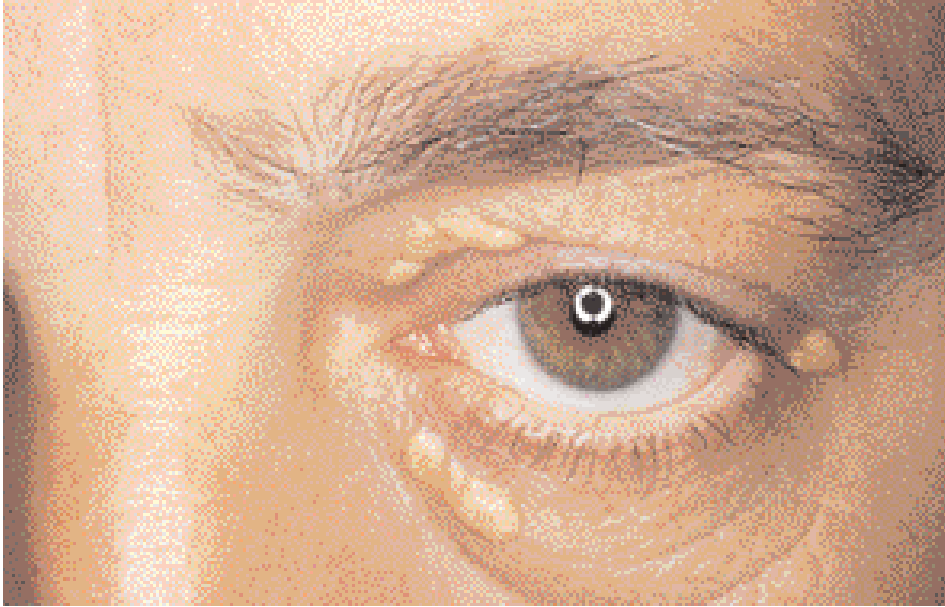
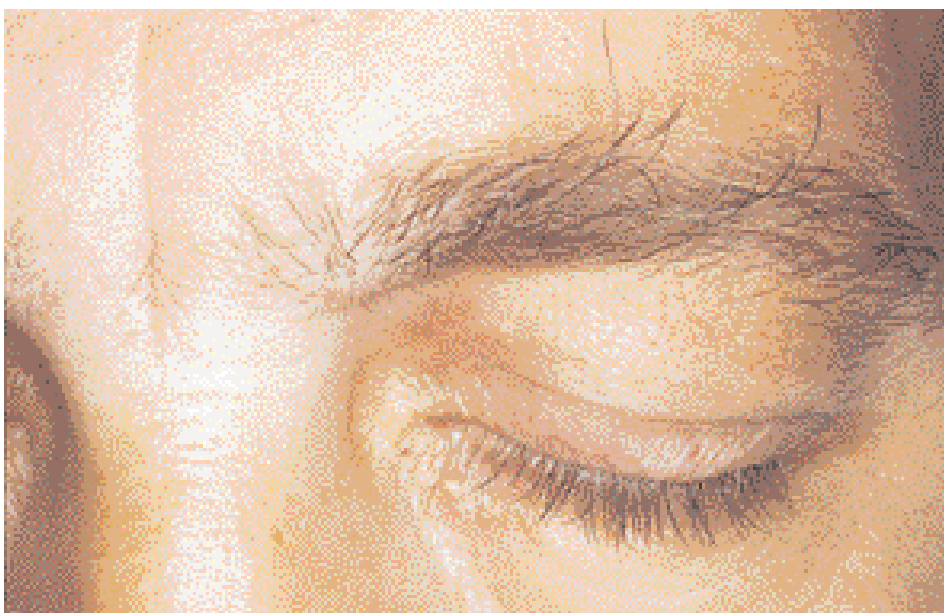
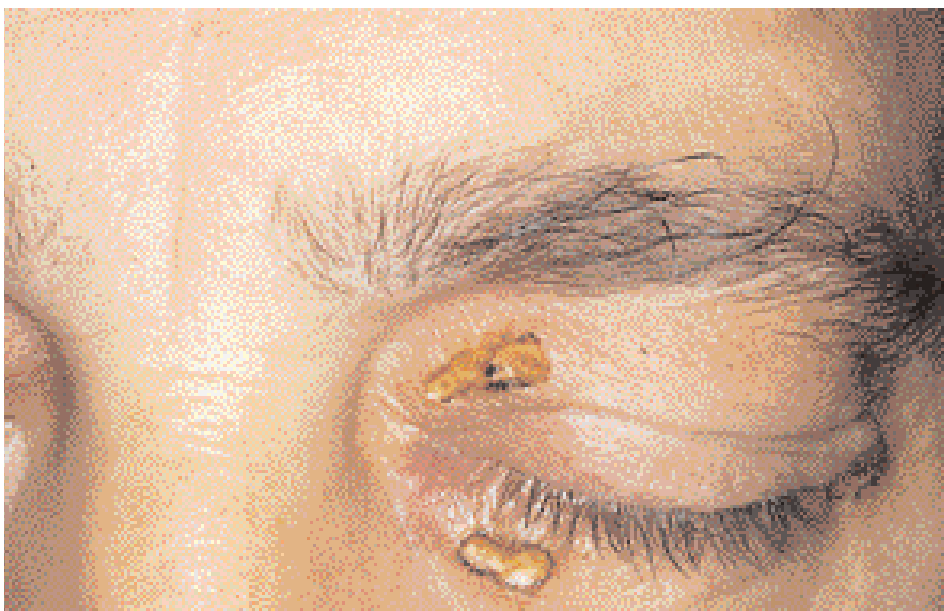
Fig. 38.0.3 Coagulation of xanthelasma, a recurrence following surgical excision. (see over)

the skin. In the post-operative period the patient applies a fine layer of antibiotic ointment. Healing is rapid and problem-free.

Re-epithelialisation continues under

the crust, thus avoiding retraction of the skin of the eyelid. One or two months later, the operator treats any residual xanthelasma fragments (**Fig. 38.0.3**).



Results after the first session. Result after the second coagulation session, following the first by one month. Programme data: **coagulation with microelectrodes, 27 Watts, EM 15** electromanipule. Local anaesthesia.

39

TREATMENT OF KERATOSES

Seborrhoeic keratoses are benign localized neoplastic proliferations of basaloid keratinocytes associated with hyperkeratosis and hyperpigmentation.

They appear as small light yellow/brown papules of circular or oval shape. They grow slowly up to 2-3 cm diameter, are well delineated and may be single or multiple, numbering hundreds in some patients. They are

common on the trunk in the elderly and may occur on the face.

One of three treatment techniques may be followed according to whether the keratoses are large, medium sized or small and multiple. For the treatment of large senile lentigines, see section 26.

If the lesion is extensive, the treatment is carried out under local anaesthesia (**Fig. 39.0.1**).

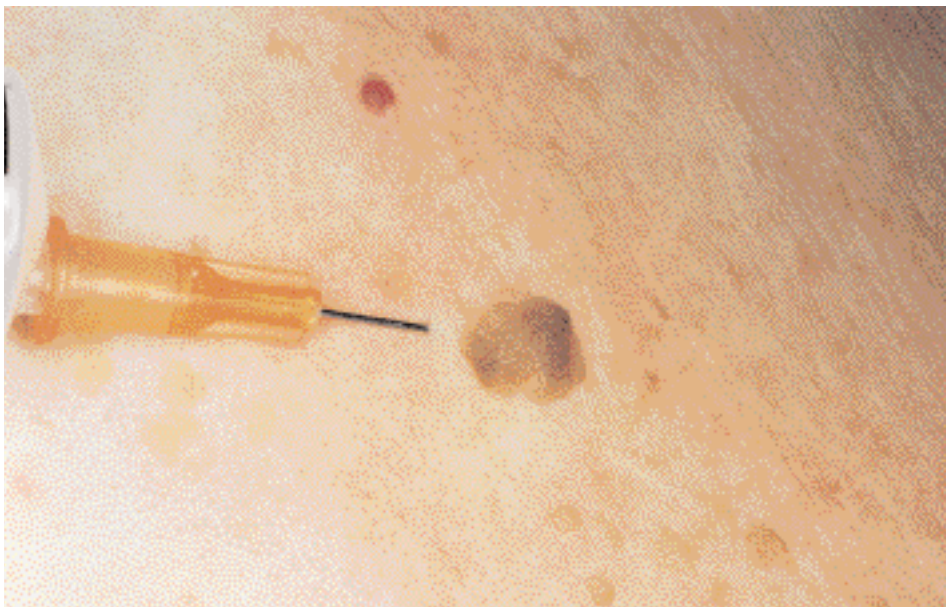


Fig. 39.0.1 Seborrhoeic keratosis in the sternal region.

39.1 Large-sized keratoses

Programme data

Direct - Coag microelectrodes - 14 Watts - EM 15

Coagulation is the traditional treatment for large or medium-sized keratoses. After positioning the patient's return electrode and disinfecting the skin, the operator sets the function to **coagulation with microelectrodes**, the power to **14** or **20 Watts** and uses an **EM 15** electromaniple.

The keratotic lesion is superficially

coagulated with rapid hand movements and the coagulated material removed with the same electromaniple or a curette. The manoeuvre is repeated until the keratosis is eliminated (**Fig. 39.1.1-5**).

There is a difference in consistency between the keratotic tissue, which is crumbly, and the dermis beneath it. It is therefore easy to establish when the healthy tissue is reached.

During this procedure, the operator presses the emission-control pedal before bringing the electromaniple into contact with the lesion.

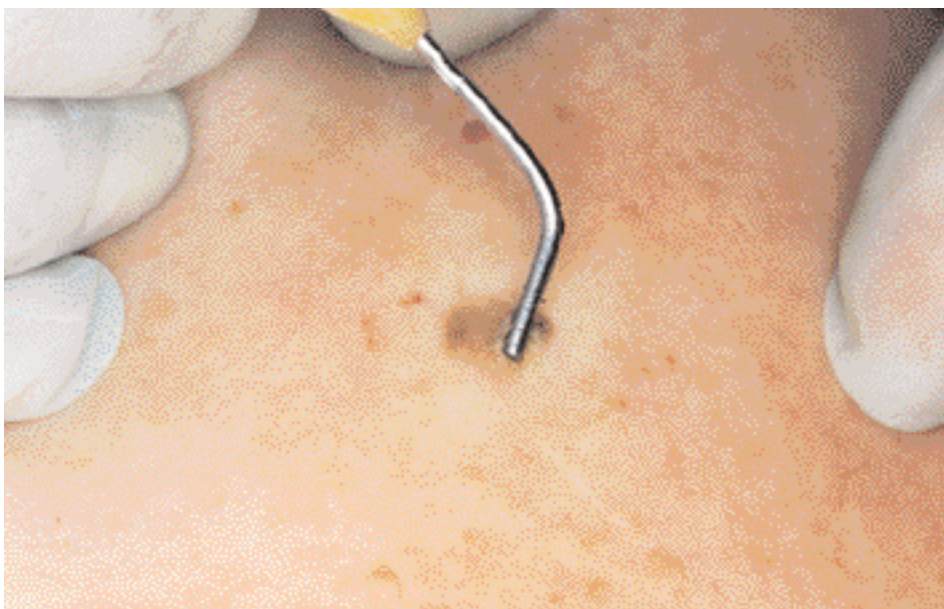

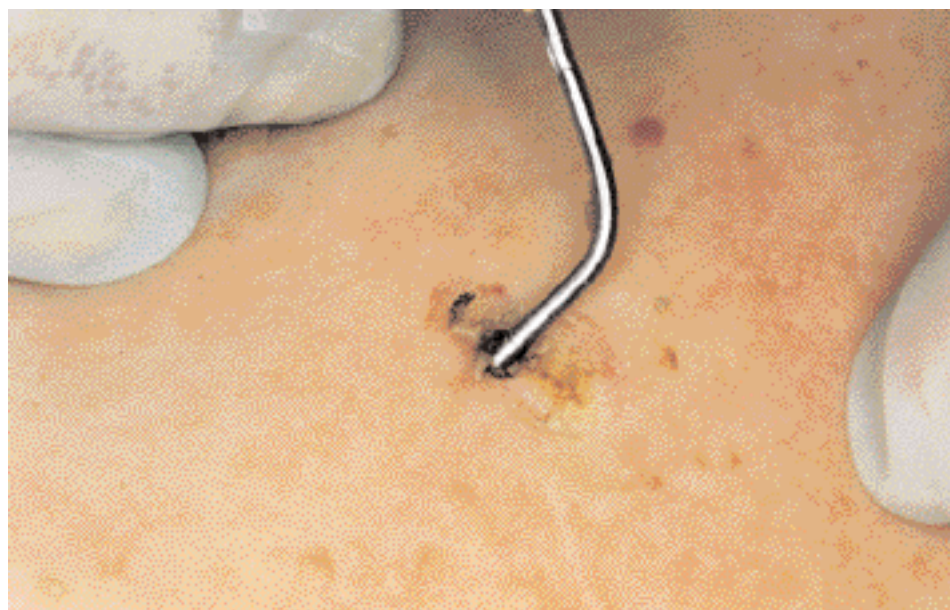Fig. 39.1.1 The keratosis is gently coagulated on the surface. Programme data: **coagulation with microelectrodes, 14 Watts, EM 15** electromaniple. Local anaesthesia.

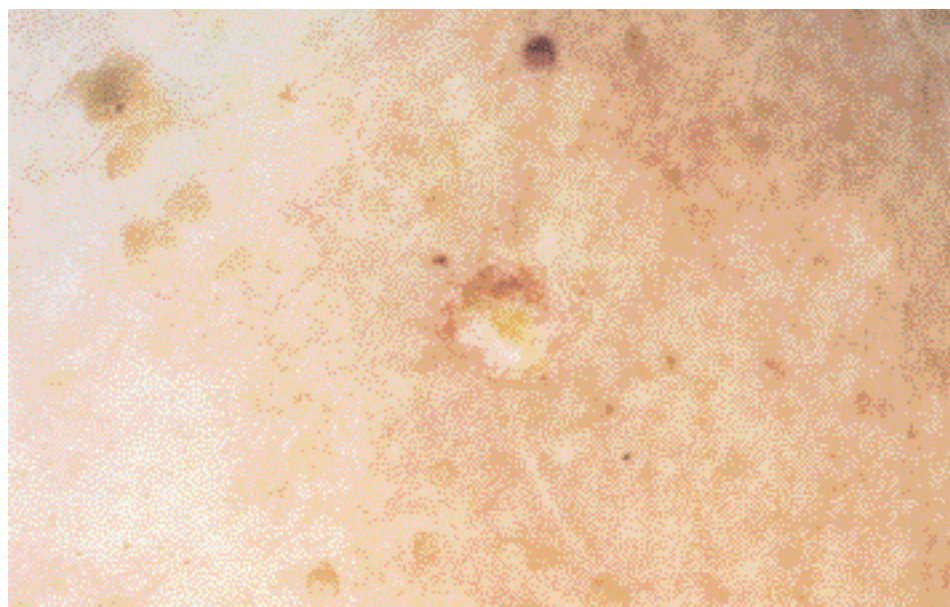
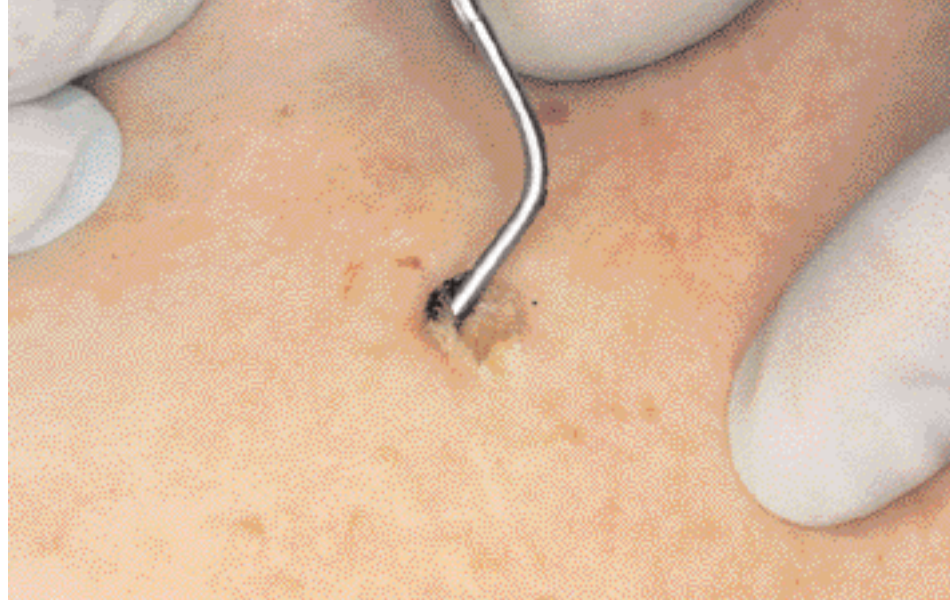
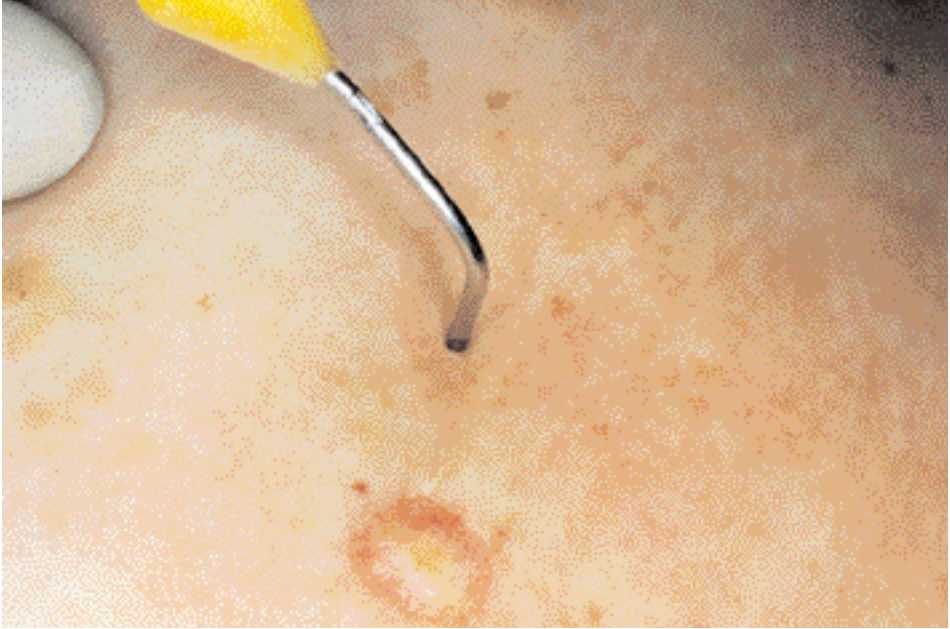



Fig. 39.1.2 The operator resets the Timed apparatus and eliminates a ruby angioma which is near the keratosis. Programme data: **coagulation with microelectrodes, 38 Watts, 9 hundredths of a second, EM 15** electromaniple.

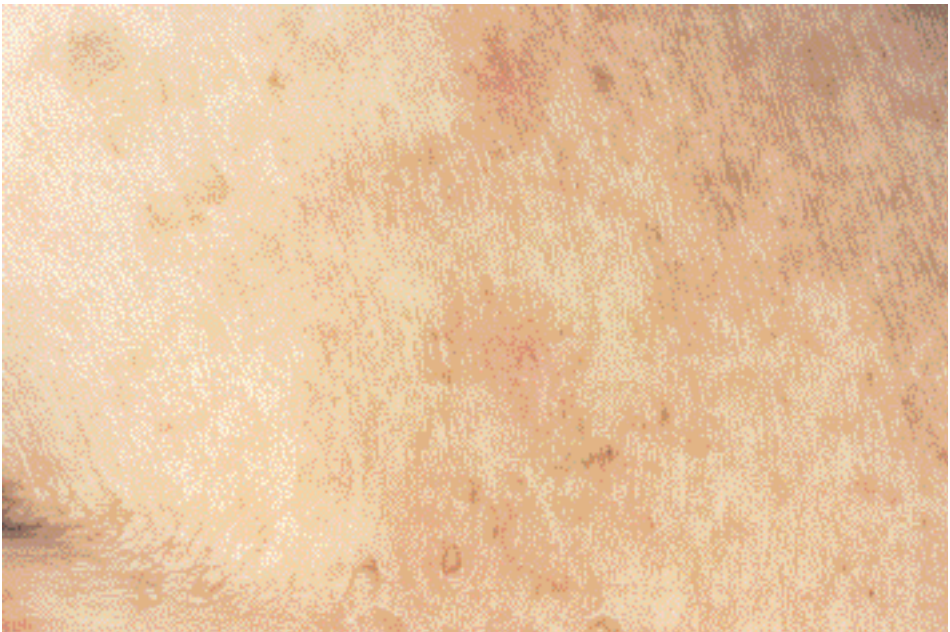

Fig. 39.1.3 There is a distinct cleavage between the keratotic tissue and the dermis.

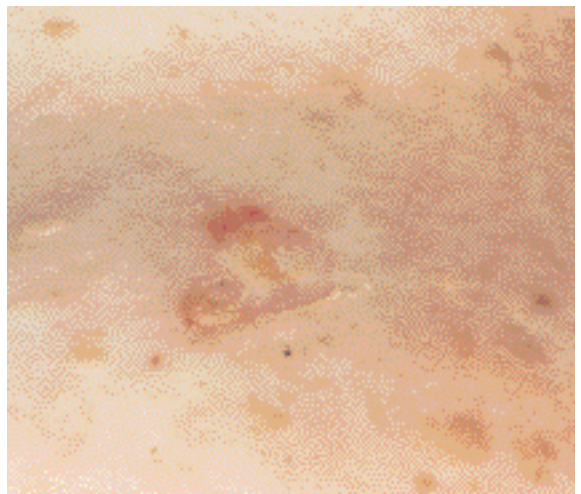
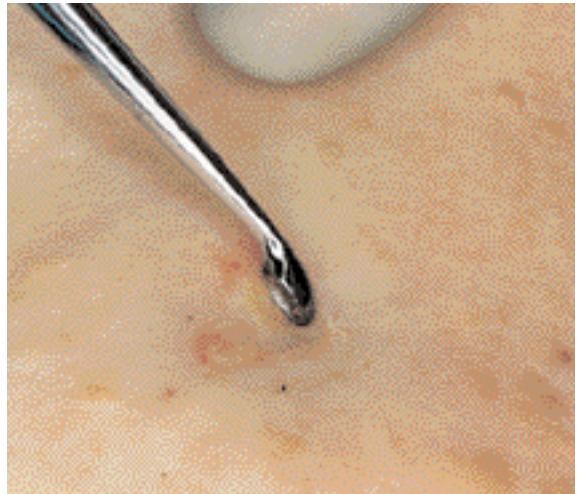
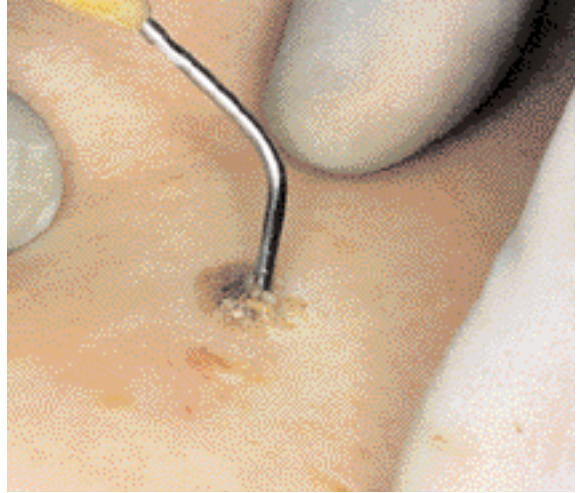


Fig. 39.1.4 Programme data: coagulation with microelectrodes, 20 Watts, EM 15 electromaniple. Local anaesthesia. The coagulated tissue is removed with a spoon.

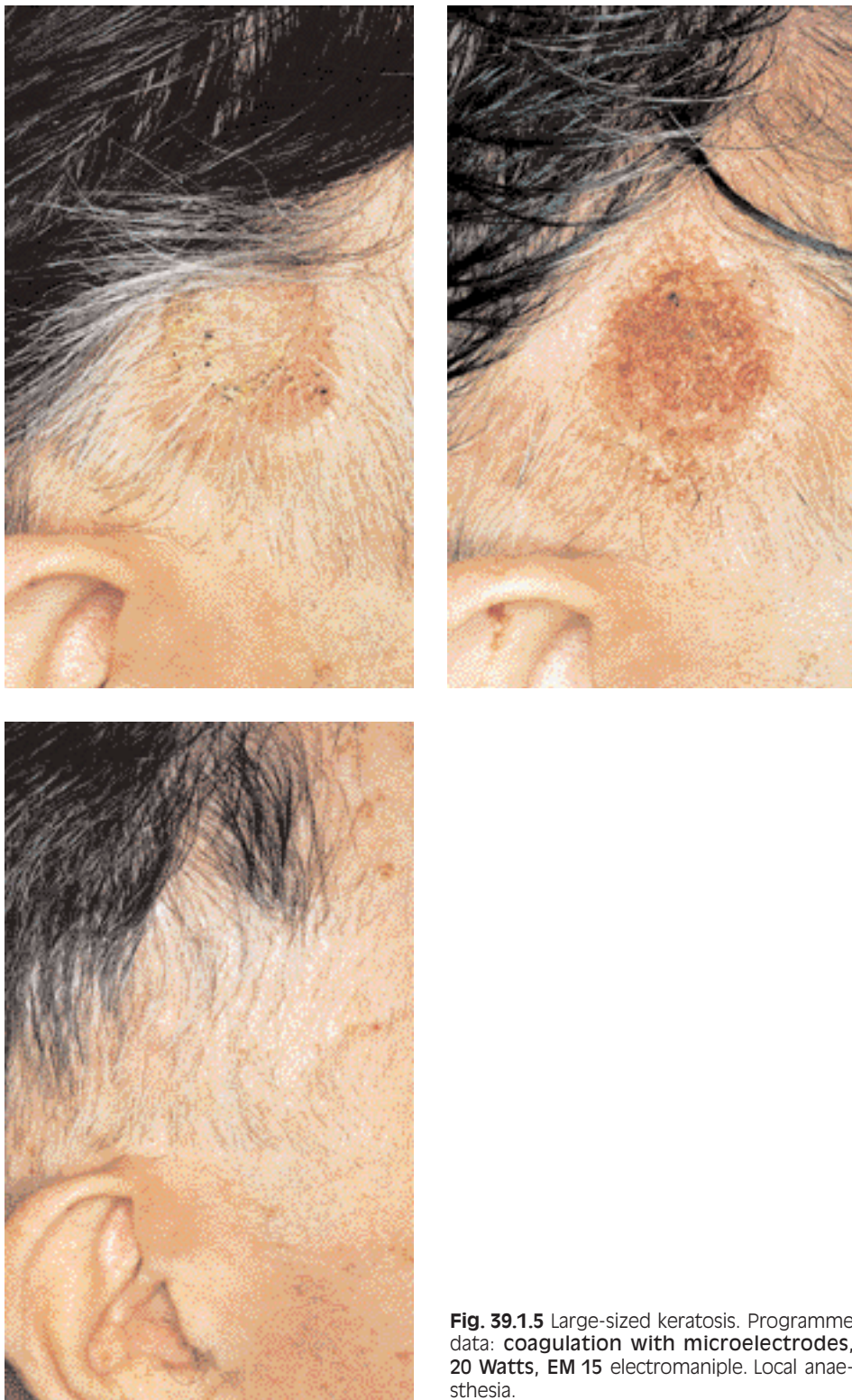


Fig. 39.1.5 Large-sized keratosis. Programme data: coagulation with microelectrodes, 20 Watts, EM 15 electromaniple. Local anaesthesia.

39.2 Small multiple keratoses

Programme data

Timed from 99 to 10 hundredths of a second - Coag microelectrodes - 20 Watts - EM 15.

If the keratoses are multiple and of small size, they may be coagulated without anaesthetic, using a power of **20 Watts** and a time proportional to the size of each keratosis, between **99** and **10 hundredths of a second** (**Fig. 39.2.1**). In this case the **EM 15** electromaniple is activated after it comes into contact with the lesion.

The keratoses are treated in order of size, starting with the largest and shortening the time progressively as the smaller lesions are treated.

Keratoses larger than the tip of the electromaniple may also be treated. After being pressed onto the lesion, the smooth tip is moved during the

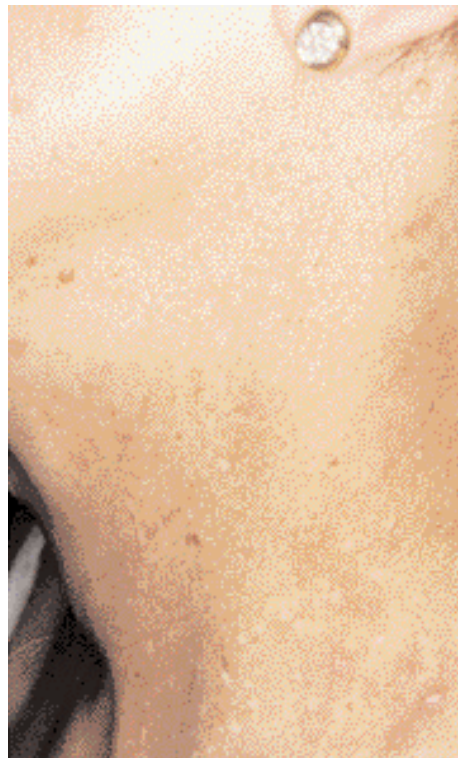
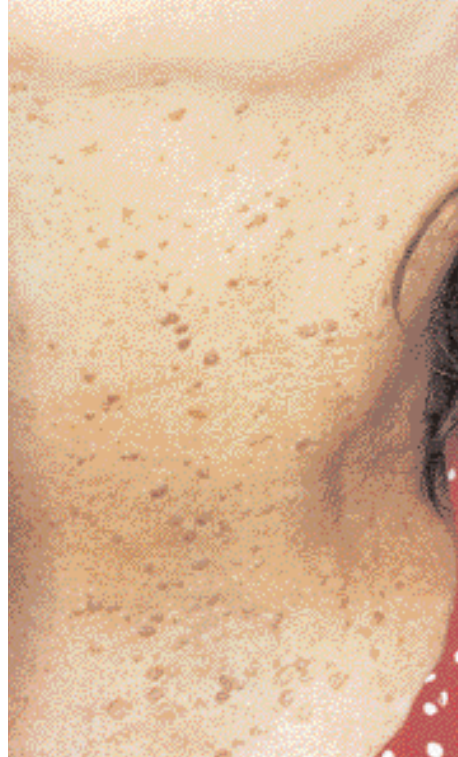
Fig. 39.2.1 Seborrheic keratoses on the neck. Programme data: **coagulation with microelectrodes, 20 Watts, from 99 to 10 hundredths of a second, EM 15** electromaniple. Results after two sittings. More than 400 lesions were coagulated without anaesthesia.

emission to coagulate as large an area of the surface as possible (**Fig. 39.2.2**).

Normally, no more than three or four timed emissions are required for the same lesion. If a total emission time of more than 4 seconds is required, the keratosis should be treated with a direct emission under local anaesthesia. If the keratoses are small, the Timed apparatus may be set to **direct pulsed 5/29 hundredths of a second**.

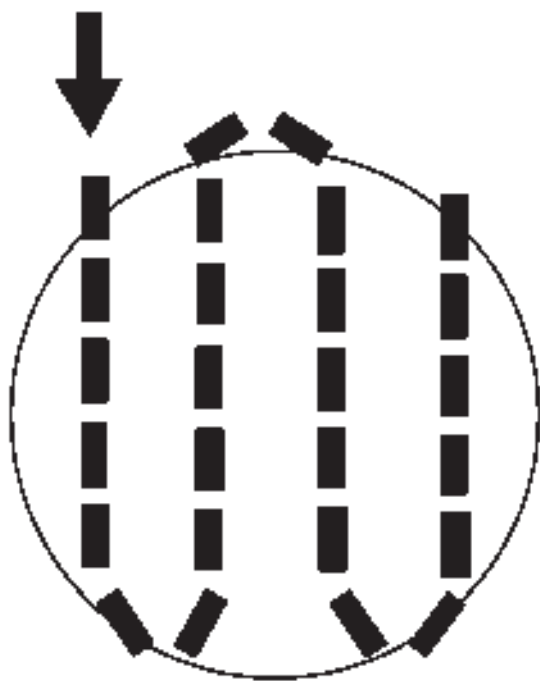


Fig. 39.2.2 During the timed emission, the **EM 15** electromanipule tip is moved rapidly over the keratosis (with an action similar to rubbing out pencil marks) to coagulate a large surface.

39.3 Timedsurgical undermining

Programme data

Direct - Coag microelectrodes - 5 Watts - EM 10 Yellow (obtuse angle).

Large, medium and small-sized keratoses may be eliminated with extreme precision by means of timed surgical undermining, with or without anaesthetic.

The operator sets the power to **5 or 7 Watts** and delicately separates the keratosis from the tissue beneath it with the angle of the needle (A. Valieri) (**Fig. 39.3.1-8**). The dermis must not be coagulated further, even if it has an irregular appearance; further coagulation may result in hypopigmentation.

Keratoses which are in exposed areas are treated with an antiseptic powder and left open to the air to encourage the formation of a crust.

Those in areas covered by clothing should be covered with a non-adherent dressing.

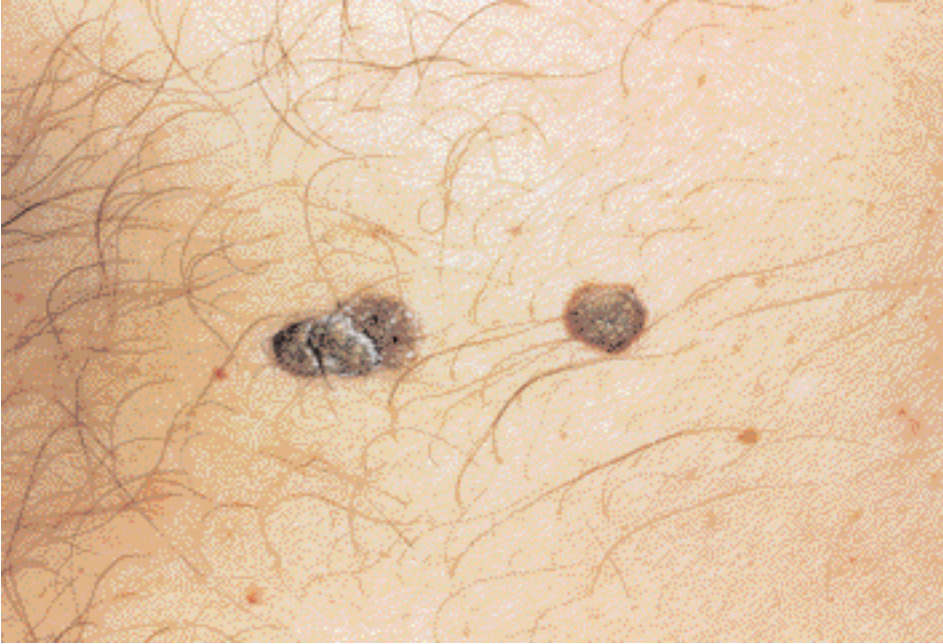


Fig. 39.3.1 Keratoses in the abdominal region.

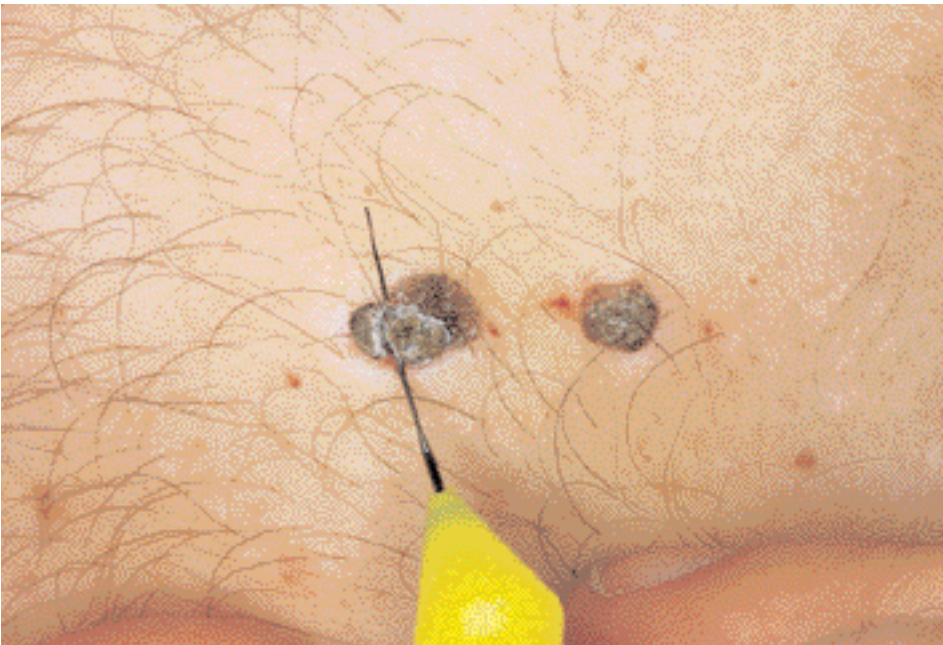


Fig. 39.3.2 After local anaesthetic has been administered, timed surgical undermining is commenced. Programme data: **coagulation with microelectrodes, 5 Watts, EM 10 Yellow** electromaniple.

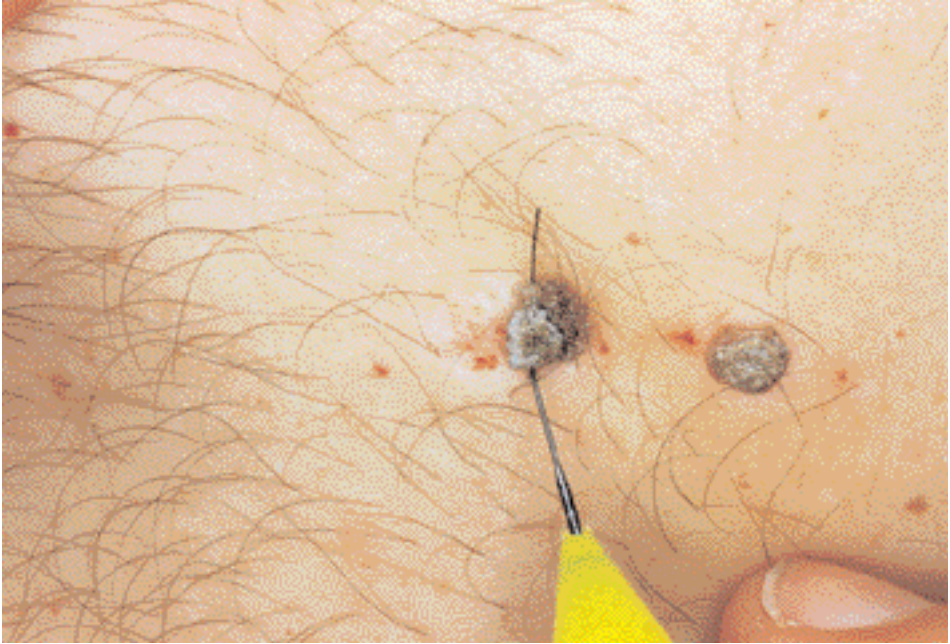

Fig. 39.3.3 Timedsurgical undermining is carried out with an **EM 10 Yellow** electromanipule bent to an obtuse angle.

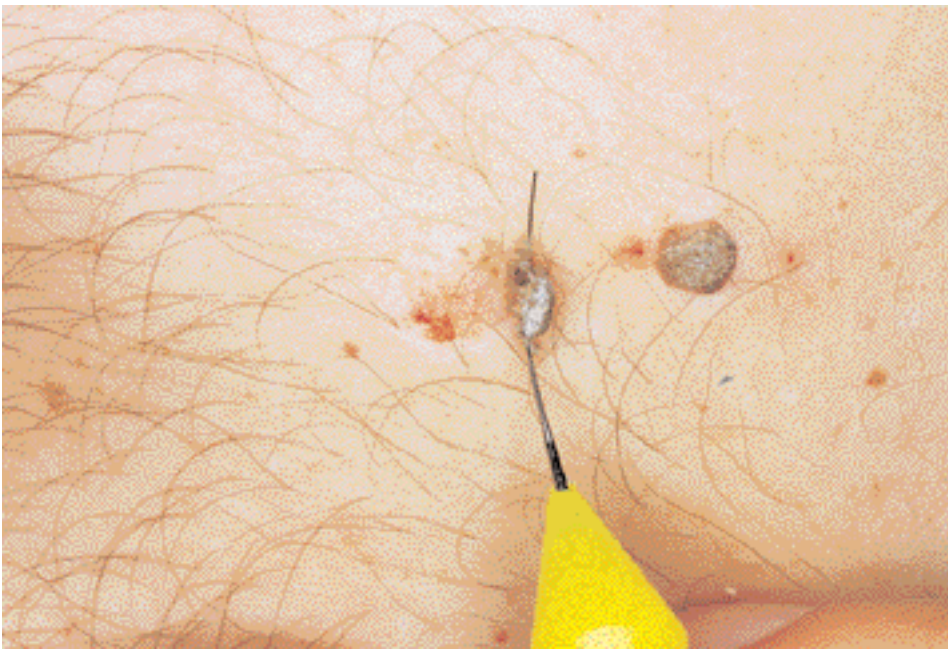


Fig. 39.3.4 The low power used prevents deeper tissue damage.

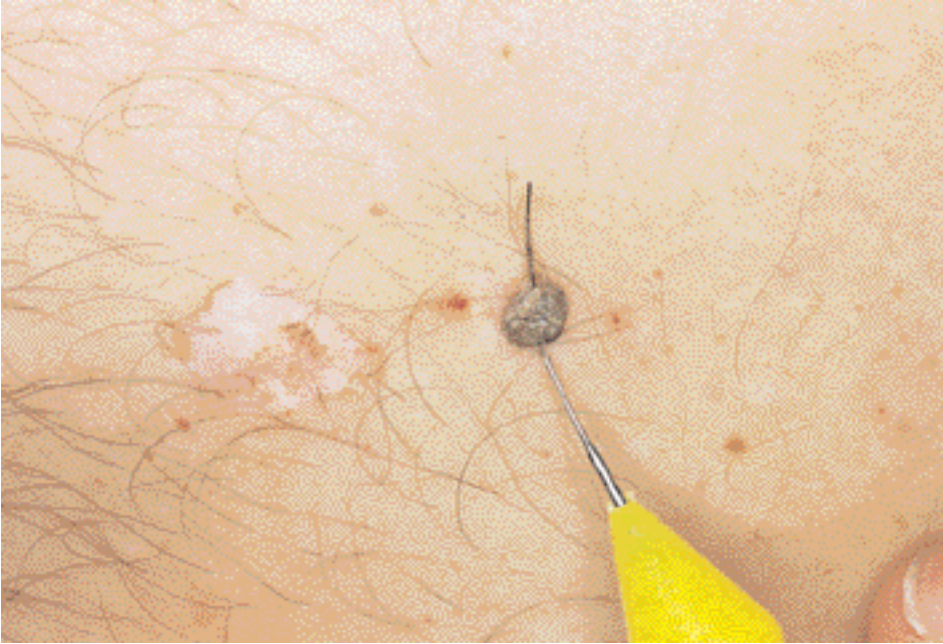


Fig. 39.3.5 On finishing the timed surgical undermining of the first keratosis, intervention on the second is started. In order to avoid leaving permanent achromic patches, the underlying dermis must not be coagulated.

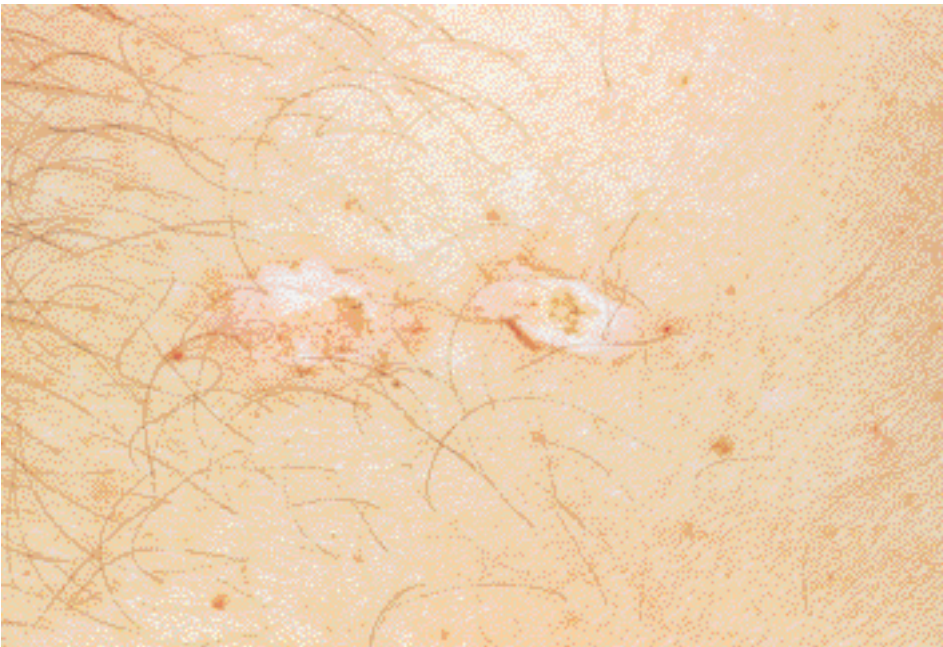


Fig. 39.3.6 Immediately after the timed surgical undermining.

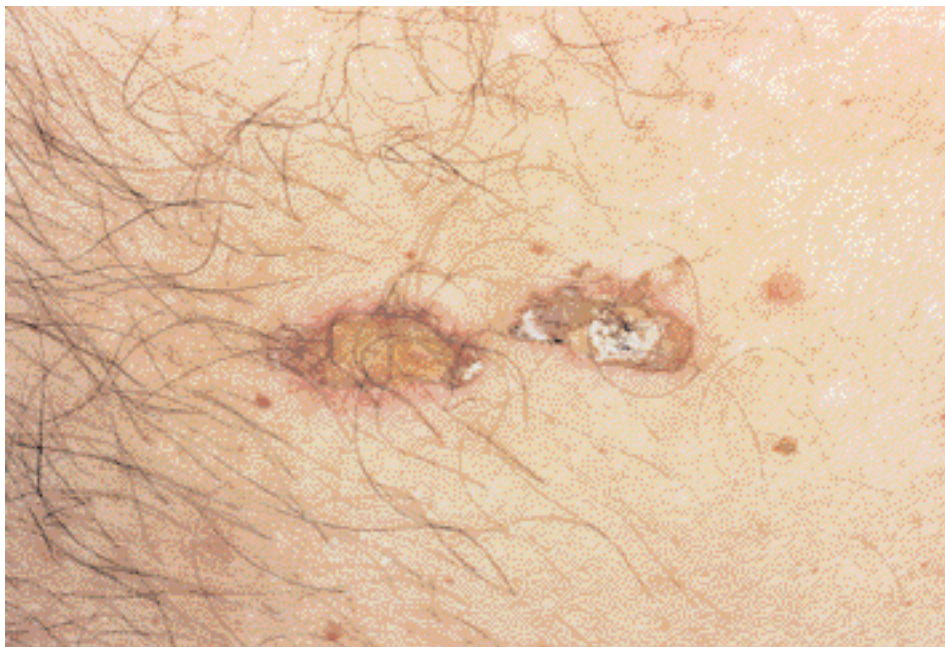


Fig. 39.3.7 After 4 days

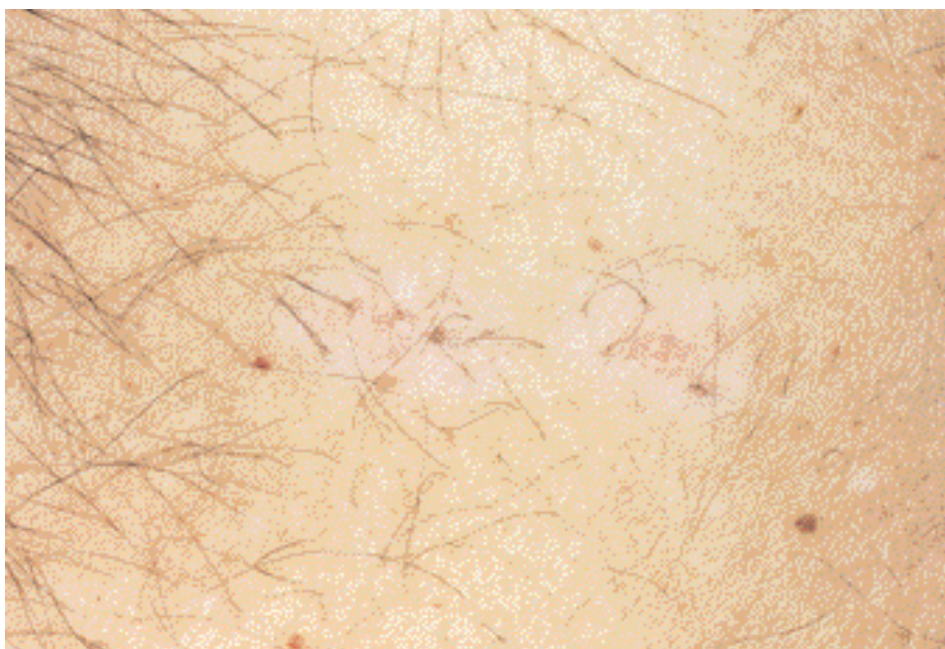

Fig. 39.3.8 Results after two months

40

TREATMENT OF INGROWING TOE-NAILS

Programme data

**Direct - Coag microelectrodes - 20
Watts - EM 15.**

The treatment of ingrowing toe-nails consists of eliminating the cause and removing the chronically inflamed tissue, which is a breeding ground for bacteria and fungi.

If the problem is recurrent, it is necessary to modify the interface between the nail and its bed by removing part of the nail matrix on the affected side of the nail, thus reducing the width of the growing nail.

A suitably-sized portion of the nail and matrix is removed, usually from 2 to 4 mm. The nail bed is adapted to the reduced nail and infected tissues are removed (**Fig. 40.0.1-7**).

The procedure is performed under a digital ring block, achieved by infiltration of lignocaine without adrenaline, around the base of the toe (see fig. 12.0.1).

The operator lifts a small flap above the matrix to be removed.

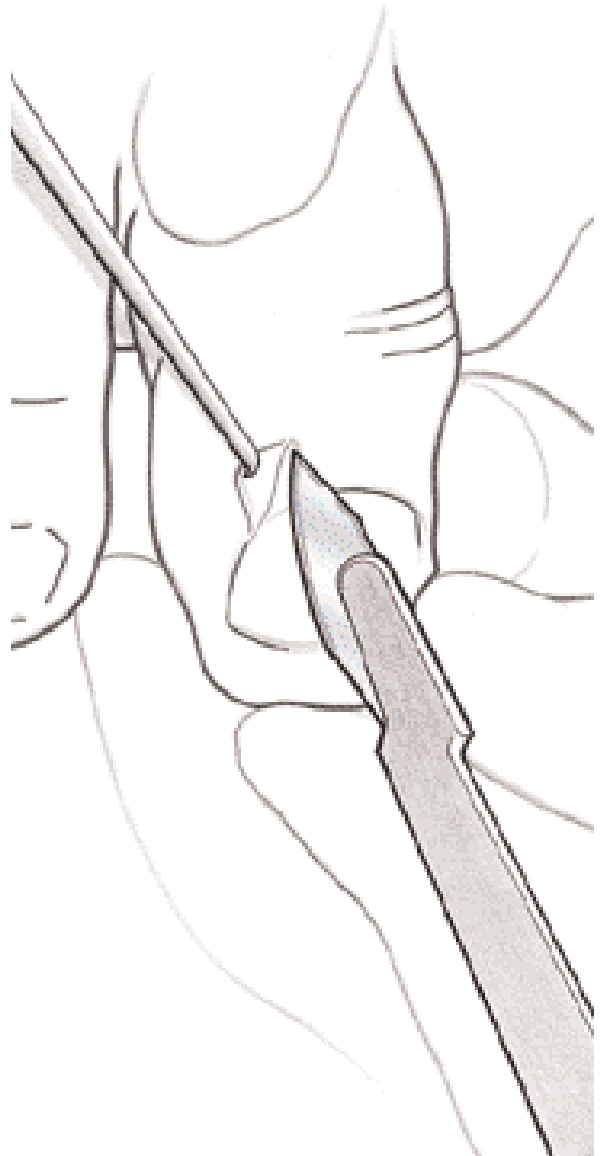

Fig. 40.0.1 A small flap of skin is lifted from above the matrix to be removed.

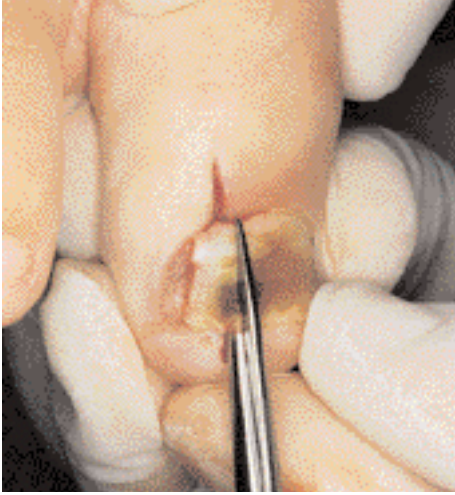


Fig. 40.0.2 The nail is cut according to the desired reduction in size

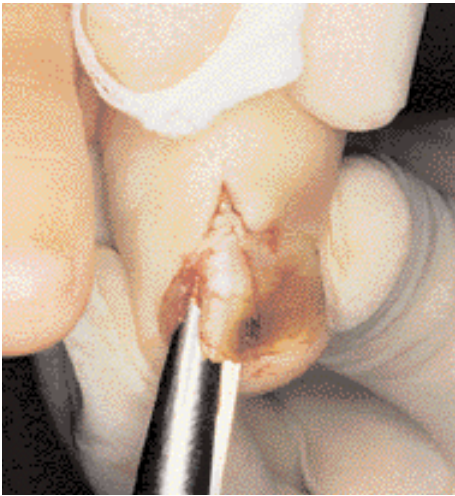


Fig. 40.0.3 The corresponding portion of the matrix is separated and removed from the nail bed.

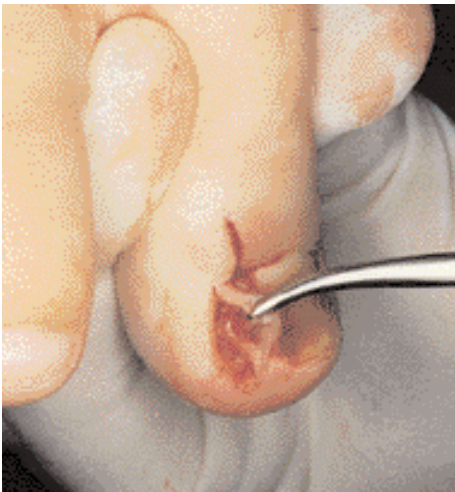

Fig. 40.0.4 The chronically inflamed tissue is removed by means of wedge excision.

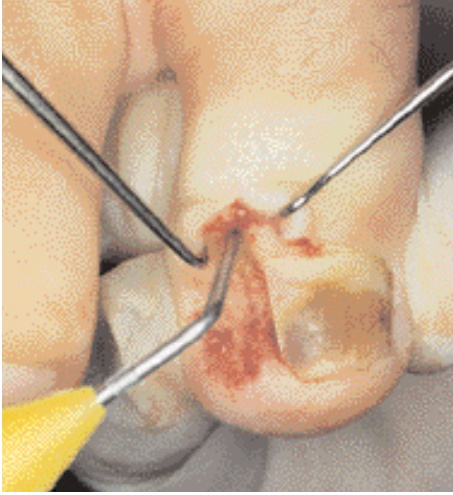


Fig. 40.0.5 Delicate coagulation of the area from which the matrix has been removed is carried out, to destroy residual nail matrix cells. Programme data: **coagulation with microelectrodes, 20 Watts, EM 15 electro-manipule.**

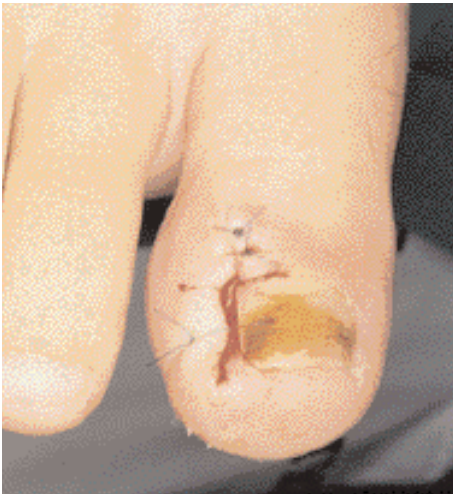

Fig. 40.0.6 The operator completes the procedure by suturing the skin wound.

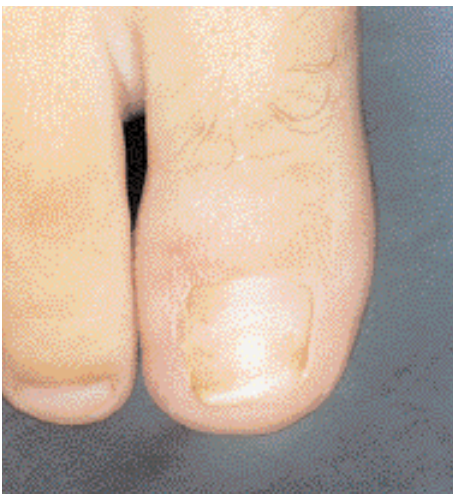

Fig. 40.0.7 Results. Reduced in size and modified in shape, the nail will no longer tend to grow into the adjacent skin.

The nail plate is separated using scissors, proceeding in a proximal direction and passing under the matrix to be removed. A strip of nail and matrix is removed. The granulation tissue along the side of the nail bed must be completely removed.

Coagulation of the zone from which the matrix has been removed is achieved with the function of **coagulation with microelectrodes**, at a power of **20 Watts**, using an **EM 15** electromaniple to destroy the residual germinative cells.

The operator completes the procedure by suturing the skin wound. An antibacterial and antifungal cream is applied until healing is complete.

41

COAGULATION OF LACHRYMAL CANALS

Programme data

Timed 20 hundredths of a second
- Coag microelectrodes - 20 Watts
- EM 10 Yellow.

A reduction of the natural tear production may occur in isolation (keratoconjunctivitis sicca), in association with salivary gland dysfunction (primary Sjogren syndrome) or as a consequence of connective tissue disease.

Coagulation of the lachrymal canals prevents outflow and maximises the effect of any residual tear production.

When medication does not improve the patient's condition, the operator obliterates the lachrymal canals with a timed emission (F. Reggiardo, 1993). The reduced outflow allows the lubrication of the cornea to be improved (**Fig. 41.0.1**).

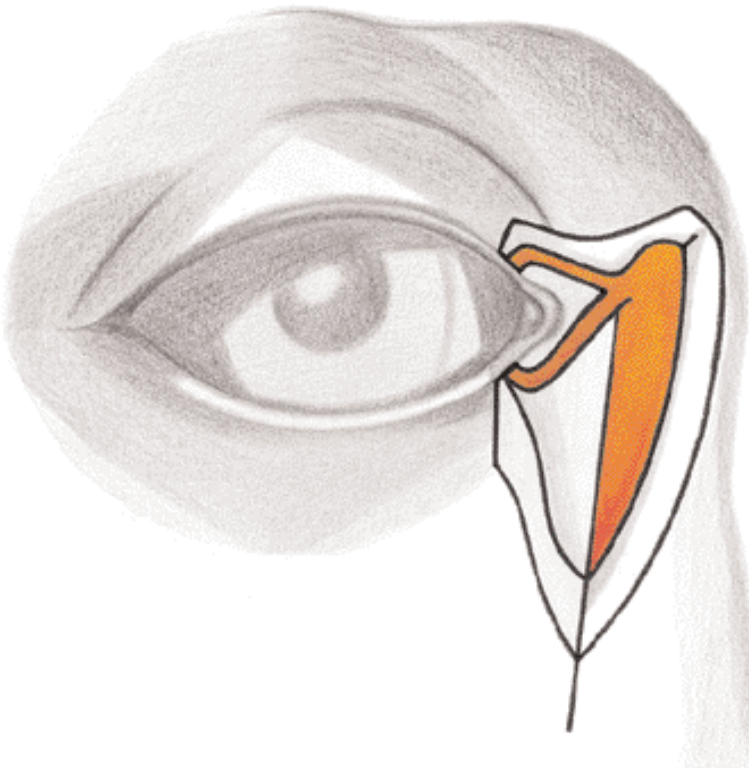


Fig. 41.0.1 The lachrymal canals are the route for outflow of tears.

Prior to definitive treatment, tests can be performed to assess the likely benefit from lachrymal duct obliteration. A fine filament of cellulose is inserted into the lower lachrymal canal. This prevents tear outflow and allows any improvement in the lubrication of the eye and the development of epiphora to be assessed. Patients who show an improvement

after this test may undergo timed-surgical obliteration of the lower lachrymal canal (**Fig. 41.0.2**). If marked epiphora occurs, the upper lachrymal canal is coagulated. The procedure is carried out under topical anaesthesia with oxybuprocaine chloride (4mg/ml). After positioning the patient's return electrode, the operator sets the Timed apparatus to

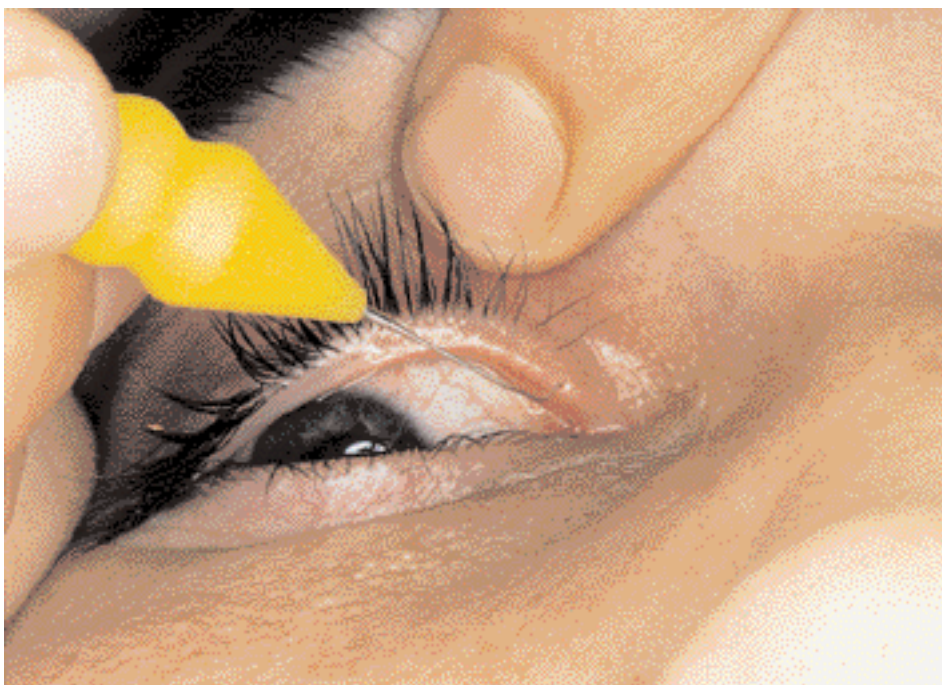


Fig. 41.0.2 The point of the **EM 10** electromaniple is inserted about 4 mm into the upper lachrymal canal.

the timed mode, the emission time to **20 hundredths of a second**, the function to **coagulation with microelectrodes** and the power to **14 or 20 Watts**; an **EM 10 Yellow** electromaniple is used. The tip of the electromaniple is inserted 3 or 4 mm into the canal. After the first emission, which is carried out in depth, the point is gradually withdrawn,

while a second and then a third emission are generated. The efficacy of the timed emissions is indicated by whitening of the tissue around the canal and by the organic material attached to the tip of the electromaniple after coagulation (**Fig. 41.0.3-5**). The patient receives medication with an antibiotic eyewash for a few days after the procedure .

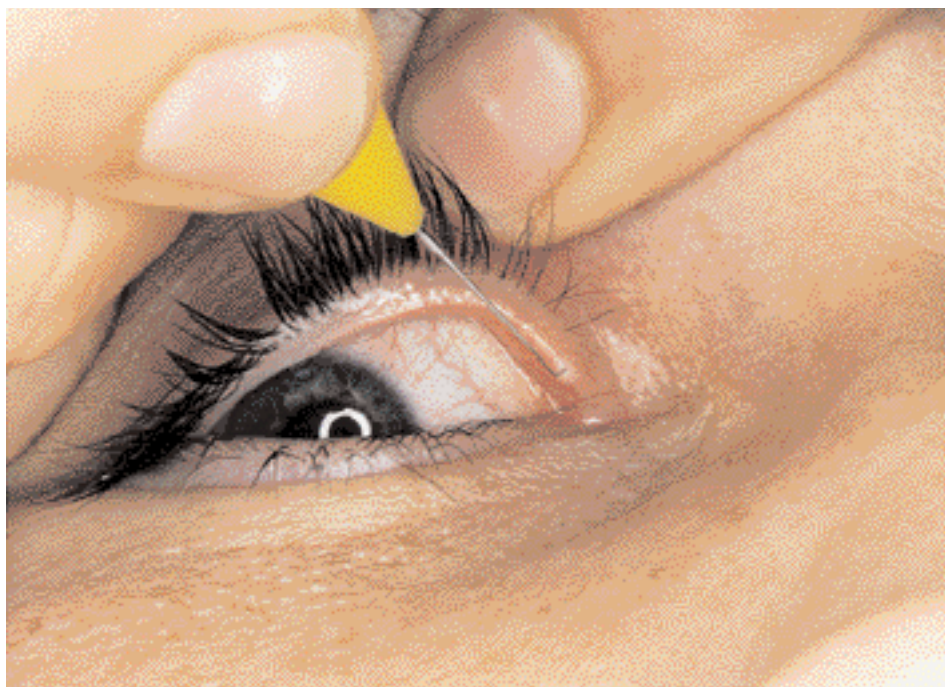


Fig. 41.0.3 The timed emission causes whitening of the tissues around the canal. Programme data: **coagulation with microelectrodes, 20 Watts, 20 hundredths of a second, EM 10 Yellow** electromaniple. Topical anaesthesia.

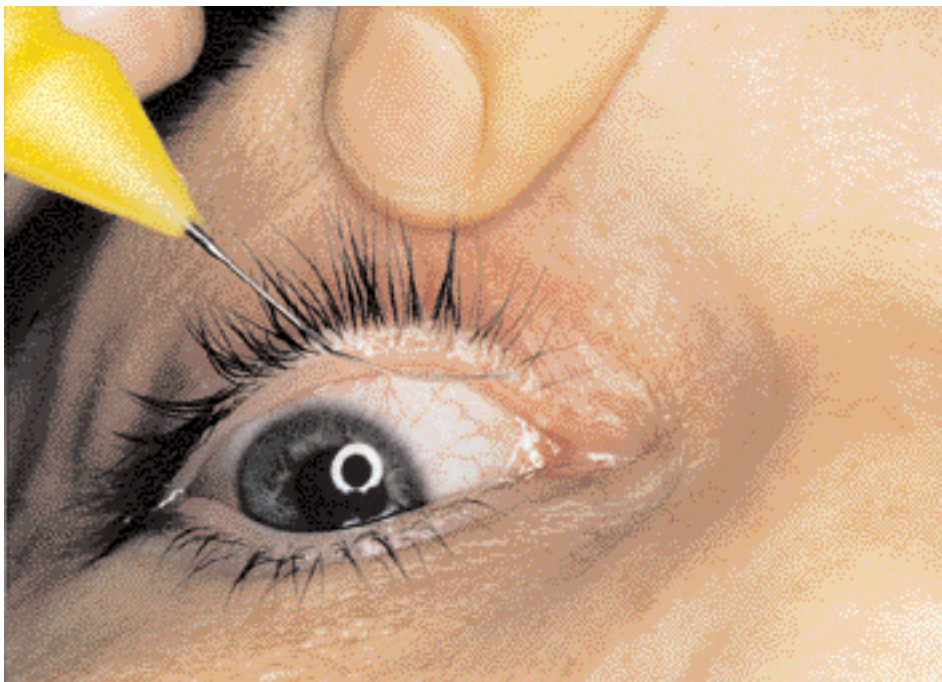


Fig. 41.0.4 Canal mucosa cells are visible on the tip of the electromaniple.

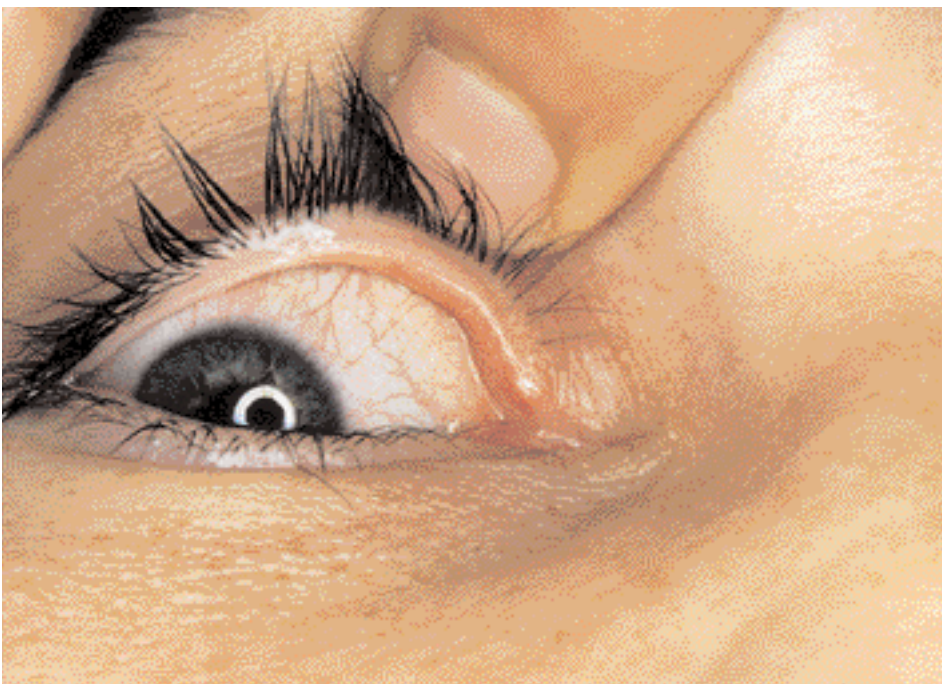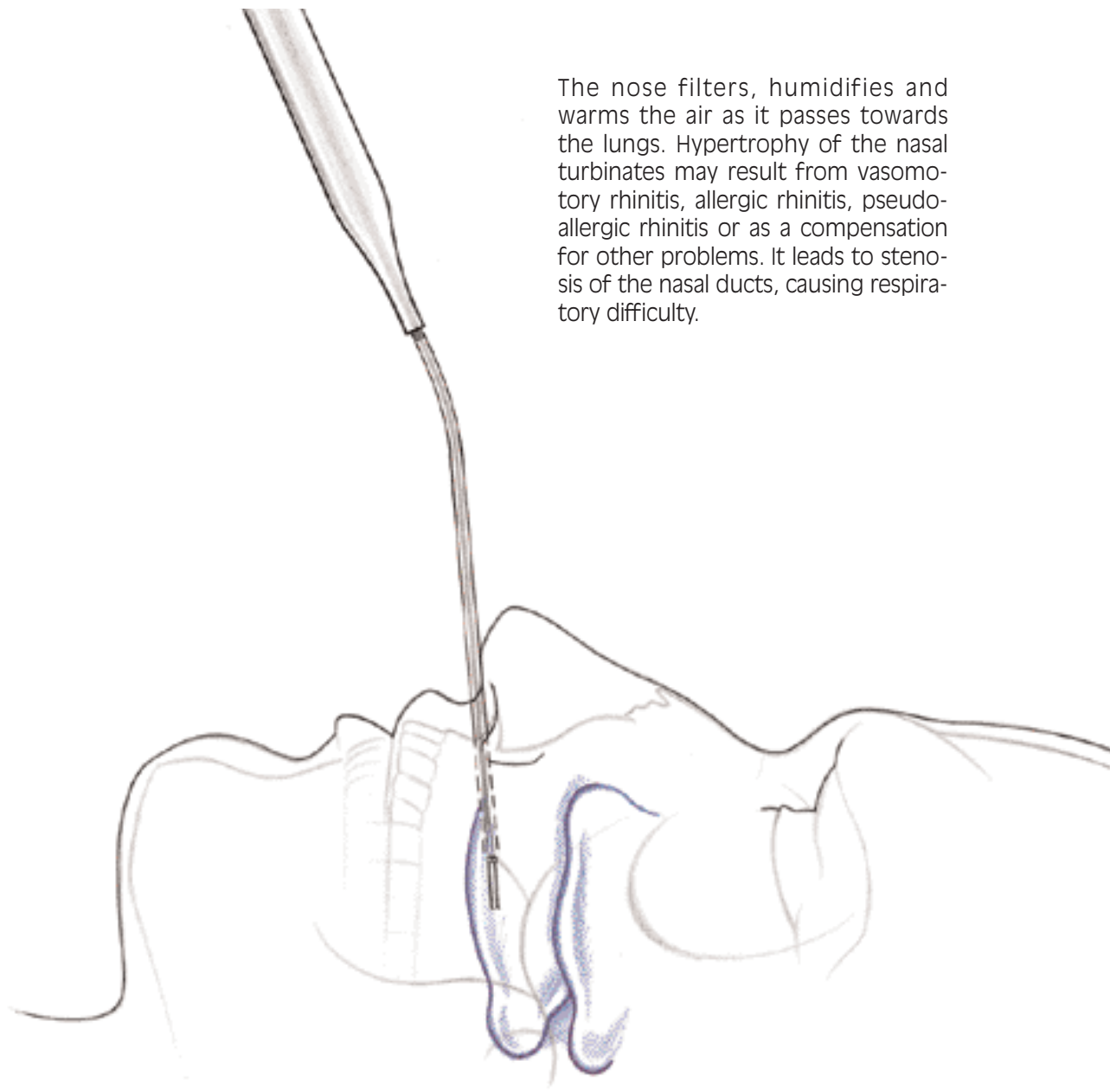


Fig. 41.0.5 Obliteration of the lachrymal canal reduces the outflow of tears, allowing the surface of the cornea to remain moist.

42

BIPOLAR COAGULATION OF NASAL TURBINATES

The nose filters, humidifies and warms the air as it passes towards the lungs. Hypertrophy of the nasal turbinates may result from vasomotor rhinitis, allergic rhinitis, pseudo-allergic rhinitis or as a compensation for other problems. It leads to stenosis of the nasal ducts, causing respiratory difficulty.



Tab. 42.1 Techniques for reducing hypertrophy of turbinates

Turbinectomy

Sub-mucosal turbinectomy

Cryosurgery

Thermocoagulation

Diathermocoagulation

Sub-mucosal monopolar coagulation

Direct or/and timed coagulation with bipolar electrodes.

The reduction of hypertrophic nasal turbinates to restore normal air flow and allow breathing without effort may be carried out in numerous ways (Tab. 42.1). The chosen technique must be efficacious, rapid and, if possible, bloodless.

Bipolar timed surgery is able to satisfy these criteria (**Fig. 42.0.1**).

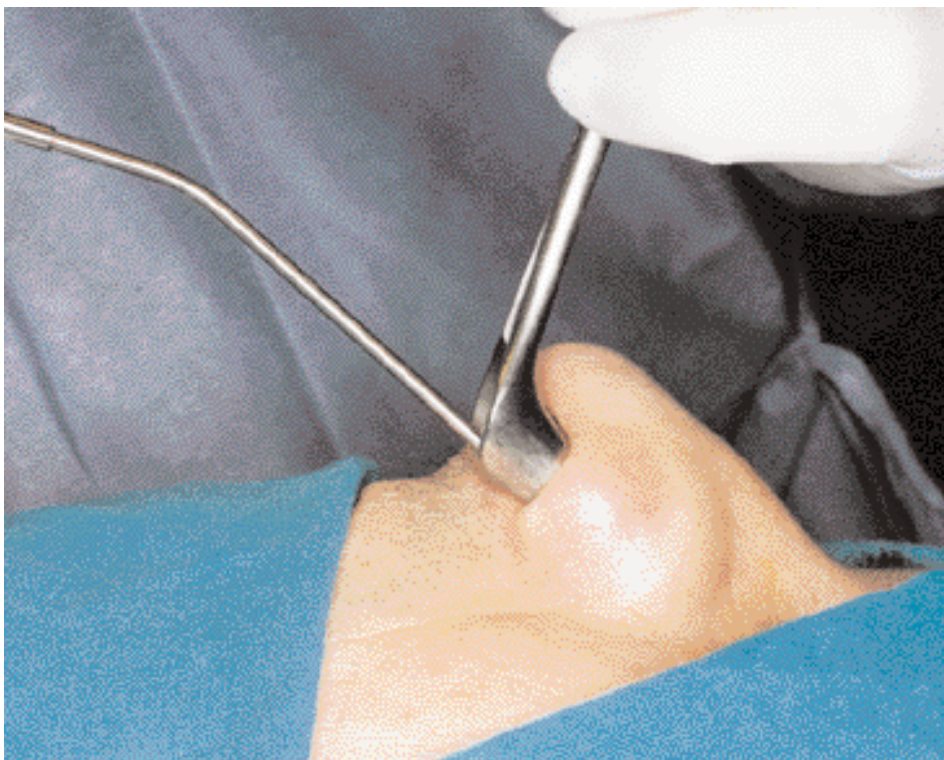


Fig. 42.0.1 The two needles of the bipolar electrode are inserted into the hypertrophic tissue of the turbinates. Programme data: **coagulation with macroelectrodes, 20 Watts, 99 hundredths of a second**. General anaesthesia.

42.1 Coagulation of nasal turbinates

Programme data

Direct or Timed 99 hundredths of a second - Coag microelectrodes - from 20 to 38 Watts - Bipolar - Bipolar electrode

Under topical, local or general anaesthesia, the Timed apparatus is set to the timed mode, the function to **coagulation with macroelectrodes or microelectrodes**, emission time to **99 hundredths of a second** and power to **20, 27 or 38 Watts**.

The bipolar cable is connected to the apparatus, which is automatically set to the bipolar mode, and the neutral electrode is disconnected.

The two points of the bipolar electrode are inserted completely into the hypertrophic turbinate before the timed emission is generated.

The bipolar coagulation causes immediate retraction of the tissue. A series of timed emissions along the turbinates completes the reduction (**Fig. 42.1.1**).

Timed bipolar coagulation yields particularly useful results in children. After the procedure, bleeding does not occur and there is no need to apply a pad. The nasal cavity is treated with an antiseptic cream.

If the turbinate is abnormally oedematous and hypertrophic, the operator sets the equipment to the direct mode, and draws the bipolar electrodes slowly along the turbinates while applying slight pressure.

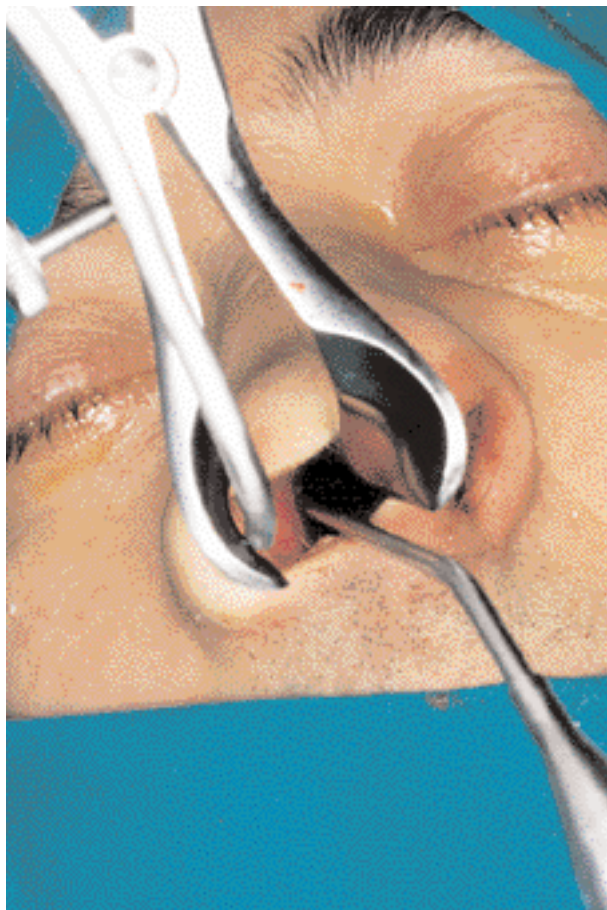


Fig. 42.1.1 A series of timed bipolar emissions completes the reduction.

42.2 Coagulation of the neurovascular centre

Programme data

**Timed 99 hundredths of a second -
Coag microelectrodes - 20 Watts -
Bipolar - Bipolar electrode**

The turbinate can also be reduced by coagulating the relevant neurovascular centre (Baricalla 1991).

Once the floor of the nasal fossa and the lower turbinate have been topically anaesthetised, the tips of the bipolar electrode are inserted behind the head of the lower turbinate,

upwards and medially, until contact is made with the concha. The timed emission is repeated 5 or 6 times (**Fig. 42.2.1**). When the neurovascular centre is being coagulated, a characteristic sizzling sound is heard. An antibiotic ointment is subsequently applied to the nasal cavity without using tampons. A good long-term result is achieved (**Fig. 42.2.2**).

Coagulation of the neuro-vascular centre can be completed by skimming the bipolar electrode over the surface of the turbinate in the direct mode.

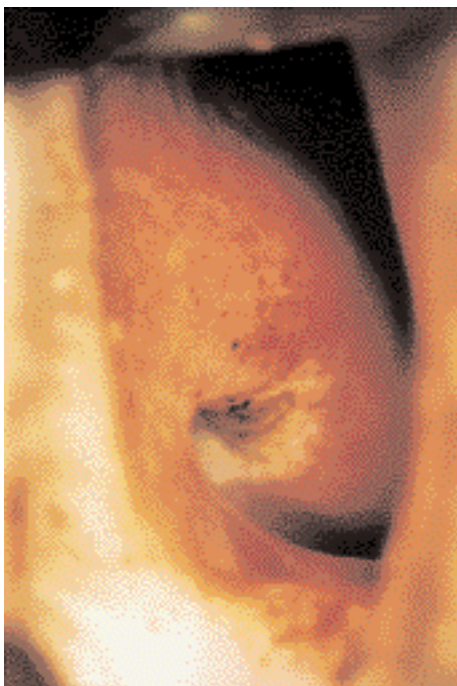

Fig. 42.2.1 Coagulation of the neurovascular centre. Programme data: **coagulation with microelectrodes, 20 Watts, 99 hundredths of a second, bipolar electrode.** Topical anaesthesia.

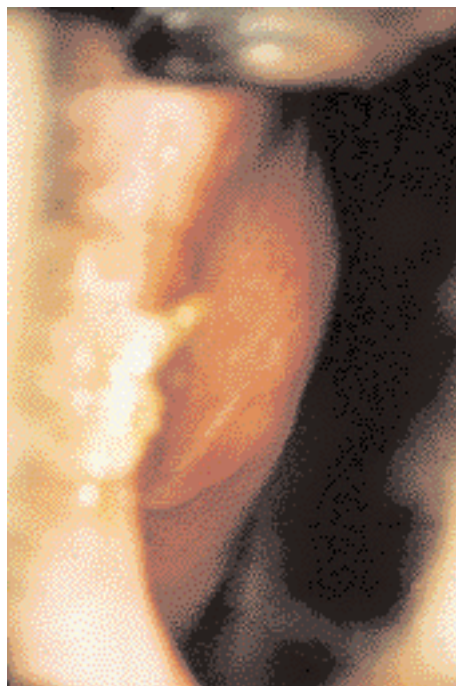


Fig. 42.2.2 Reduction of the turbinate achieved by means of timed bipolar coagulation of the neurovascular centre.

43 EXCISION WITH TIMED AND PULSED CUTTING

Timed cutting enables cutaneous and mucosal excisions and micro-excisions to be performed. The progression of the cut is predetermined with extreme precision by regulating the emission time. Pushing the pedal generates a single timed emission. The interval between emissions gives the operator sufficient time to correctly position the electromaniple tip, which must be moved a few millimetres and put under a slight elastic pressure to carry out cutting (see section 8.8).

Micro-excisions can be also carried out with slow pulsed cutting

(0.5/45.5 hundredths of a second. Large excisions can be carried out by means of rapid pulsed cutting **(0.3/5.3 hundredths of a second).** In this case, the operator keeps the pedal pressed.

If the cut penetrates the whole thickness of the skin, the skin is sutured; healing times are similar to those of cuts produced by a scalpel.

If the excision remain within the thickness of the dermis (electroshaving), the wound can be left to heal spontaneously.

Table 43.1 shows the main indications for timed and pulsed cutting.

Tab. 43.1 - Principal indications for timed or pulsed cutting

Mucosal, conjunctival and cutaneous excisions and micro-excisions
Upper blepharoplasty and transconjunctival blepharoplasty
Tangential excision of benign neoformations (electroshaving)
Excision of pedunculated or liftable neoformations
Excision of pigmented neoformations
Excision of malignant melanomas
Re-excision of scars
Procedures requiring precision and haemostasis
Operations on poorly accessible anatomical regions

43.1 Cutting through the whole thickness of the skin

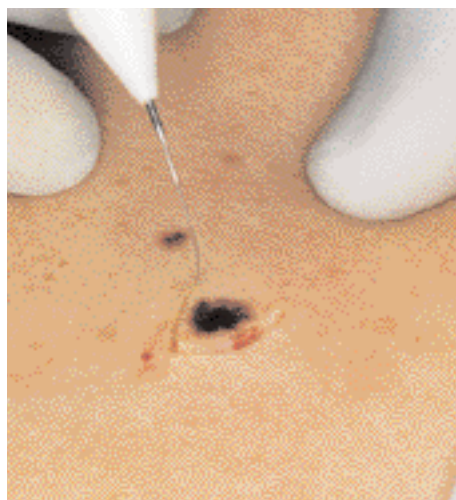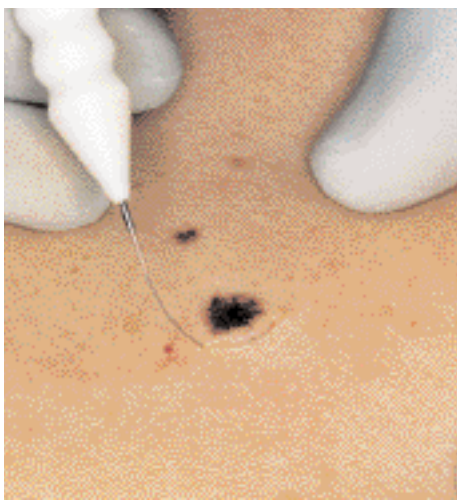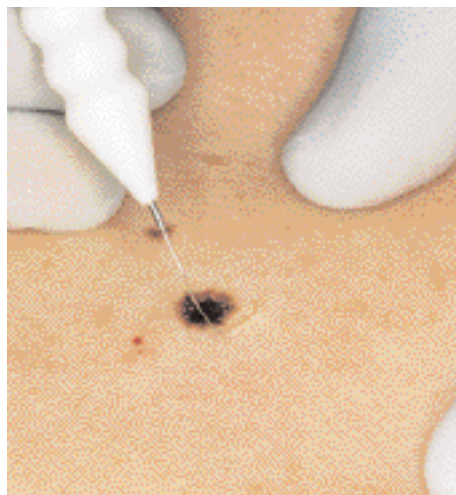
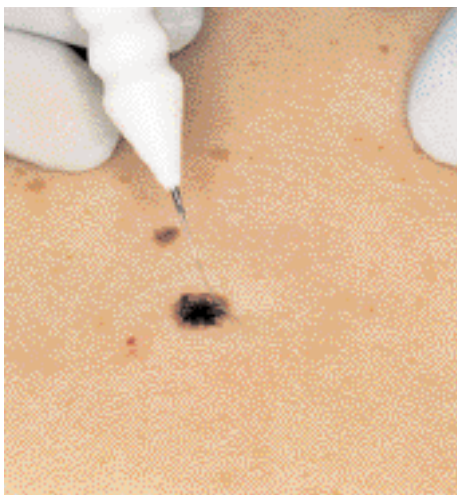
Programme data

Timed from 1 to 3 hundredths of a second or Direct pulsed 0.5/24.5 or 0.3/5.3 hundredths of a second
- Cut - 38 Watts - EM 10 White

Traditional electrocautery is not used for cutting the skin because it produces a burn at the margins of the

wound, which considerably retards scar formation (Mock 1935). Healing may occur only if the necrotic tissues are eliminated during wound repair. Moreover the wound is prone to infection in the presence of necrotic tissue. Timed and pulsed cutting, on the other hand, cuts the skin without burning the edges (**Fig. 43.1.1-2**).

A series of single micro-cuts is produced, utilising a high-power current, a brief emission time, and a fine electromanipule with elastic properties.



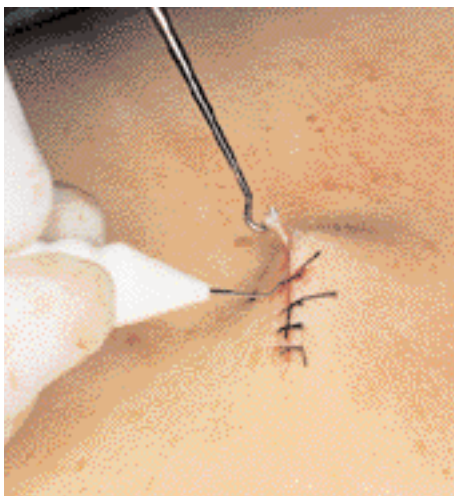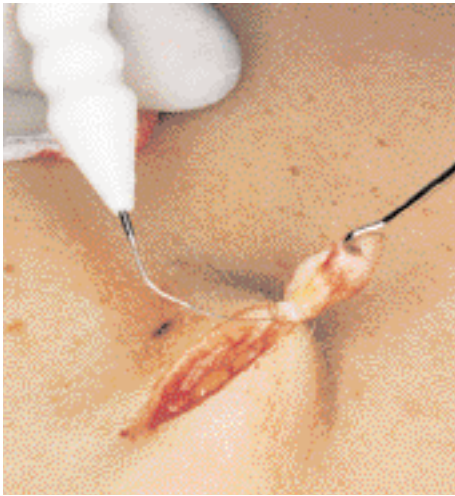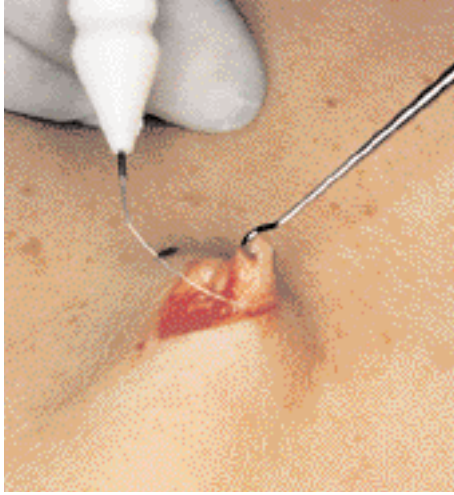


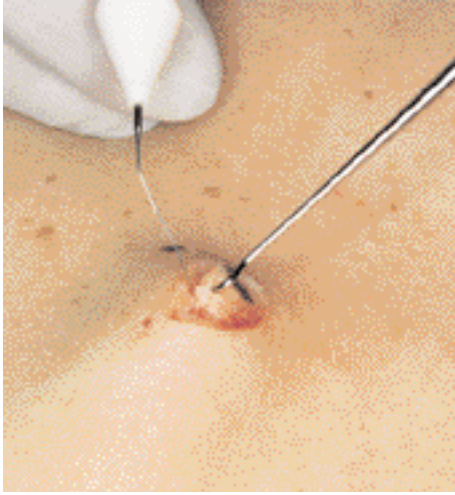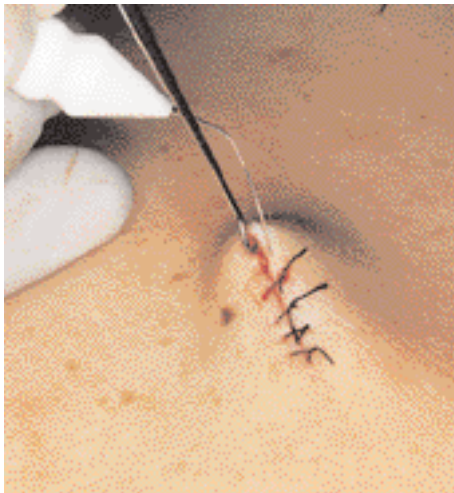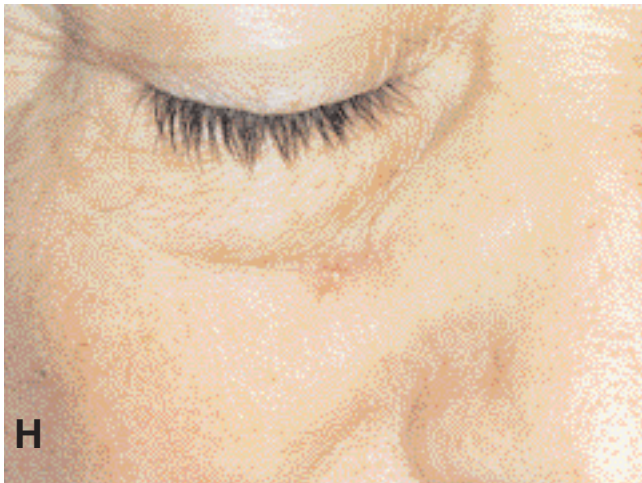
Fig. 43.1.1 Pigmented neoformation. Programme data: cutting (Cut), 38 Watts, 2 hundredths of a second, EM 10 White electromaniple. Local anaesthesia. The duration of the emission has been reduced to 1 hundredth of a second in order to regularise the extreme edges of the wound (dog ear).



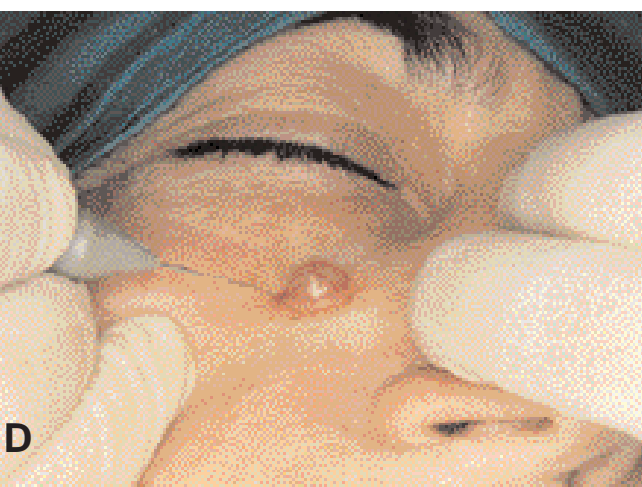
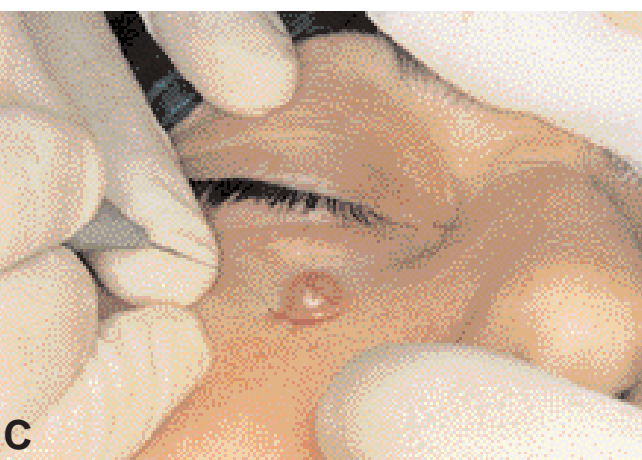
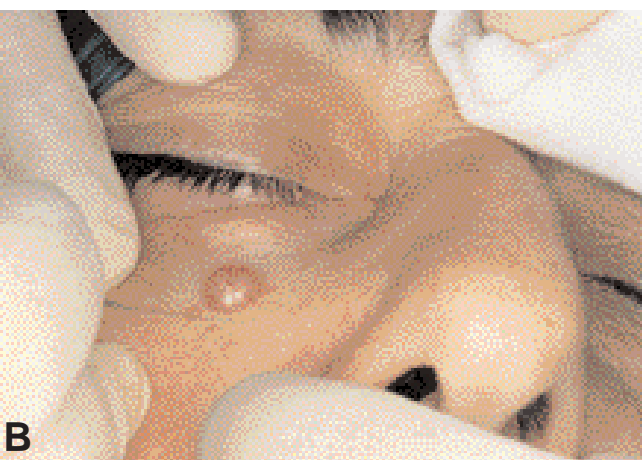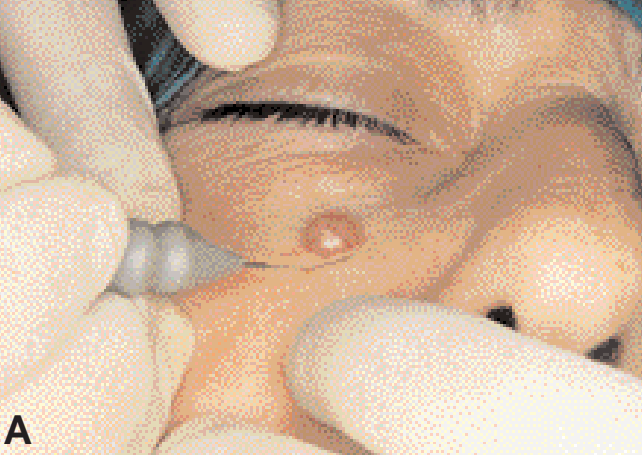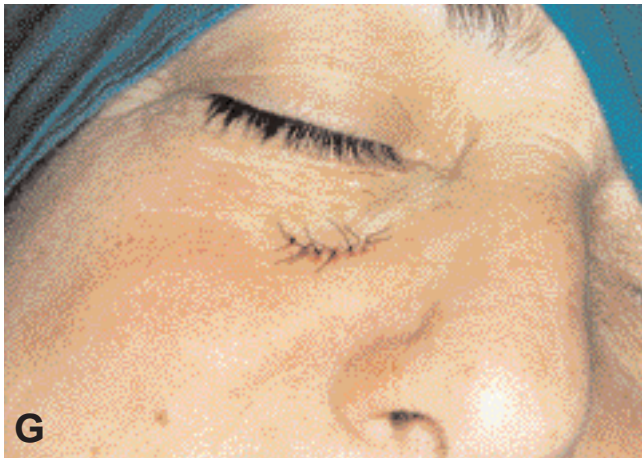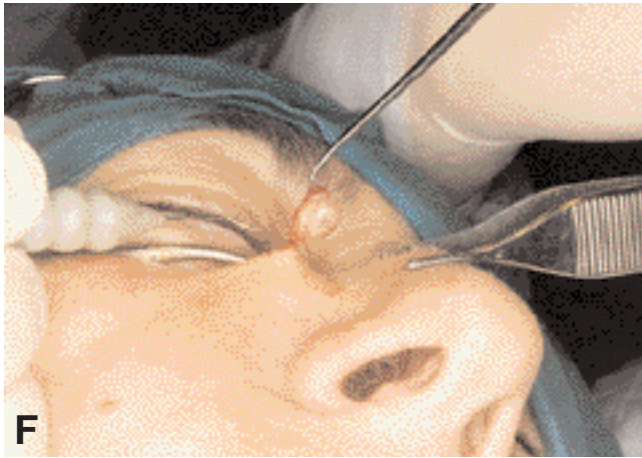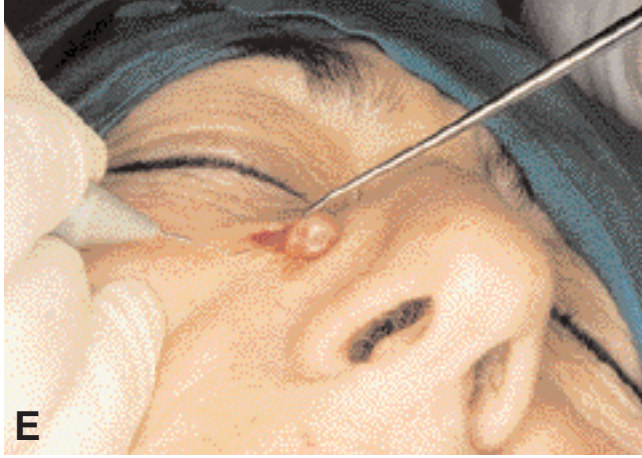Fig. 43.1.2 Excision of basal-cell carcinoma. **A)** The skin has been anaesthetised, the point of the **EM 10** electromanipulator is put under elastic pressure. **B)** The timed emission allows the point of the electromanipulator to straighten, thus cutting of the skin. Programme data: **cut, 38 Watts, 3 hundredths of a second, EM 10 Grey** electromanipulator. **C and D)** A series of timed cuts completes the skin cut; bleeding is less than with a scalped.

(see over)



E) The subcutaneous tissue is cut in the same programme. **F)** The excision is nearly complete. The operator must always bear in mind that the cut is produced by the few millimetres at the tip of the electromaniple, where the energy density is greatest. **G)** The wound is sutured. **H)** Marks disappear after a few days. Aesthetic results are good.

Technique

After positioning the neutral electrode and preparing the skin, the operator sets the Timed apparatus to the timed mode, emission time from **1 to 3 hundredths of a second** according to the length of the cut to be produced, the function to cutting and power to **38 or 50 Watts**. An **EM 10 White, Green or Grey** electromaniple is used. The finer the electromaniple, the finer the cut.

For micro-intervention the smallest diameter **EM 10 White** electromaniple is used.

The operator places the end few millimetres of the point in contact with the skin and flexes the electromaniple elastically, so that the extremity of the point is pointing in the opposite direction to which the cut is intended to proceed. A timed emission is generated and the immediate release of elastic tension straightens the point, thus cutting the tissue without causing burns at the edges. The cut is completed with a series of single timed emissions.

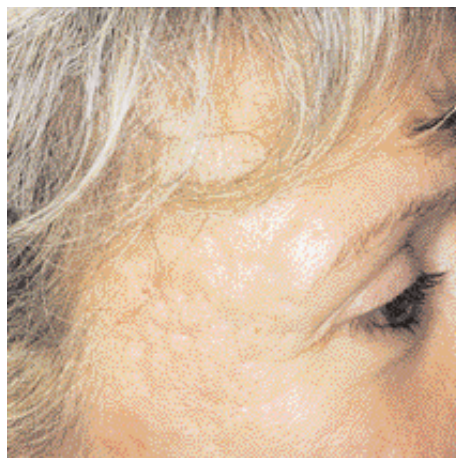
To remove a cutaneous lesion of 1.5 cm in diameter, the total emission time (i.e. the total time of activation of the electromaniple) is little over 1 second. The timed cut is precise and safe, seals venous and lymphatic capillaries and requires minimal pressure on the tissues (with an **EM 10 White** electromaniple, timed cutting is carried out with a pressure of about 5 grams).

When micro-excisions are to be carried out, slow pulsed cutting **0.5 / 24.5 hundredths of a second** is used (**Fig. 43.1.3**). When large excisions are to be carried out, rapid pulsed cutting **0.3 / 5.3 hundredths of a second** is used. This is implemen-

ted automatically by keeping the pedal of the generator pressed. In this case too, the electromaniple must be kept under elastic tension. The electromaniple constitutes a "scalpel" that is always perfectly sharp.

Timed or pulsed cutting is used for excisions and microexcisions, upper and transconjunctival blepharoplasty and also for the excision of pigmented neoformations.

The pulsed functions must be used in the direct mode.



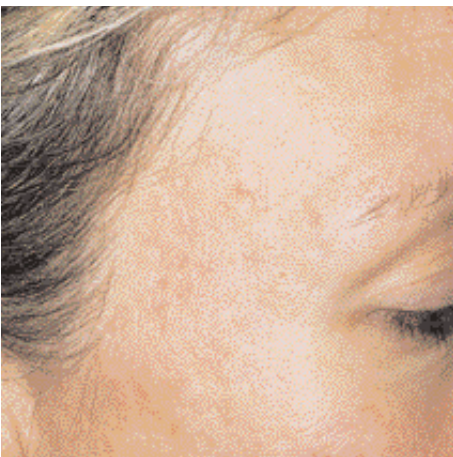
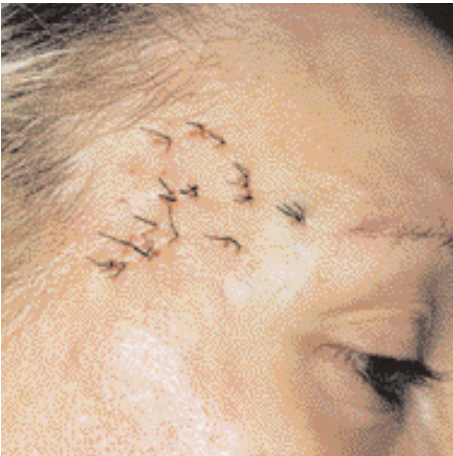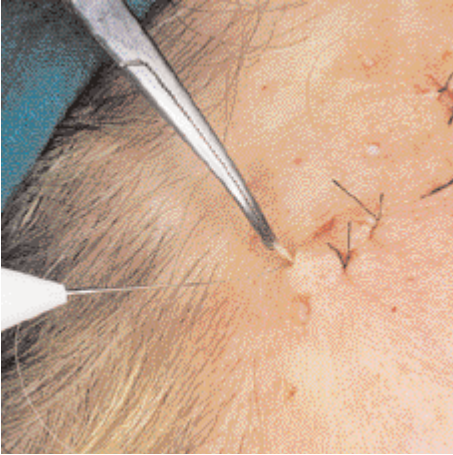


Fig. 43.1.3 Acne scars. Slow pulsed cutting enables the deepest scars to be excised easily, thus improving the patient's appearance in a very short time. Programme data: cut, 38 Watts, pulsed 0.5 / 24.5 hundredths of a second, EM 10 White electro-manipule. Local anaesthesia. Residual imperfections can be smoothed by means of one or more sessions of timed surgical resurfacing. Acne scars can also be incised along the edges and lifted.

43.2 Electroshaving

Programme data

**Timed 2 hundredths of a second
or Direct pulsed 0.5/24.5 hun-
dredths of a second - Cut - 38 or
50 Watts - EM 10 Grey**

Benign skin lesions raised above the skin surface may be excised by tangential timed or pulsed cutting, down to the level of the dermis: electroshaving.

Technique

The operator sets the Timed apparatus to the timed mode with an emission time of **2 hundredths of a second**, or to the **pulsed mode 0.5/24.5 hundredths of a second**.

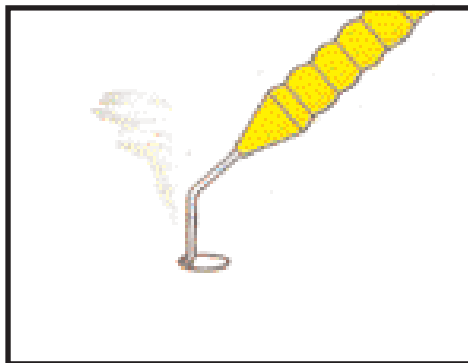
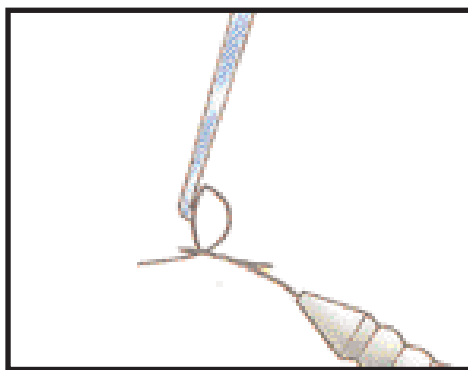
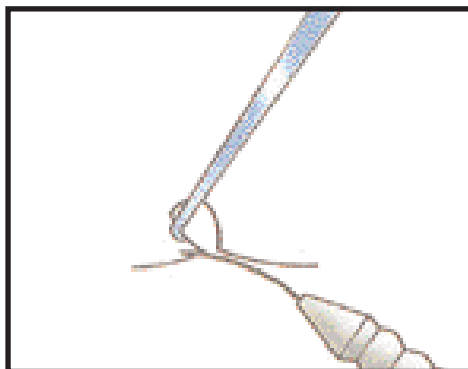
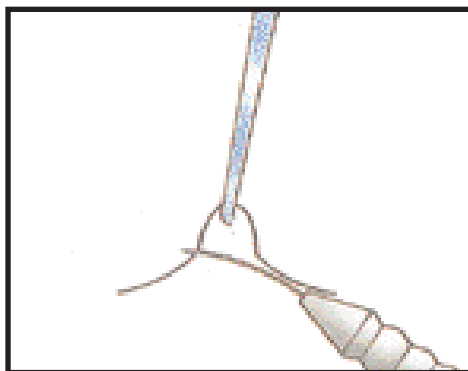
The function is set to cutting, the power to **38 or 50 Watts** and an **EM 10 White, Green or Grey** electromaniple is selected (**Fig. 43.2.1**). The lesion is gripped with forceps and lifted away from the skin surface.

The cut is effected within the thickness of the dermis. The specimen is suitable for histological examination, which must confirm complete excision of the lesion.

With timed surgical cutting, bleeding capillaries are sealed but, if a vessel of larger dimension is cut, this may need to be coagulated with an **EM 15** electromaniple.

The timed apparatus is set to the direct mode, the function to **coagulation with microelectrodes** and the power to **20 Watts**. The operator dries the field of operation with a gauze, places the tip of the electromaniple on the bleeding vessel and generates an emission for a few seconds (electrobliteration).

The exposed dermis is covered with a



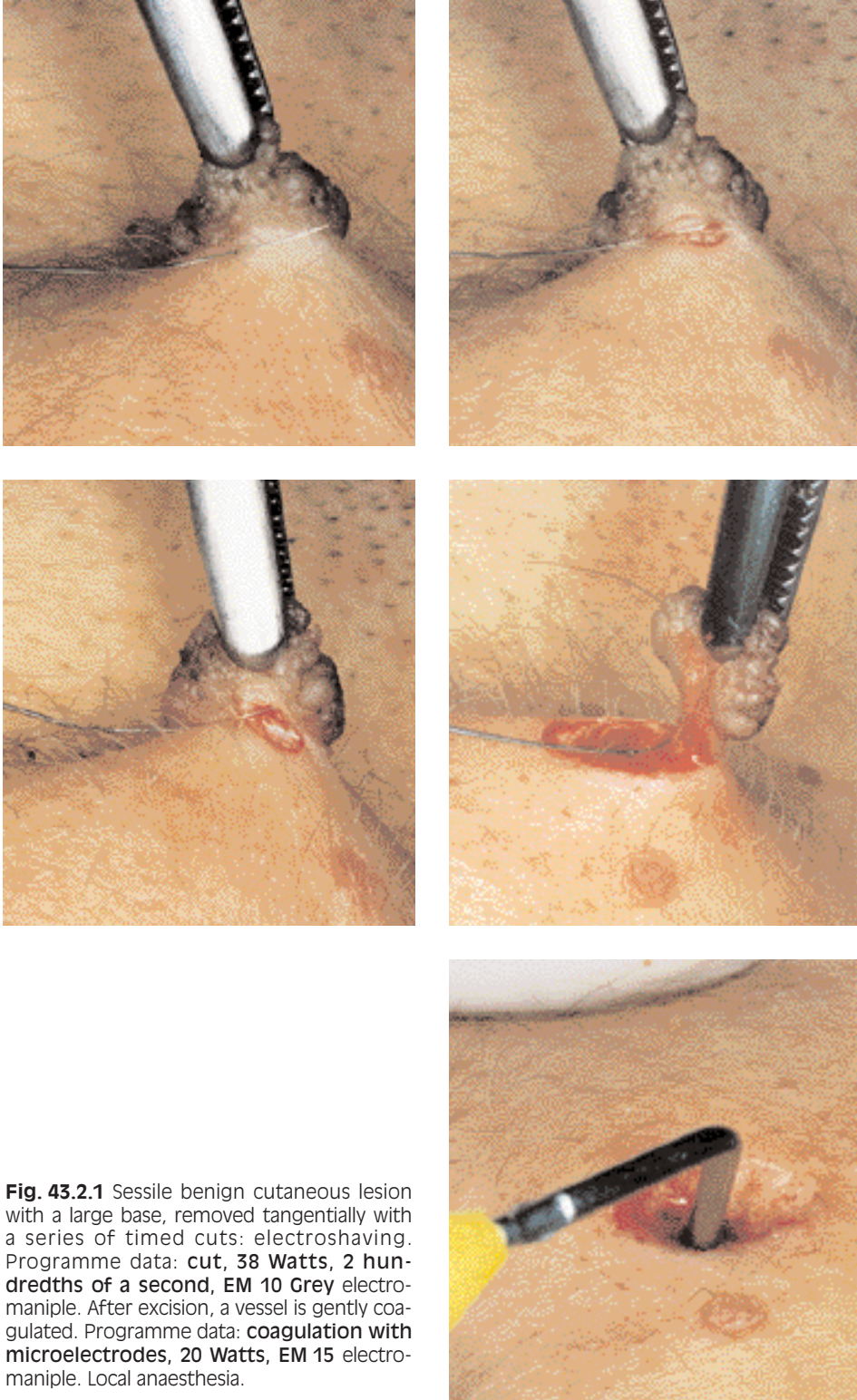


Fig. 43.2.1 Sessile benign cutaneous lesion with a large base, removed tangentially with a series of timed cuts: electroshaving. Programme data: cut, 38 Watts, 2 hundredths of a second, EM 10 Grey electro-manipule. After excision, a vessel is gently coagulated. Programme data: coagulation with microelectrodes, 20 Watts, EM 15 electro-manipule. Local anaesthesia.

non-adherent gauze or antiseptic cream or powder.

Electroshaving of benign lesions allows rapid treatment, at low cost. It is particularly indicated for the back, where scars left by traditional surgical excision may be conspicuous. There are no suture marks and there is no need for preparation of the field of operation, or other surgical instruments.

Electroshaving is used to remove sessile benign lesions on the border of the eyelid (see section 44.1).

The technique, which is carried out under local anaesthesia, consists of removing the lesion by means of timed or pulsed cutting (**0.5/24.5 hundredths of a second**), and coagulating any bleeding vessels at a power of **7 or 10 Watts**, with an **EM 15** electromaniple.

44 TIMED AND PULSED CUTTING IN EYELID SURGERY

Timed surgical cutting is particularly suitable for the excision of lesions on the eyelid. It provides a bloodless field and allows the operator to save as much healthy tissue as possible.

Timed or slow pulsed cutting is used in the most refined oculoplastic procedures; rapid pulsed cutting is used in upper blepharoplasty and transconjunctival blepharoplasty.

44.1 Excision of lesions on the eyelids

Programme data

Timed 2 hundredths of a second or Direct pulsed 0.5/24.5 hundredths of a second - Cut - 38 Watts - EM 10 White

After positioning the neutral electrode, the operator disinfects the skin and administers a local anaesthetic. The Timed apparatus is then set to the timed mode, emission time to **1 or 2 hundredths of a second**, or is set to the **pulsed mode 0.5/24.5 hundredths of a second**, the function to **cut** and power to **38 Watts**. The excision is performed as a series of micro-cuts using an **EM 10 White** or **Green** electromanipule.

The sutured wound rapidly heals (**Fig. 44.1.1-2**).

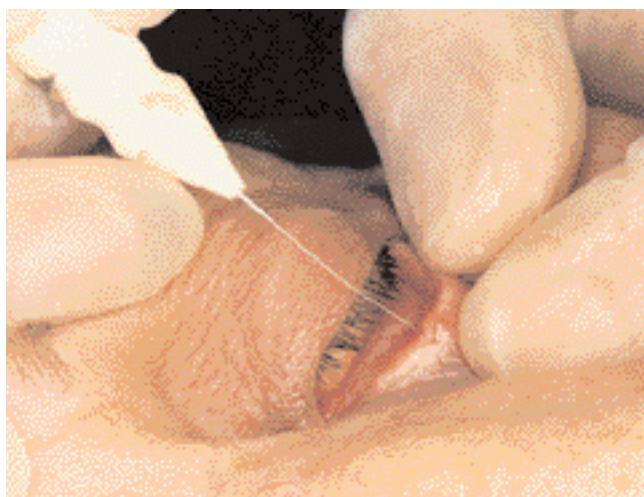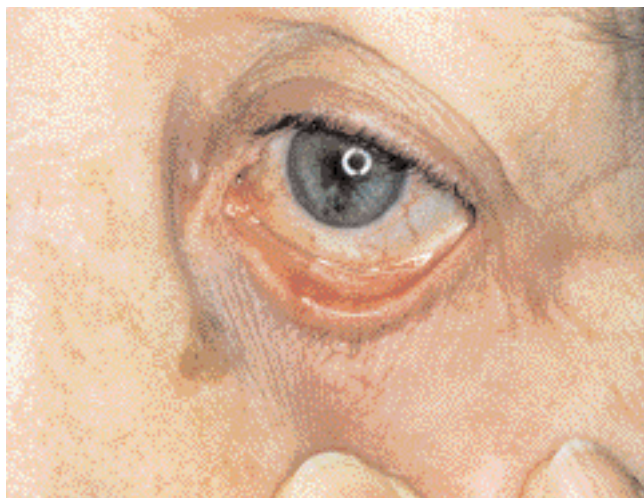
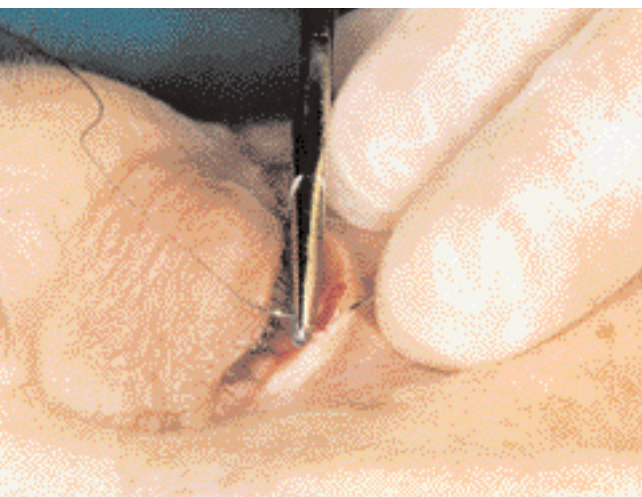
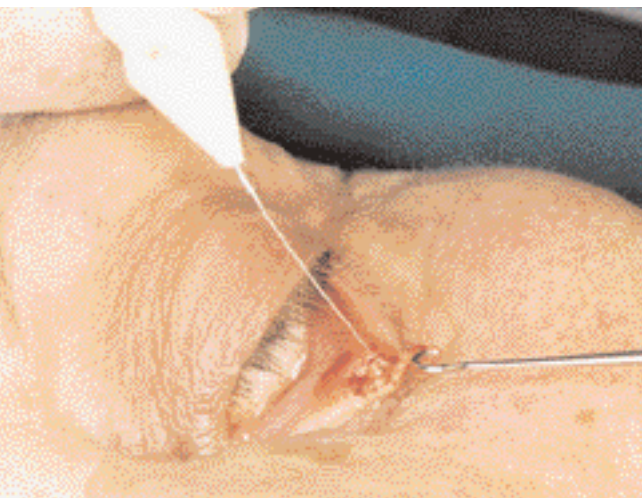

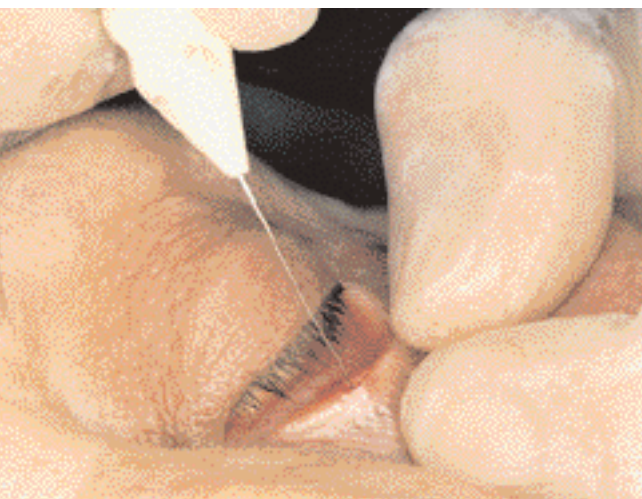
Fig. 44.1.1 Chalazion of the lower eyelid. Programme data: cut, 38 Watts, 2 hundredths of a second, EM 10 White electromanipule. Local anaesthesia.



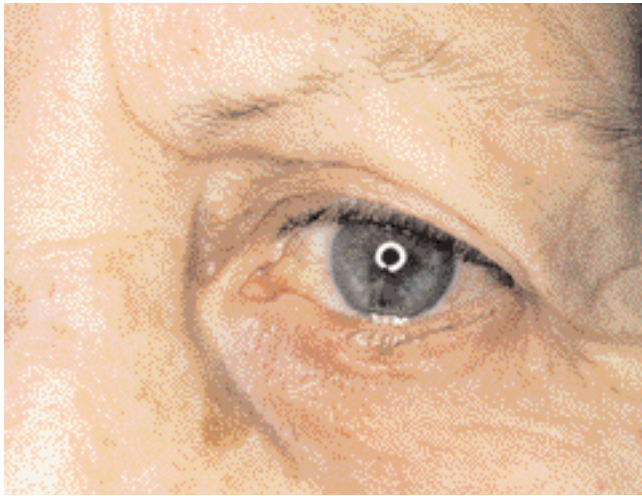
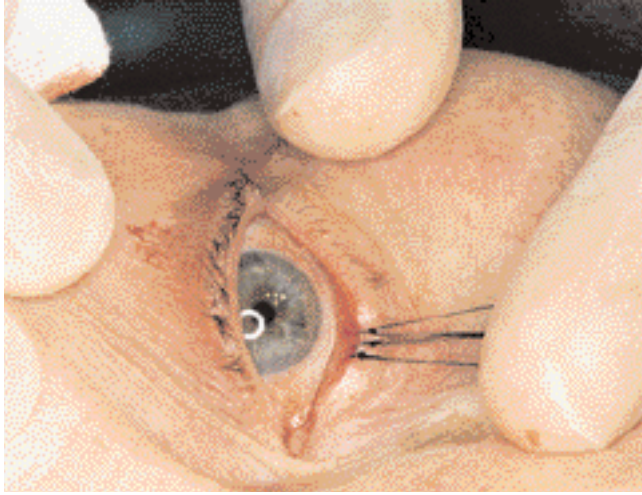


Fig. 44.1.2 The sutured tissue loss heals rapidly; the healing time is similar to that of an incision made by a surgical scalpel.

Owing to the particular anatomical structure of the region and the presence of eyelashes, benign lesions localised on the edge of the eyelid are preferably removed by electroshaving. The lesion is excised by means of a series of timed cuts, or by slow pulsed cutting, remaining within the thickness of the dermis. Once excision is complete, the Timed is reset to **coagulation with microelectrodes** and power reduced to **14 or 10 Watts**.

The operator then inserts an **EM 15** electromaniple and delicately coagulates the capillary vessels of the area. The procedure is rapid and almost bloodless. Healing is rapid and results are aesthetically superior to those obtained with full-thickness surgical excision followed by suturing: the eyelashes are largely preserved (**Fig. 44.1.3-5**).

Slow and rapid pulsed cutting are more precise than cutting with a scalpel (**Fig. 44.1.6-7**).

Timed micro-cuts can also be performed on the anterior surface of the eye (**Fig. 44.1.8**).

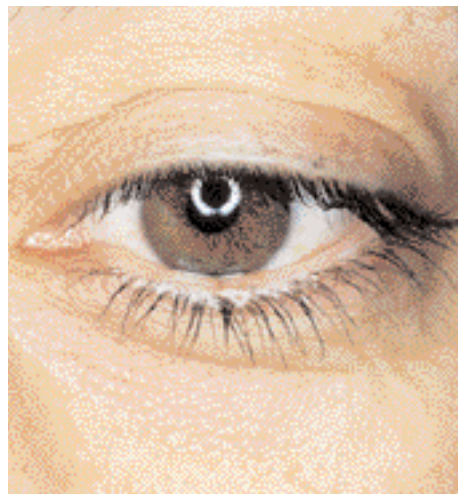
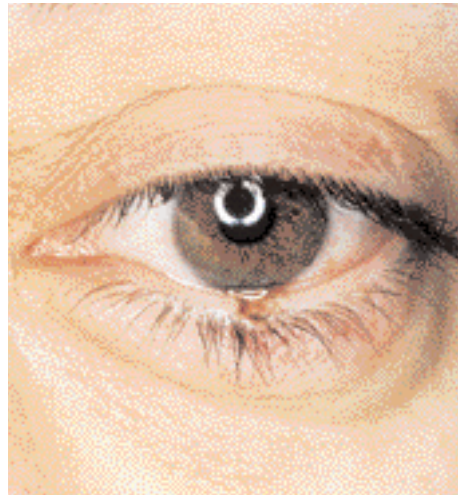
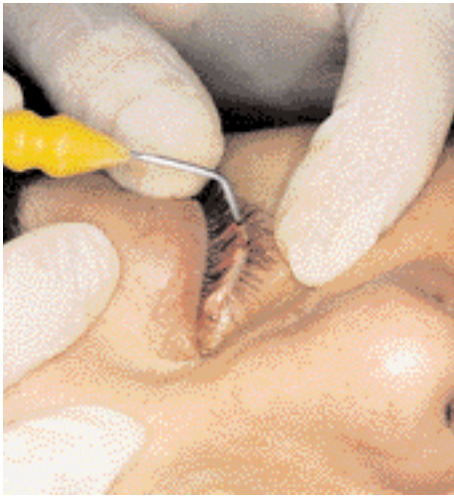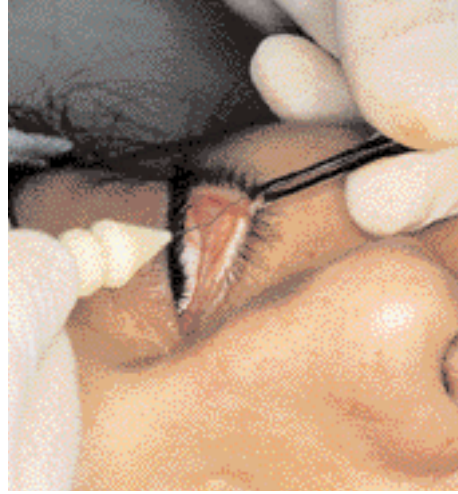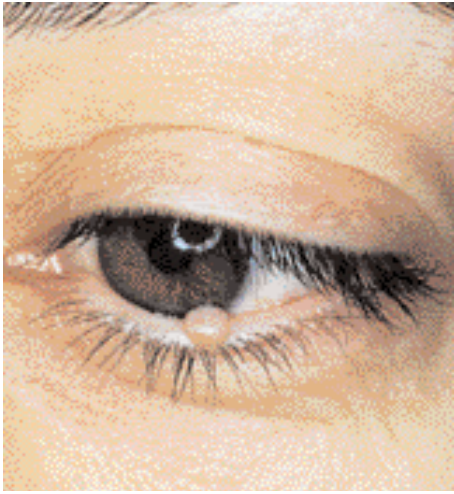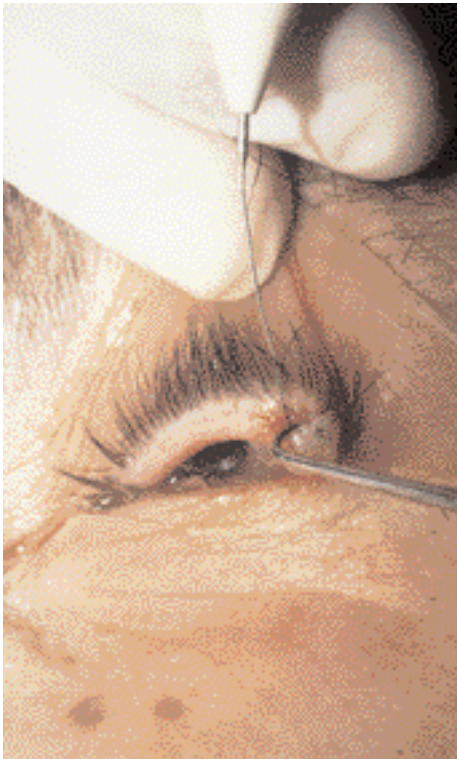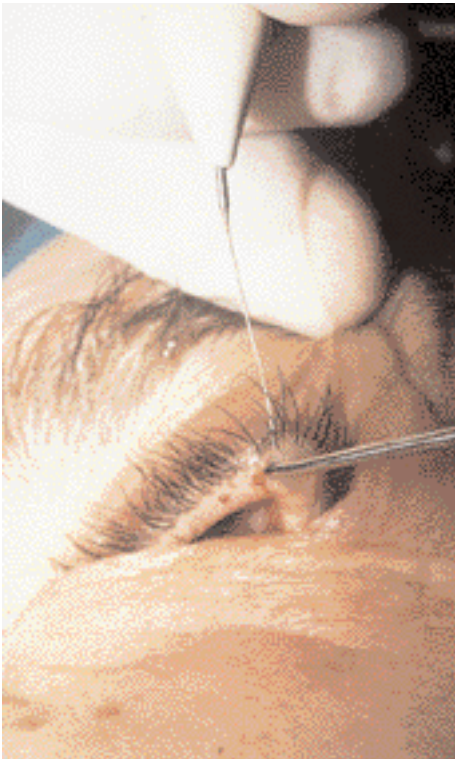
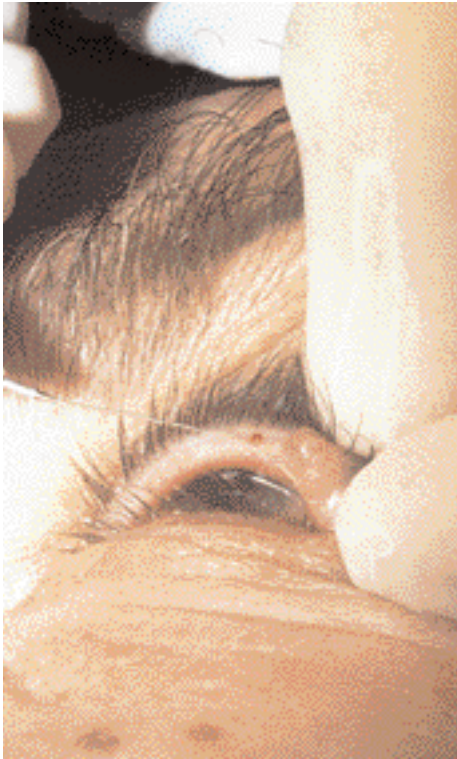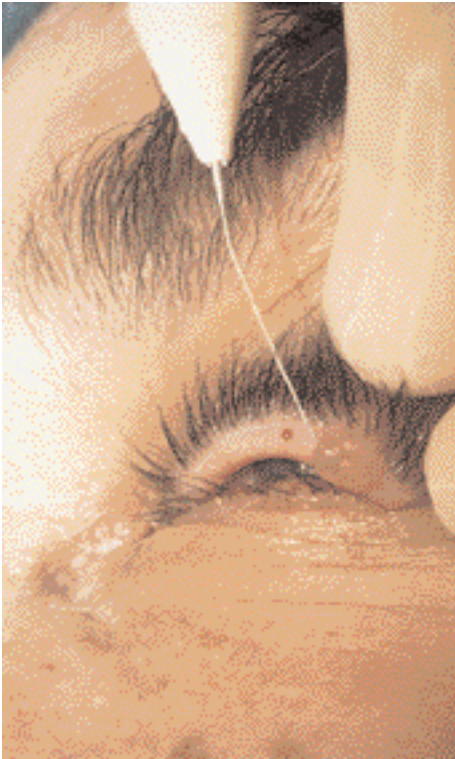


Fig. 44.1.3 Lesion on the edge of the lower eyelid. Programme data: cut, **38 Watts, 1 hundredth of a second, EM 10 White** electromaniple. Local anaesthesia. After electroshaving the area is superficially coagulated. Programme data: **coagulation with micro-electrodes, 14 Watts, EM 15** electromaniple.



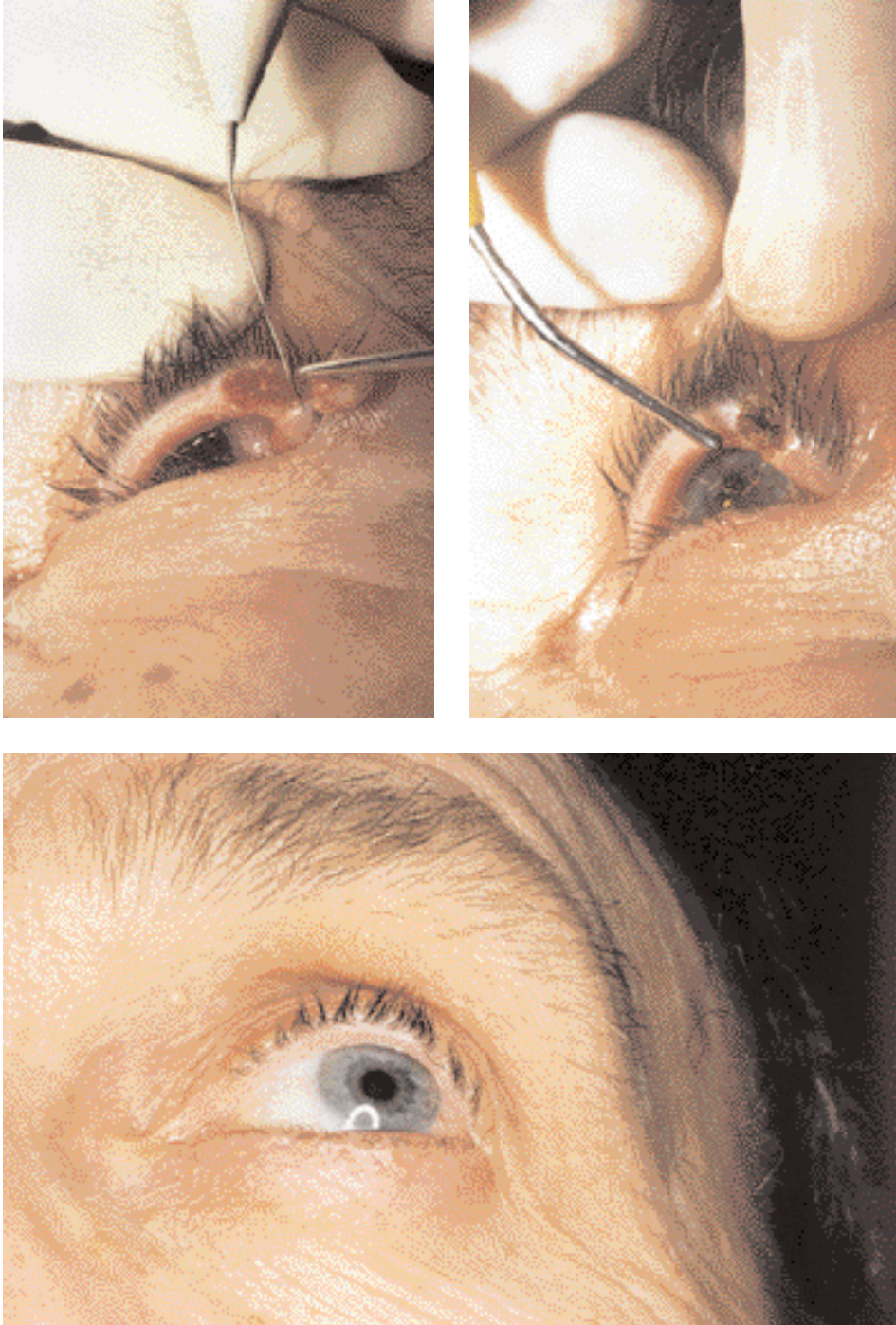


Fig. 44.1.4 Lesion on the edge of the upper eyelid. Programme data: cutting (cut), 38 Watts, 2 hundredths of a second, EM 10 White electromaniple. Local anaesthesia. After electroshaving, the area is superficially coagulated. Programme data: coagulation with micro-electrodes, 14 Watts, EM 15 electromaniple.

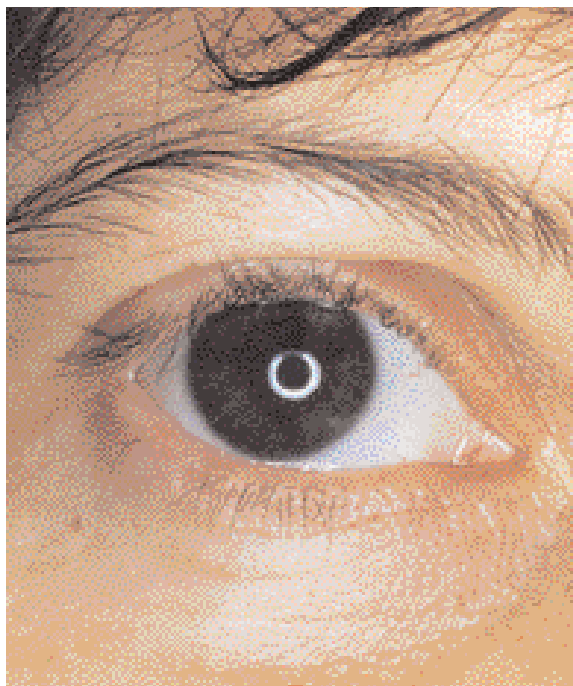
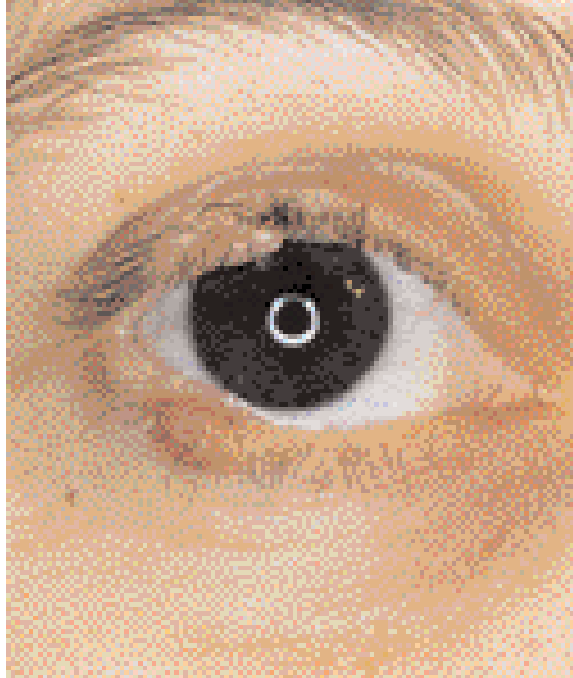


Fig. 44.1.5 Electroshaving of two neoformations on the eyelids. Programme data: cutting (cut), 50 Watts, pulsed 0.5/24.5 hundredths of a second, EM 10 White electromaniple. Local anaesthesia. Excision is followed by haemostasis. Programme data: coagulation with microelectrodes, 14 Watts, EM 15 electromaniple.

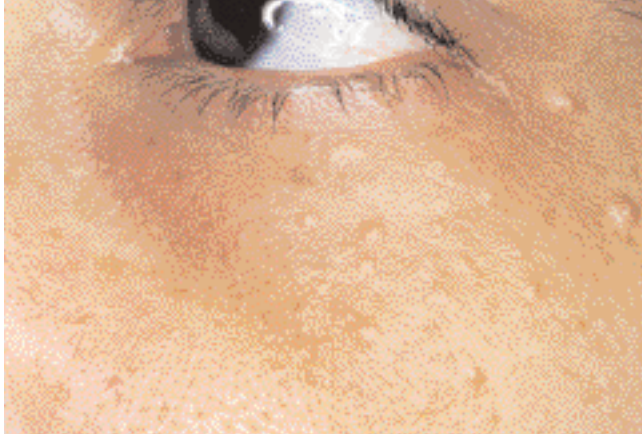

Fig. 44.1.6 Eyelid syringomas excised by means of slow pulsed cutting. Programme data: cutting (cut), 38 Watts, pulsed 0.5/24.5 hundredths of a second, EM 10 White electromaniple. Local anaesthesia.

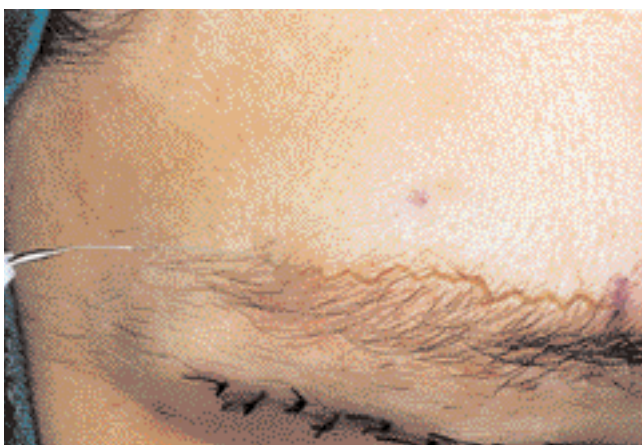
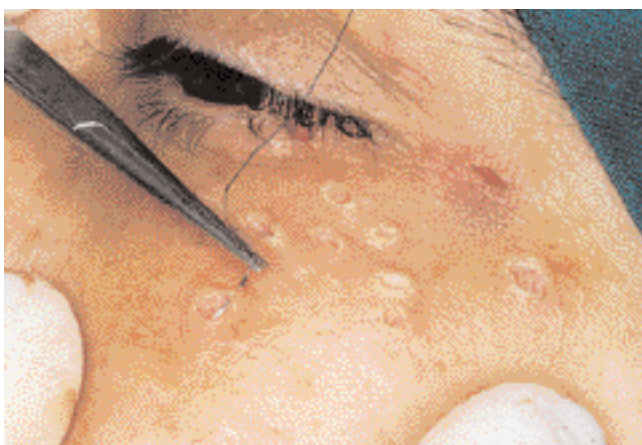
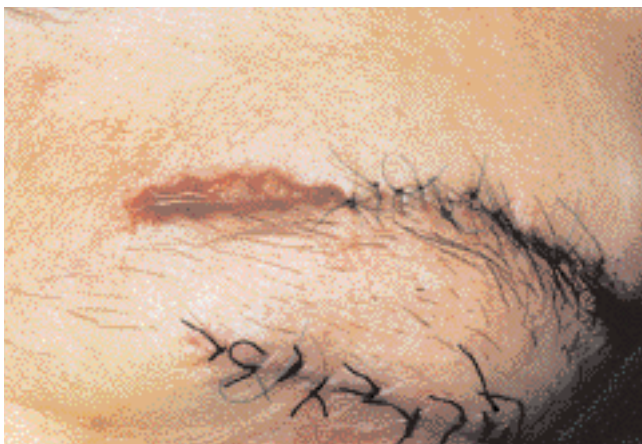
Fig. 44.1.7 Rapid pulsed cutting used to raise an eyebrow. Programme data: cutting (cut), 27 Watts, pulsed 0.3/5.3 hundredths of a second EM 10 White electromaniple . Local anaesthesia. The "W" cut maintains the natural pattern of eyebrow hairs. Timesurgical resurfacing can be performed after two months.



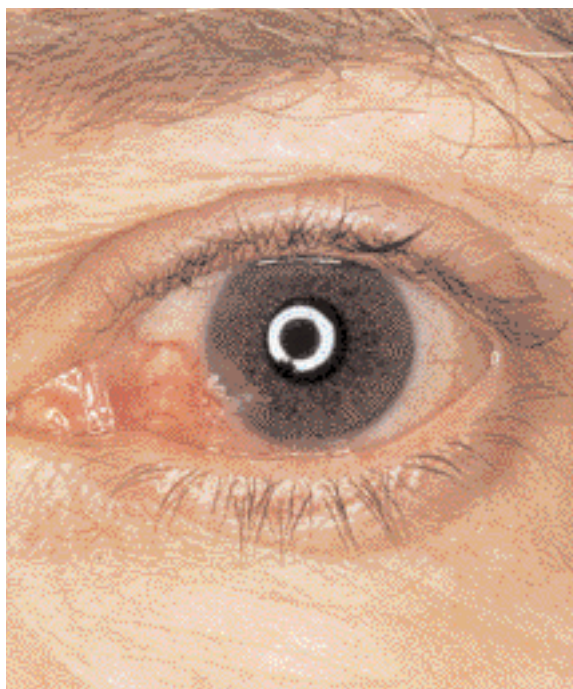
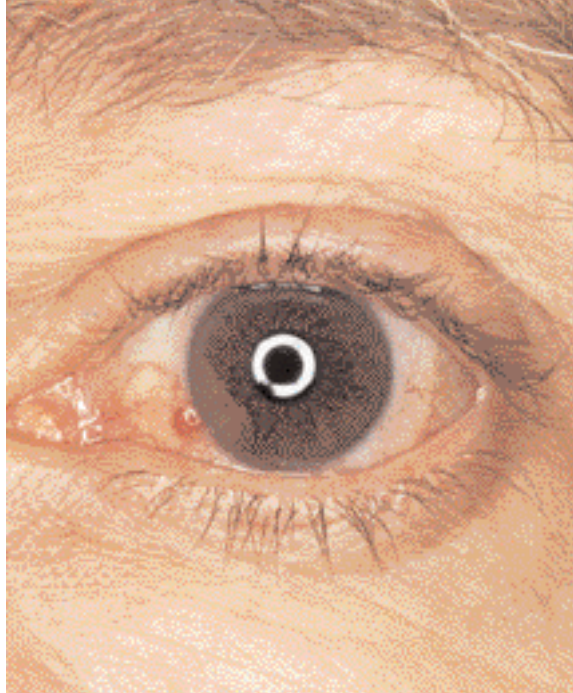


Fig. 44.1.8 Small angioma (top). Programme data: cutting (cut), 10 Watts, 0.3 hundredths of a second, EM 10 White electro-manipule. Topical anaesthesia. Immediately after the excision (bottom). On the conjunctiva the healing of a timed cut is very rapid.

44.2 **Blepharoplasty of the upper lid**

Programme data

Direct pulsed 0.3/5.3 hundredths of a second - Cut - from 27 to 72 Watts - EM 10 White

Rapid pulsed cutting is used for the entire upper blepharoplasty procedure: skin incision, excision of skin and muscle, removal of fat, and haemostasis (**Fig. 44.2.1**). The advantages of this technique are illustrated in Tab. 44.1.

Once the operating field has been disinfected and local anaesthesia (2% or 3% mepivacaine with epinephrine) administered, the Timed apparatus is set to the **cut** function, the power to **38 Watts** and the mode to direct rapid pulsed cutting **0.3 / 5.3 hundredths of a second**. An **EM 10 White** electromaniple is used.

The operator is able to trace the skin incision very accurately with the tip of the electromaniple, as the fine point does not obscure his view and the skin is not distorted, as occurs under the pressure of a surgical

scalpel. When the incisions have been completed, the power is set to **50 Watts**. The skin and muscle tissue are removed, the orbital septum is opened and the yellow fat excised. Finally, the medial pocket is opened and the white fat is excised. Rapid pulsed cutting enables fine strips of muscle to be removed and the external corner and edges of the wound to be carefully modelled. (**Fig. 44.2.1**). Haemostasis of the vessels is achieved by touching the thickest portion of the electromaniple with a pair of watchmaker's tweezers. If a greater haemostatic effect is required during excision, the **EM 10 White** electromaniple is moved more slowly or the power is set to **72** or **100 Watts**. Unlike laser operations, hesitation or hand tremors have little effect on the line of the cut.

The skin incision is sutured with 6-0 silk stitches, which remain in place for 3 days. An hour after the procedure, the patient is allowed to go home. The procedure enhances the system of raising the eyelids (**Fig. 44.2.2-3**).

Tab. 44.1 Advantages of rapid pulsed timed surgical cutting

Compared with a surgical scalpel	Compared with the laser
Intervention is quicker, more precise, easier and safer	Intervention is quicker, more precise, easier and safer
Less bleeding	Less tissue damage
Better visibility	Much more rapid healing
Easier removal of deep bags	Better quality scars
Less tissue damage	Easier removal of deep bags
Less post-operative pain	No skin burns
Better quality scars	Millimetric corrections can be made.

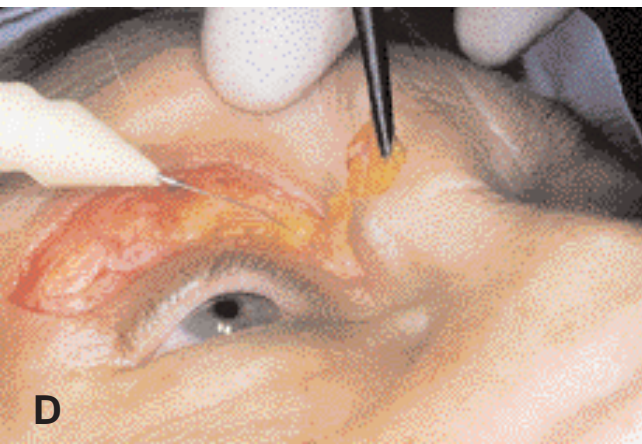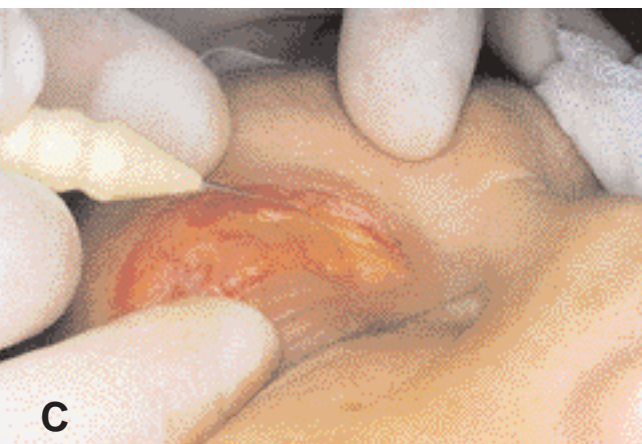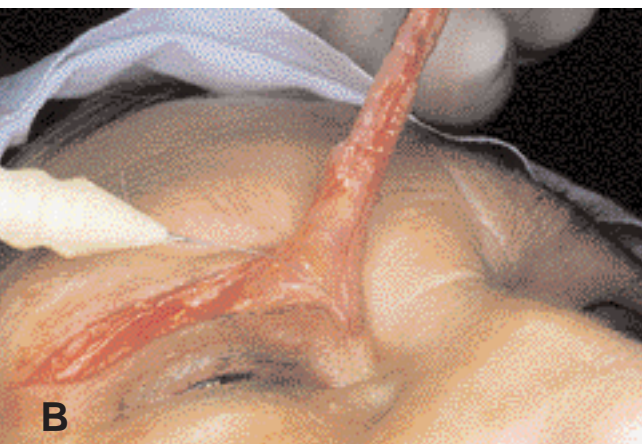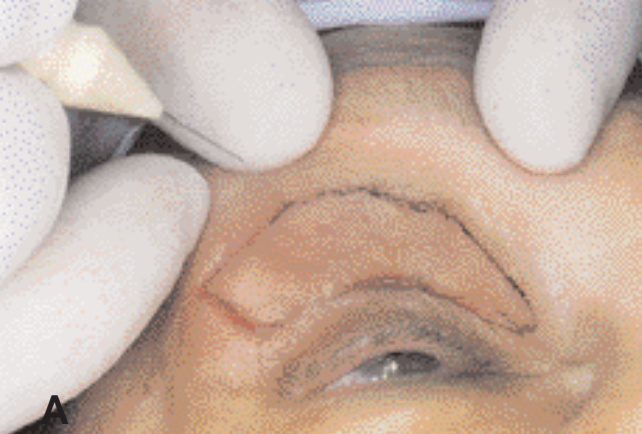
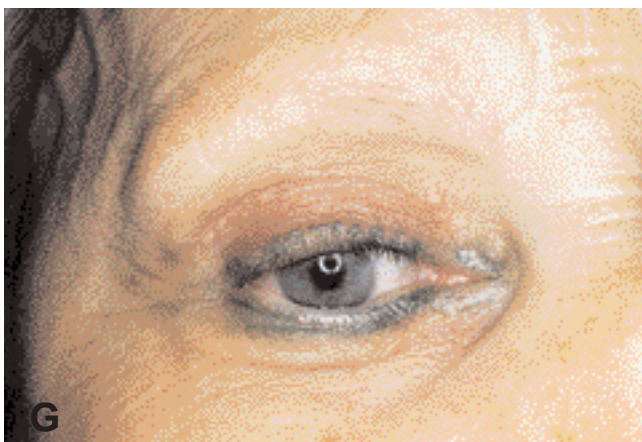
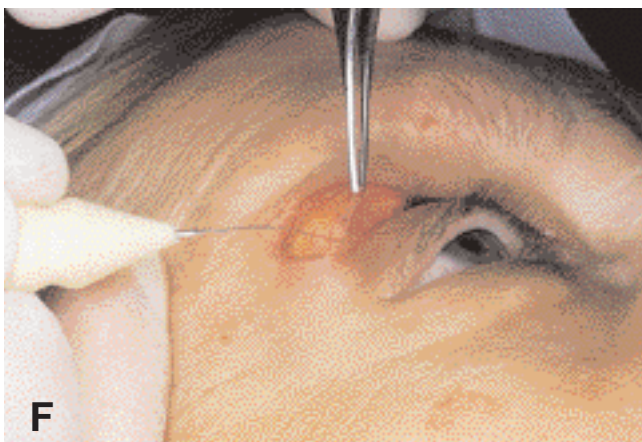
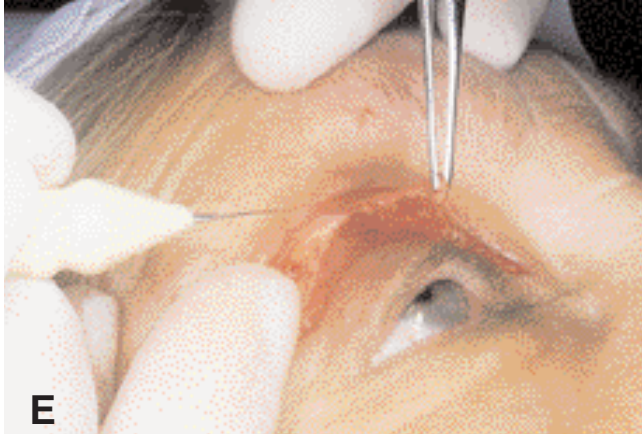


Fig. 44.2.1 Upper blepharoplasty by means of rapid pulsed timed surgical cutting. **A)** the fine tip of the electromanipulator enables the outline to be traced very accurately. The negligible pressure exerted during cutting does not distort the skin. Programme data: cutting (cut), **38 Watts, pulsed 0.3/5.3 hundredths of a second, EM 10 White** electromanipulator. Local anaesthesia. **B)** The power is increased to **50 Watts**. The skin and orbicular muscle are removed.

If the orbit is sufficiently large, only the medial portion of the orbicular muscle below the design is removed. By means of timed-surgical cutting, the residual portion of the muscle is easily lifted from below and is used to augment the superexternal region of the eyelid. This gives the patient a softer, more youthful gaze. **C)** The orbital septum is opened. **D)** The adipose tissue (yellow and white fat) is removed. To achieve good definition of the palpebral sulcus and to prevent recurrence, the bags must be completely removed. This procedure has a functional, as well as aesthetic purpose.

(see over)



E) Pulsed cutting enables the operator to smooth the base and edges of the wound by accurately removing strips of muscle. **F)** Particular attention is paid to the lateral corner. **G)** Stitches can be removed after three days. Healing is rapid and the scar is of very good quality. Hypertrophy of the scar, which is often encountered in this region after cutting with a traditional scalpel, does not occur.

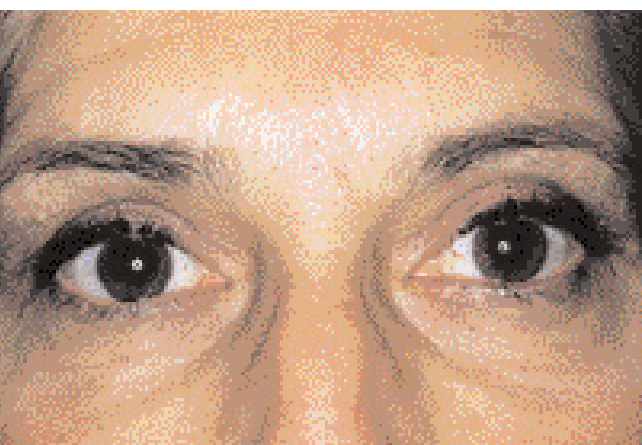
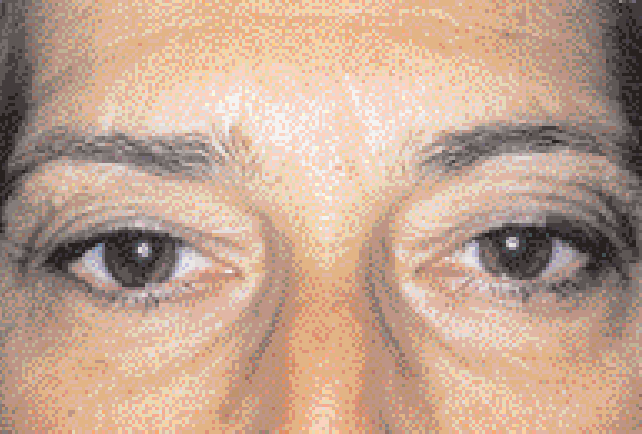
Fig. 44.2.2 Upper blepharoplasty by means of rapid pulsed cutting. Complete removal of the bags and excess tissue enhances the system of raising the eyelids, and the eyes appear bigger. Local anaesthesia.

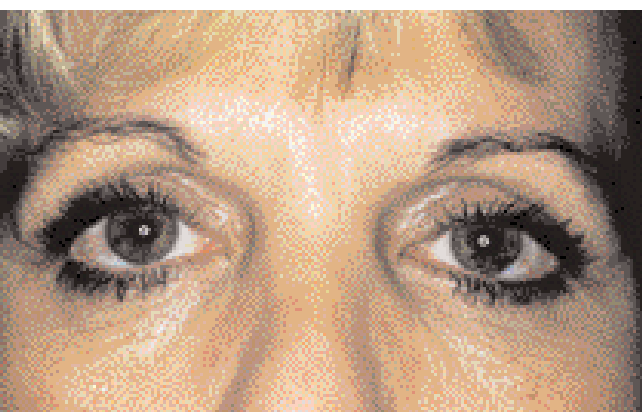
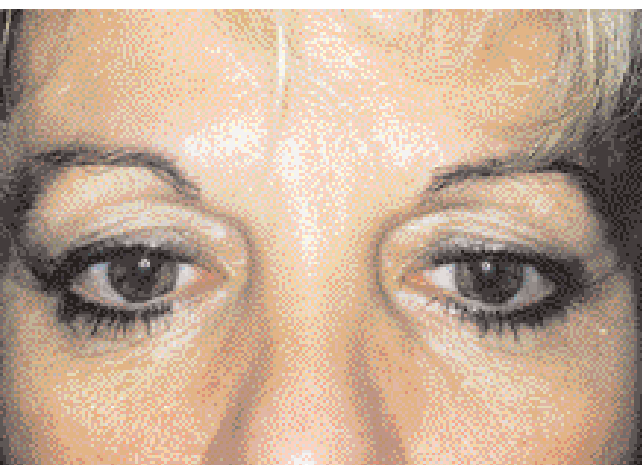
Fig. 44.2.3 Upper blepharoplasty by means of rapid pulsed cutting. Local anaesthesia.

44.3 Transconjunctival lower blepharoplasty

Programme data

Direct pulsed 0.3/5.3 hundredths of a second, - 50 or 72 Watts - Cut - EM 10 White

Rapid pulsed 0.3 / 5.3 hundredths of a second timed surgical cutting at **50 or 72 Watts** is also used to incise and remove fat bags in transconjunctival lower blepharoplasty (**Fig. 44.3.1**).

After administering local anaesthesia (2% or 3% mepivacaine with epinephrine) and waiting until vasoconstriction sets in, the operator uses an **EM 10 White** electromanipulator to make two incisions of about 1 cm, one in the lateral adipose compart-

ment and the other in the medial compartment. These incisions will be made 2 mm below the tarsus. Slight pressure on the eye-ball causes protrusion of the fat, which is then grasped with forceps and excised. Deep-seated bags can be exposed by scraping back the tissues with a fine klemmer. If great care is exercised in removing the three compartments of fat, there will be no need to repeat the procedure. Cuts in the mucosa are not sutured, and heal in a few days (**Fig. 44.3.2**). If the patient's skin is wrinkled, the area may be treated by means of timed surgical pulsed de-epithelialisation at **1 Watt**, followed by a very brief application of resorcin solution (see fig. 24.3.4).

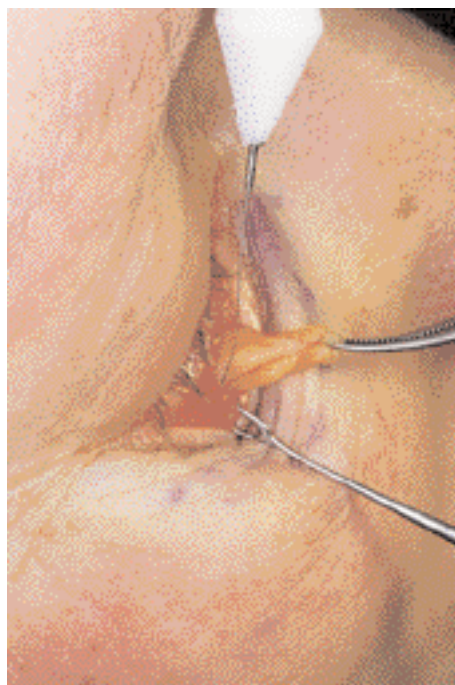


Fig. 44.3.1 Transconjunctival blepharoplasty. Removal of the adipose bag. Programme data: cutting (cut), **50 Watts, pulsed 0.3/5.3 hundredth of a second, EM 10 White** electromanipulator. Local anaesthesia.

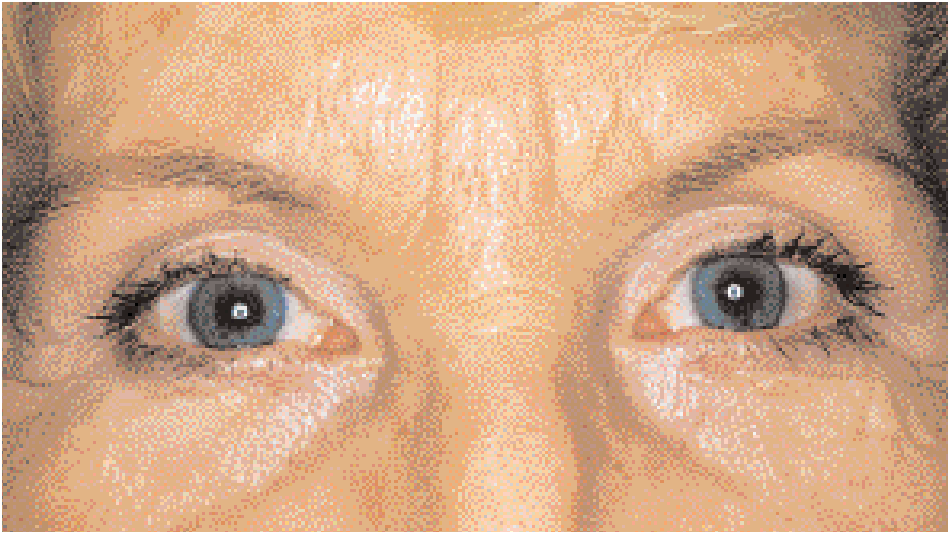
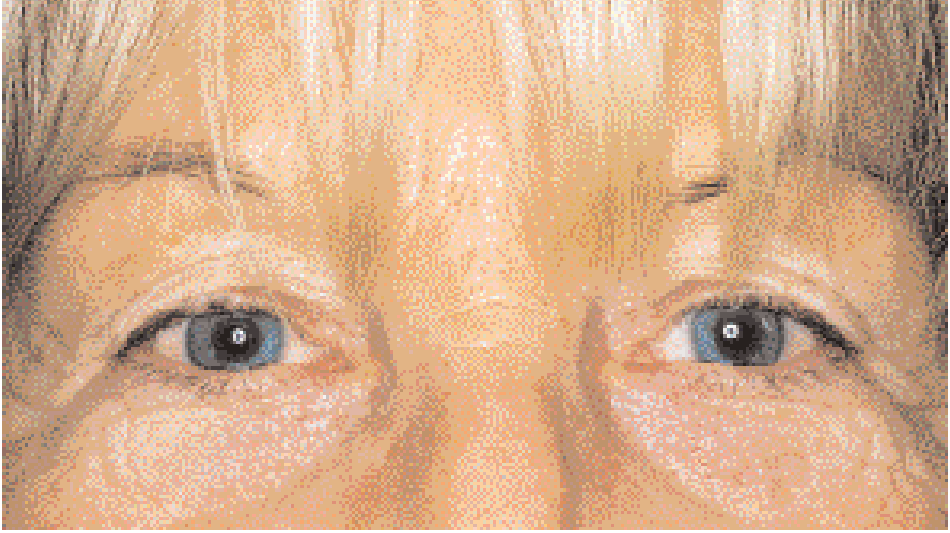

Fig. 44.3.2 Upper blepharoplasty and transconjunctival lower blepharoplasty by means of rapid pulsed timed surgical cutting. Local anaesthesia.

45

TIMED AND PULSED CUTTING IN ORAL SURGERY

Programme data

**Timed 2 hundredths of a second
or Direct pulsed 0.5/24.5 or
0.3/5.3 hundredths of a second -
Cut - 38 Watts - EM 10 Green.**

Timed or pulsed cutting is used in numerous oral surgery procedures, for removal of malignant and pre-malignant growths, fibromas, papillomas and angiomas and in periodontics (gingivectomy), preventive treatments (reduction of gingival collar etc.) and in preprosthesis and prosthesis surgery.

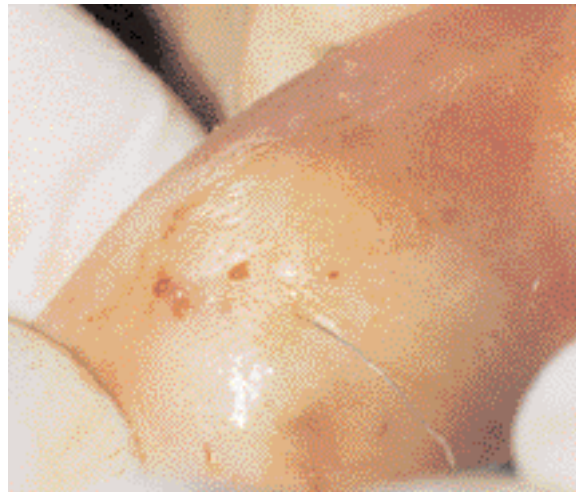
The wound heals in a few days without scar retraction and does not require a periodontal compress.

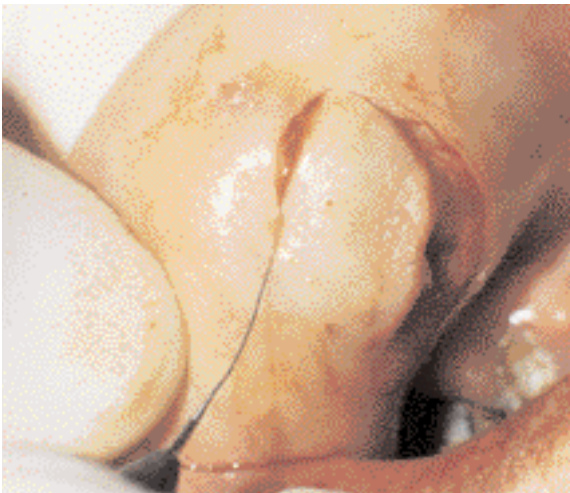
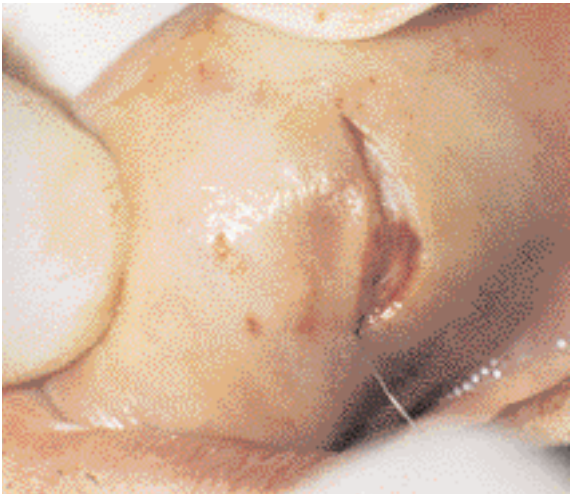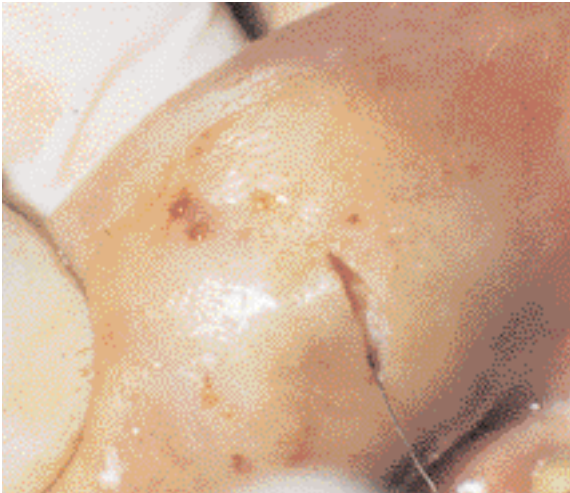
45.1 Technique

For micro-intervention, which can be carried out with extreme precision, the operator sets the generator to the timed function and regulates the emission time control to **2 hundredths of a second** or to the **pulsed mode 0.5/24.5 hundredths of a second**. The device is set to cutting, power to **38 watts** and an **EM 10 Green** or **White** electromanipule is fitted.

For larger cuts, the rapid **pulsed** function can be used **0.3/5.3 hundredths of a second**.

For correct cutting, it is necessary to aspirate any saliva in order to





reduce dispersion of the high-frequency current. With timed or pulsed cutting it is possible to expose dental roots and root remnants, to perform frenulectomies, incisions to provide surgical access, and to remove pedunculated and non-pedunculated fibromas (**Fig. 45.1.1**), the latter being often caused by ill-fitting prostheses. The technique allows precision and haemostasis in every procedure.

Timed cutting solves problems associated with the management of caries adjacent to the gingival margin (**Fig. 45.1.2**).

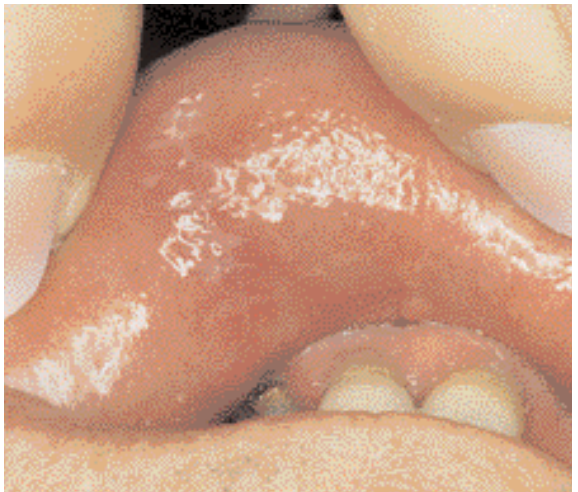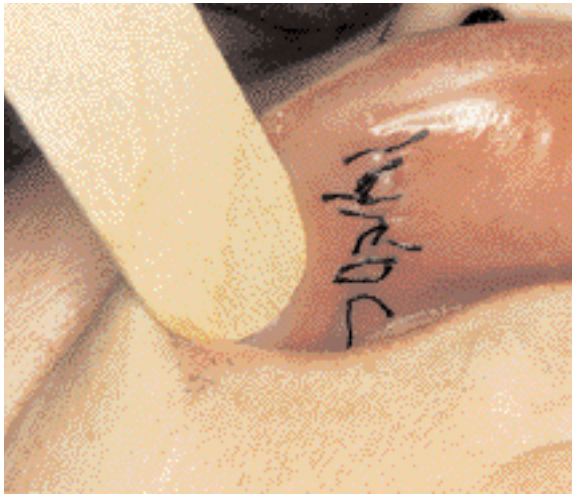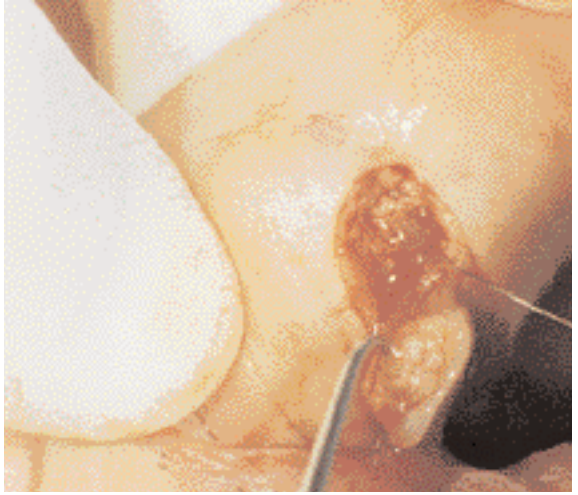
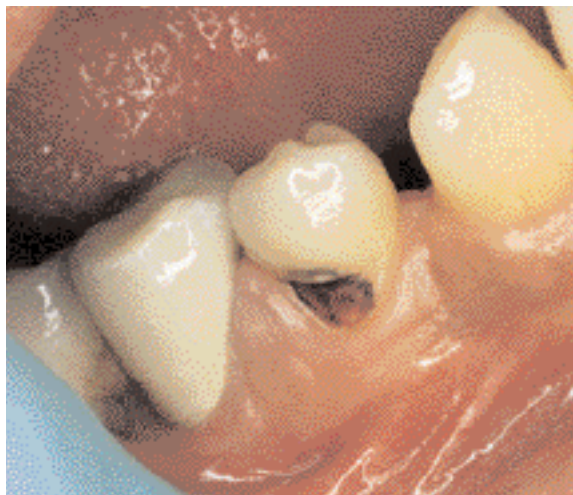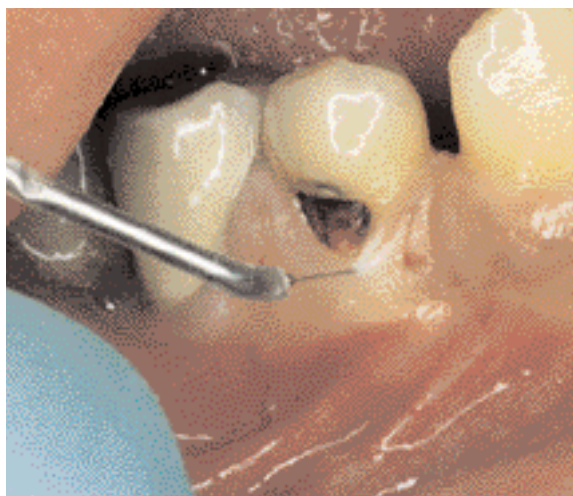
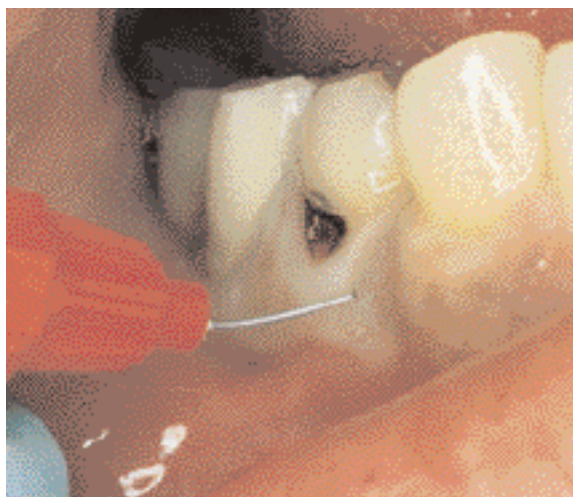


Fig. 45.1.1 Fibroma of the upper lip. Programme data: cut, 38 Watts, 2 hundredths of a second, EM 10 Green electro-manipule. Local anaesthesia. The excision is bloodless.



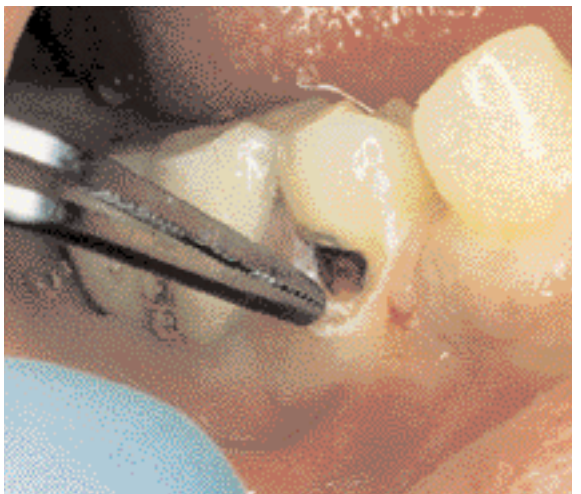
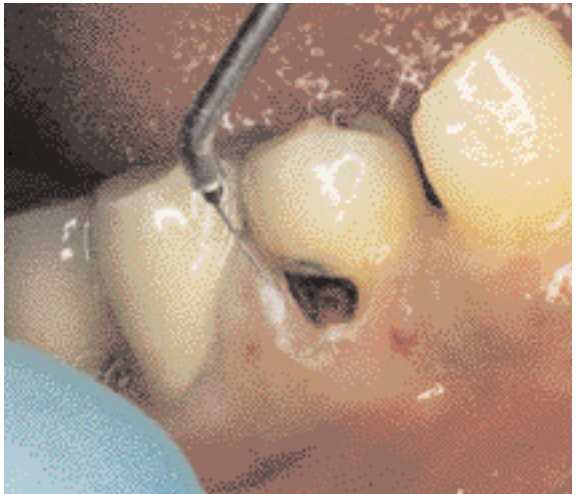
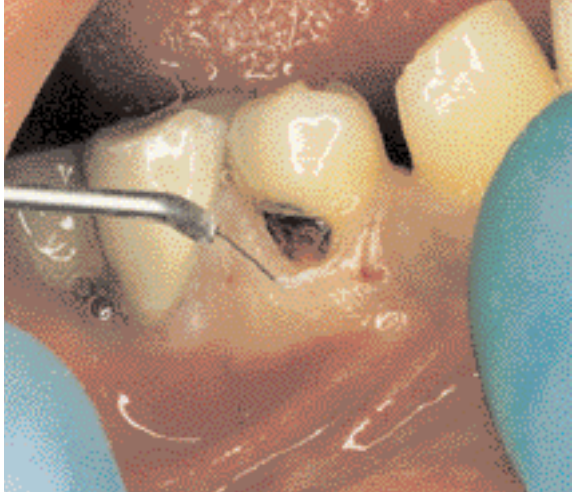
A horizontal segment of margin of the gum can be excised with extreme precision, without difficulty or the risks that accompany traditional electrosurgical cutting (Brunamonti 1991). In addition to the ease of cutting there is no fear of causing burns which can lead to marginal retraction of the gum. The bloodless field renders immediate restoration of the tooth possible.

In periodontics microcutting, with electromaniples for oral application, enables perfect gingivectomy to be executed even in areas with difficult access, such as between the teeth.



In this way the natural festooned form of the edge of the gum is maintained, and pockets above the bone, pseudo-pockets and gingival hypertrophy are eliminated. The point of the electromaniple is positioned 1 or 2 mm below the edge of the gum and inclined at about 45 degrees to the plane of the excision in the direction of the crown.

To widen the gingival sulcus, it is preferable to use timed surgical peeling at **5 Watts** with a **pulsed** emission at **4/9 hundredths of a second** and an **EM 10 Yellow** electromaniple.



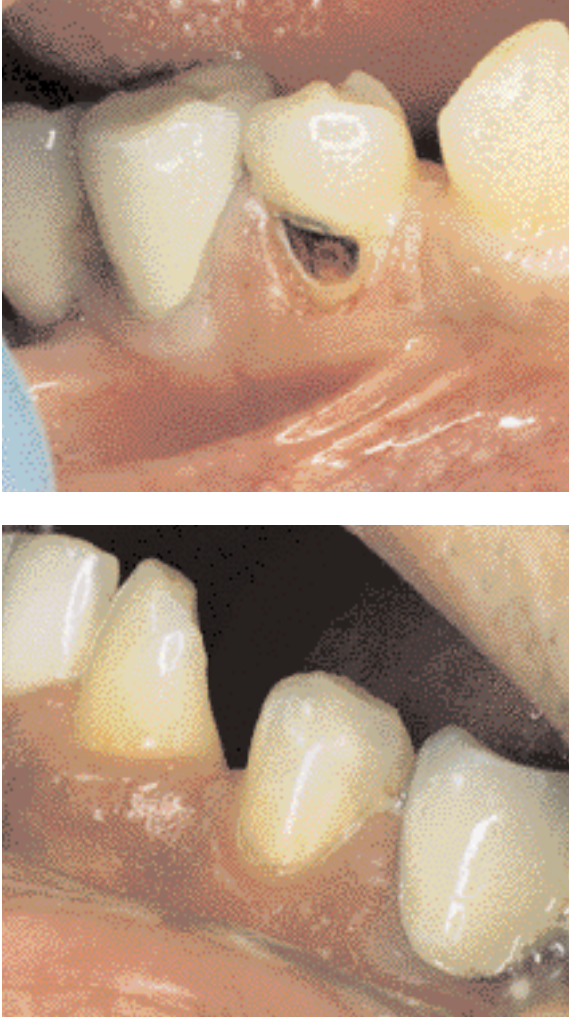


Fig. 45.1.2 Marginal caries. Excision of a strip of mucosa. Programme data: cut, 38 Watts, 2 hundredths of a second, EM 10 Green electromaniple. Local anaesthesia. The timed cut allows access for repair of the cavity.

46

EXCISION OF PEDUNCULATED AND LIFTABLE LESIONS

Programme data

Timed from 5 to 15 hundredths of a second - Cut - 38 or 50 Watts - EM 10 Grey

Pedunculated lesions are excised without anaesthetic with the maximum safety by means of timed cutting (**Fig. 46.0.1-2**).

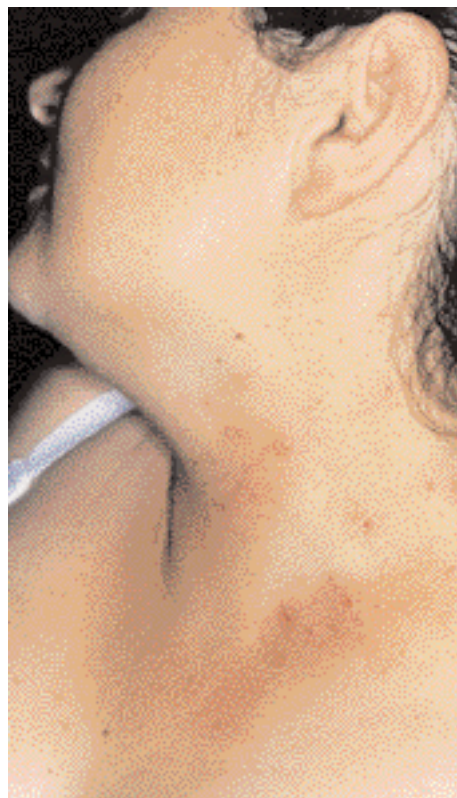
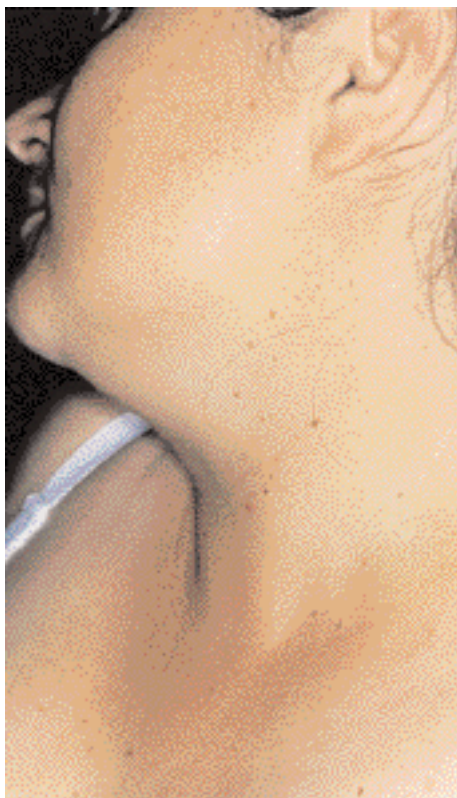
Fig. 46.0.1 Soft fibromas. Programme data: cut, 38 Watts, 10 hundredths of a second, EM 10 Grey electromanipule.

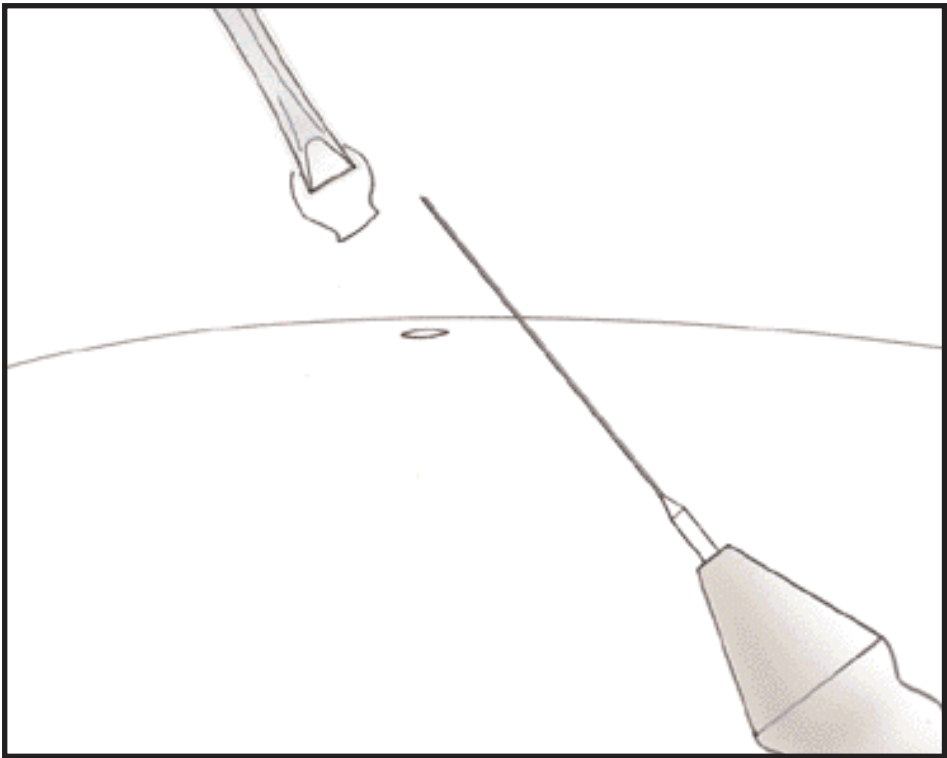
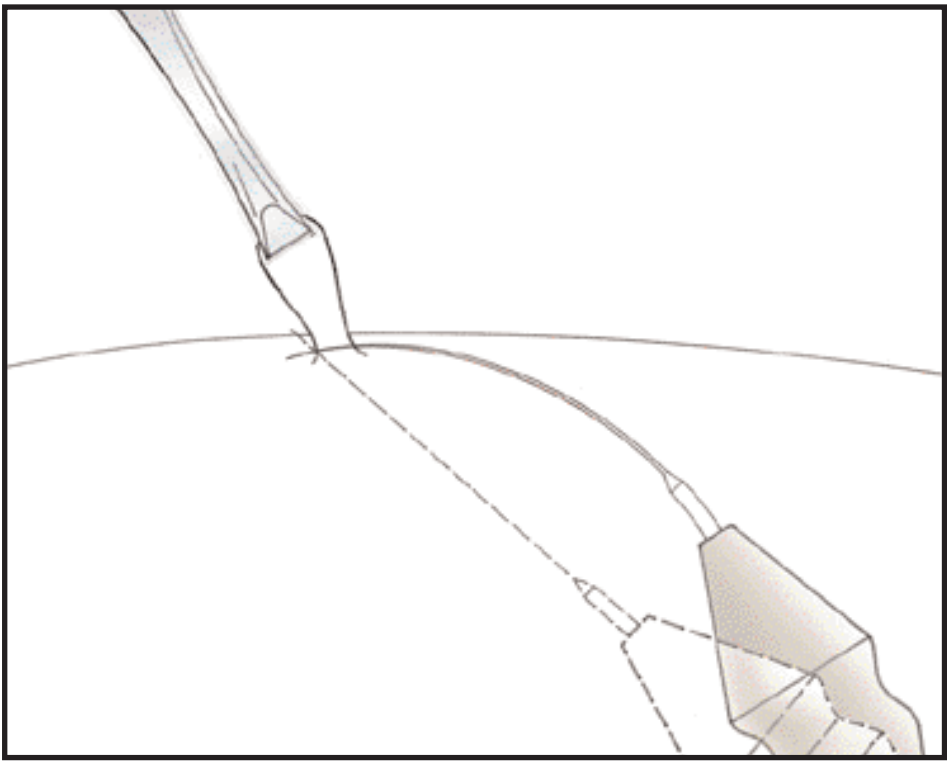


Fig. 46.0.2 The point of the electromanipule is positioned in elastic tension against the base of the peduncle (top). The timed emission allows the point to streighten, thus excising the soft fibroma (bottom).

46.1 Technique

After positioning the neutral electrode and disinfecting the area, the operator sets the Timed apparatus to the timed mode, emission time to between **5 and 15 hundredths of a second**, function to **cut**, power to **38 or 50 Watts** and inserts an **EM 10 Green or Grey** electromaniple.

While exerting traction on the lesion with forceps, the point of the electromaniple is placed under elastic tension against the base of the peduncle and an emission is generated. High power and adequate emission time enable the lesion to be removed with a single emission (**Fig. 46.1.1-3**).

The small superficial wound is left to heal spontaneously. If there are multiple lesions, any bleeding, although unimportant, is a nuisance.

If the cut peduncle bleeds, it is necessary to increase the power and electromaniple diameter.

If a greater haemostatic effect is required, the apparatus can be set to the blend function or to coagulation with microelectrodes (at a power higher than **14 Watts** and with a fine electromaniple, the coagulation function has the same effect as the blend function).

When the point of the electromaniple is able to cover the stalk of the lesion, or at least half of it, an anaesthetic is not required.

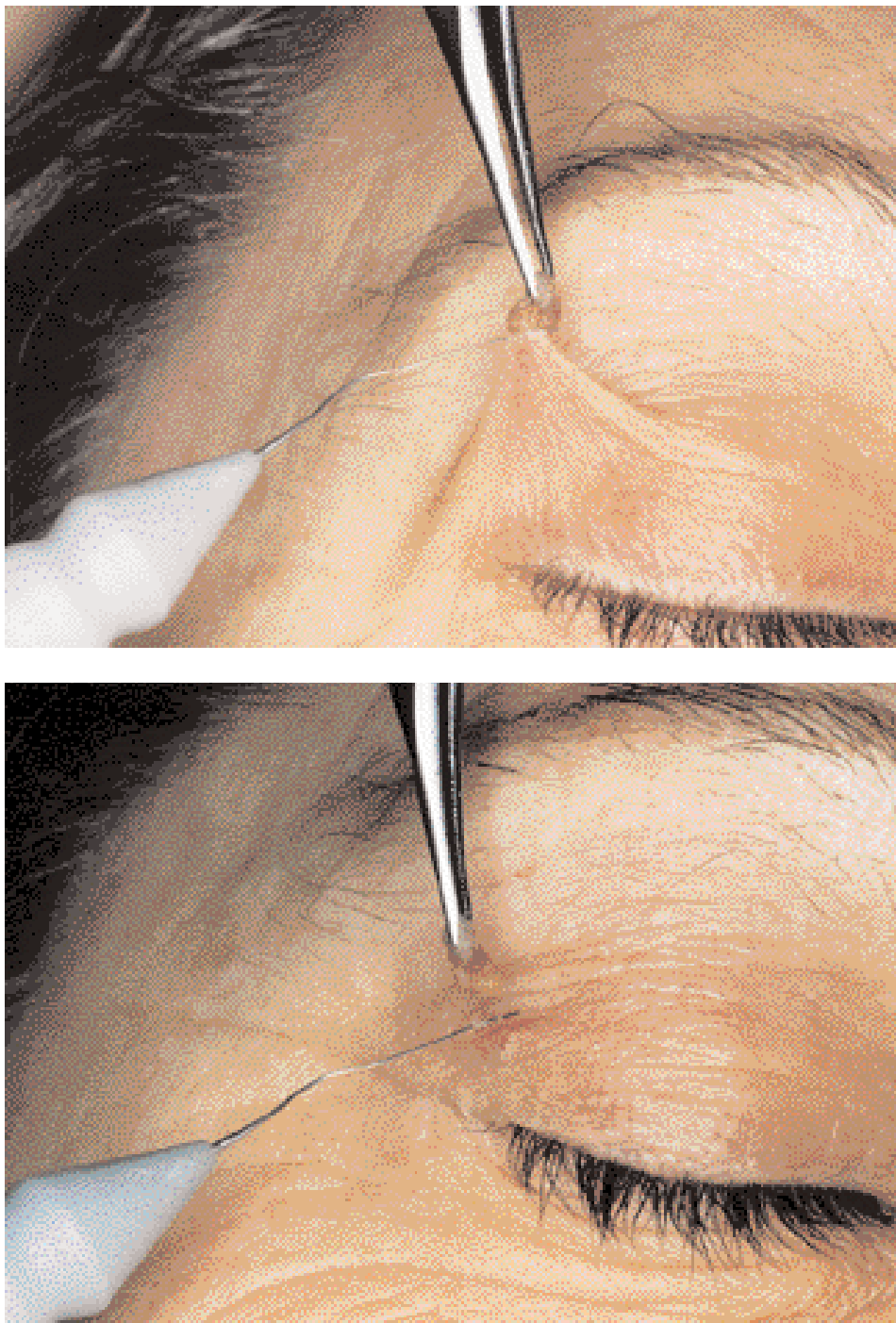


Fig. 46.1.1 Peduncolated lesion. Programme data: cut, 38 Watts, 10 hundredths of a second, EM 10 Grey electromaniple.

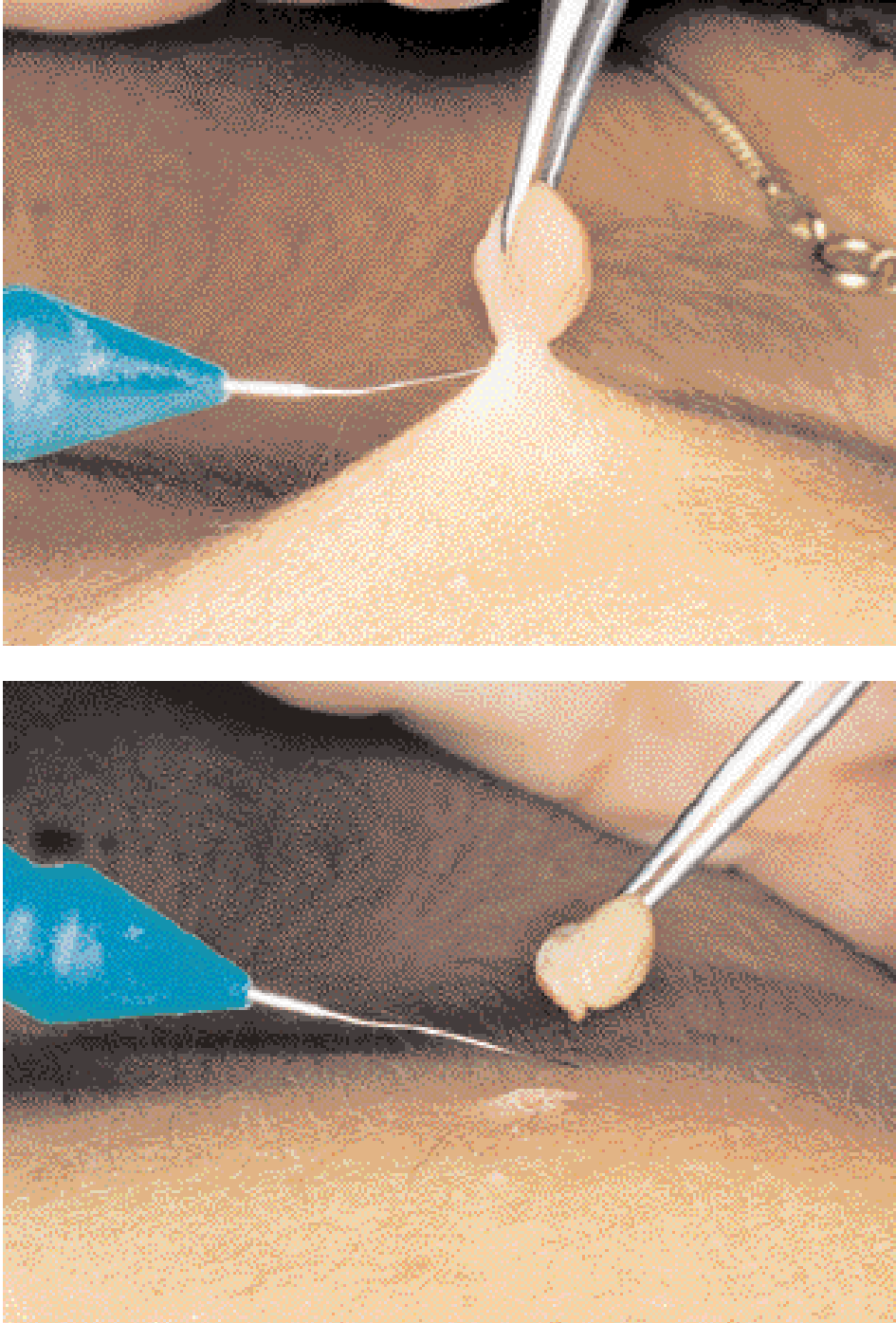


Fig. 46.1.2 Soft fibromas. Programme data: cut, 38 Watts, 15 hundredths of a second, EM 10 Green electromaniple.

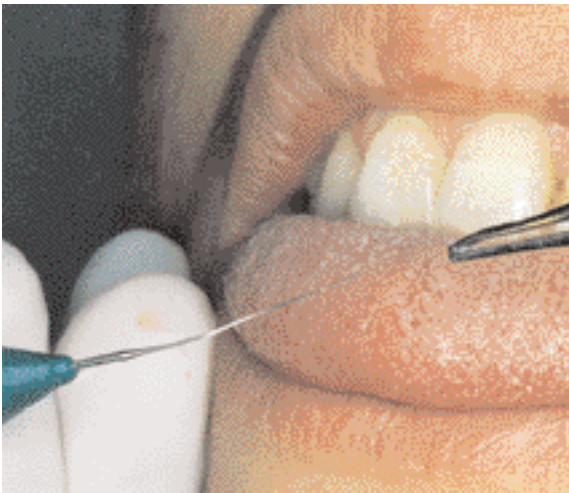
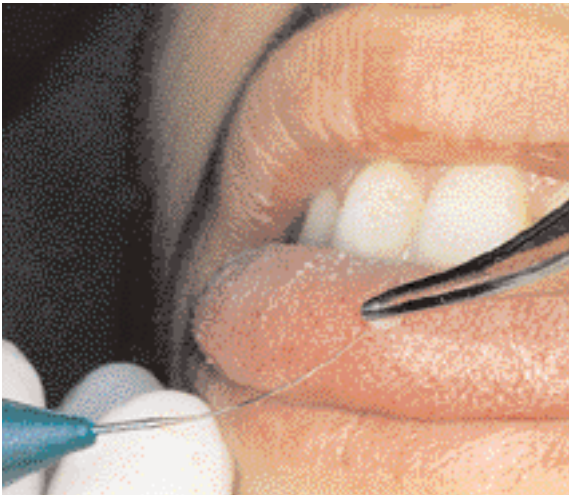
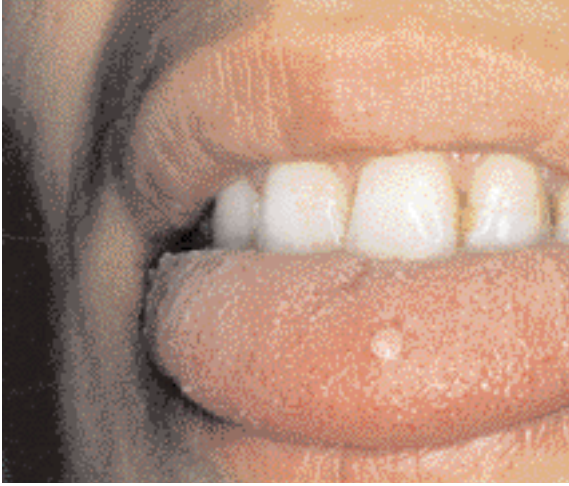

Fig. 46.1.3 Programme data: cut, 38 Watts, 10 hundredths of a second, EM 10 Green electromaniple.

Small benign skin lesions that are non-pedunculated, but which can be lifted from the level of the skin with forceps to produce a peduncular form, may be excised by means of tangential timed cut carried out at the level of the derma.

The operator sets the Timed apparatus to the timed mode and emission time to **15 hundredths of a second**.

The lesion is gripped and pulled with angled forceps (**Fig. 46.1.4**).

The point of the electromaniple is placed under elastic tension against the skin at the base of the lesion. The high-energy timed emission causes explosion and disintegration of the cells in contact with the electromaniple, which rapidly straightens and cuts off the lesion (**Fig. 46.1.5**). With the optimum programme only one or two emissions are needed; anaesthesia is not required, as pressure is not applied to nerve terminals and the brief sensation of heat is well tolerated by the patient. If a larger-diameter vessel bleeds, it should be coagulated with the **EM 15** electromaniple at **20 Watts**.

Lesions with a wide base and situated deep in the derma cannot be treated by this technique, as part of the formation may be left in place.

If the lesion is of considerable size and has a large base, it is necessary to administer a local anaesthetic and use electroshaving (see section 43.2) or to perform excision through the whole thickness. In the latter case, the operation is carried out in the pulsed cutting function with the finest electromaniple (**EM 10 White**) and is followed by suturing.



Fig. 46.1.4 Angled forceps for skin lesions (Graefe).

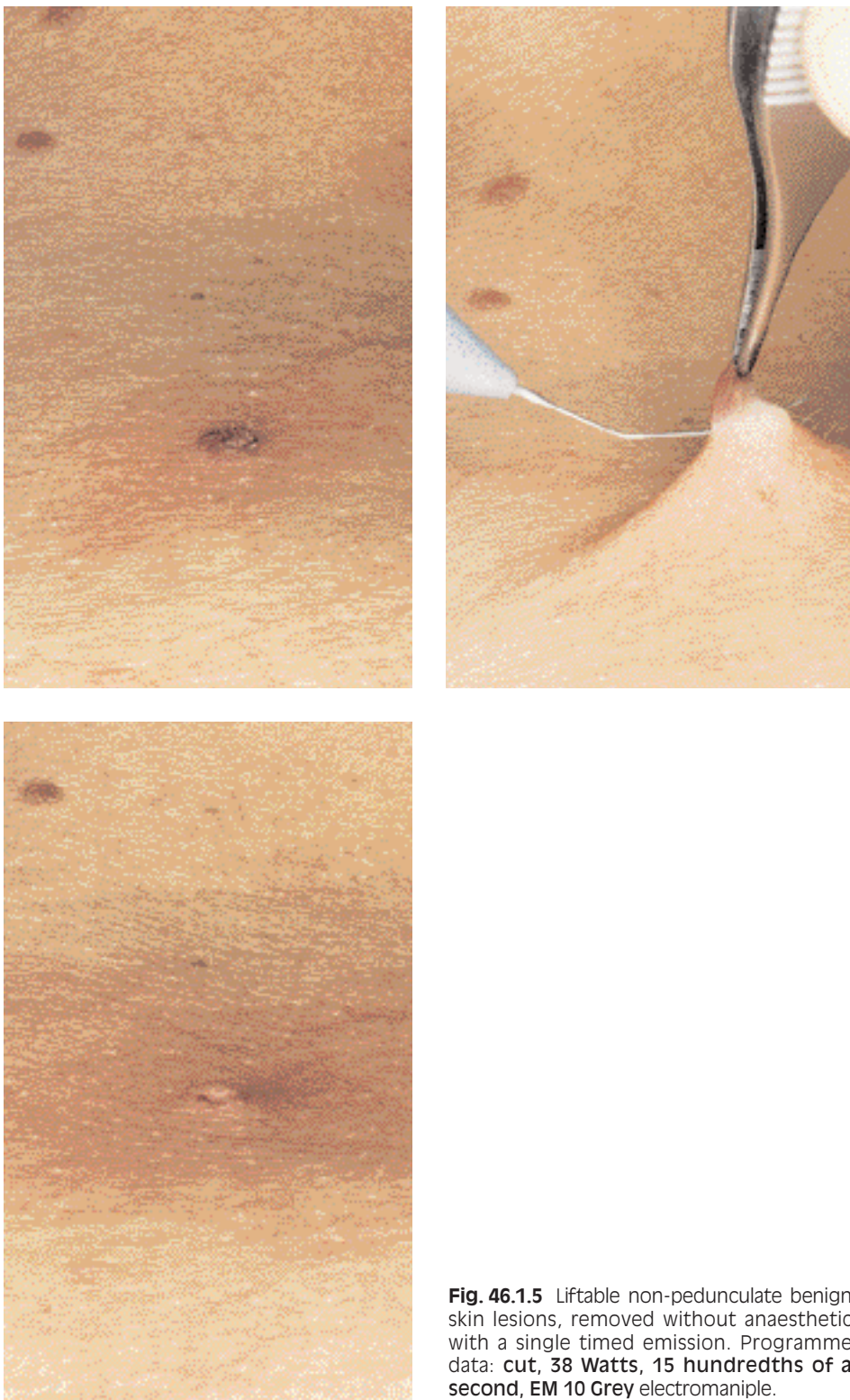


Fig. 46.1.5 Liftable non-pedunculate benign skin lesions, removed without anaesthetic with a single timed emission. Programme data: cut, 38 Watts, 15 hundredths of a second, EM 10 Grey electromanipule.

47

REMOVAL OF WHITEHEADS

Programme data

**Timed 2 hundredths of a second-
Cut - 20 Watts - EM 10 White.**

A whitehead or closed comedo is an accumulation of corneocytes in the infundibulum.

Clinically, spherical skin-coloured or whitish structures are seen, with a central opening sometimes visible as a fine point.

Timed cutting enables the cutaneous incision necessary to evacuate a closed comedo to be carried

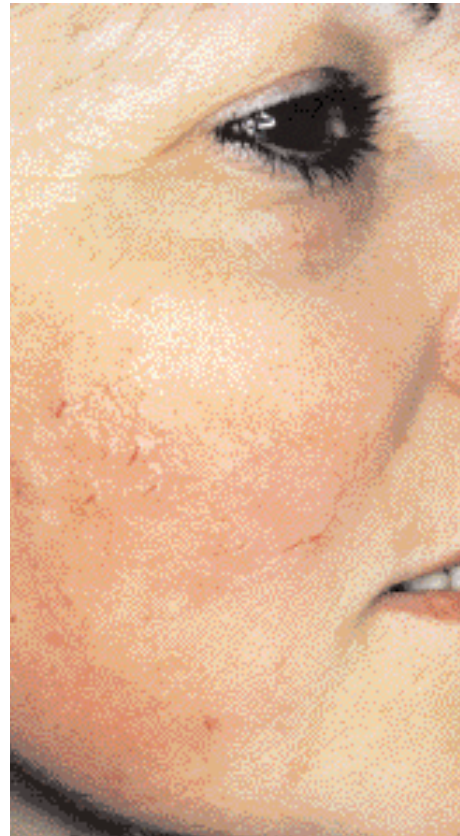
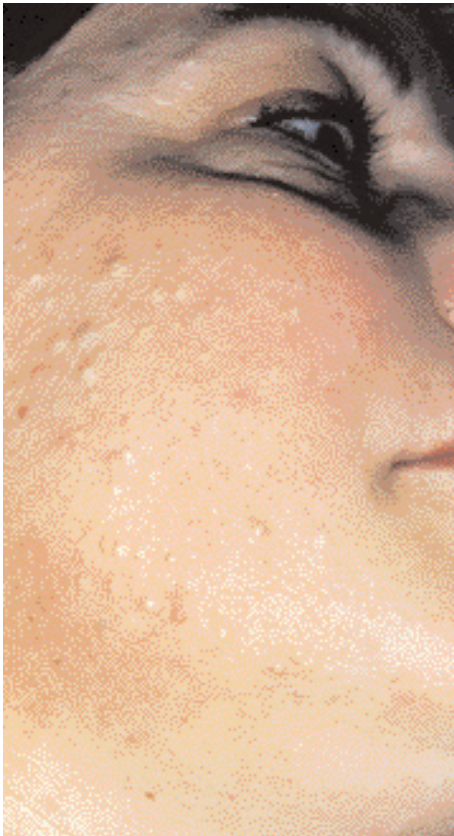
Fig. 47.0.1 Whiteheads on the face. Programme data: cut, 20 Watts, 2 hundredths of a second, EM 10 White electromaniple.

out without anaesthesia (**Fig. 47.0.1**). The treatment has the advantage of being rapid, almost bloodless, allowing good drainage the cyst and being practicable even in the presence of skin infections.

47.1 Technique

After positioning the neutral electrode and disinfecting the skin, the operator sets the Timed apparatus

to the timed mode, emission time to **2 hundredths of a second**, function to **cut**, power to **20 Watts** and uses an **EM 10 White** electro-manipule.

After positioning the point of the electromaniple on the skin above the cyst (**Fig. 47.1.1**) a timed cut is executed (**Fig. 47.1.2**). The contents of the cyst are then squeezed out with a hook or with the angled part of the same electromaniple, non-activated (**Fig. 47.1.3**).

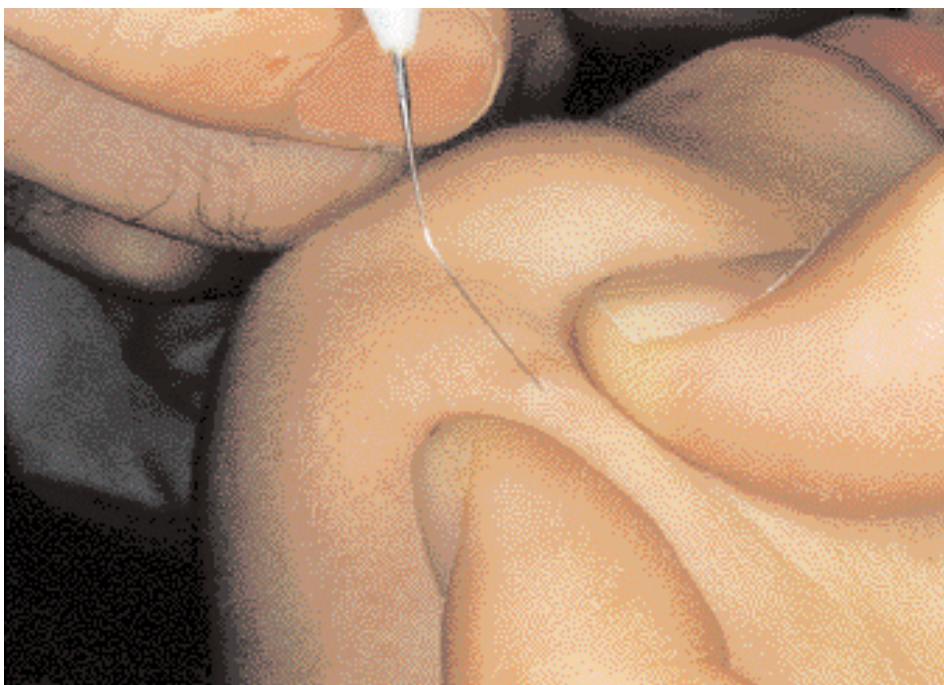


Fig. 47.1.1 The point of the electromaniple is put under elastic tension.

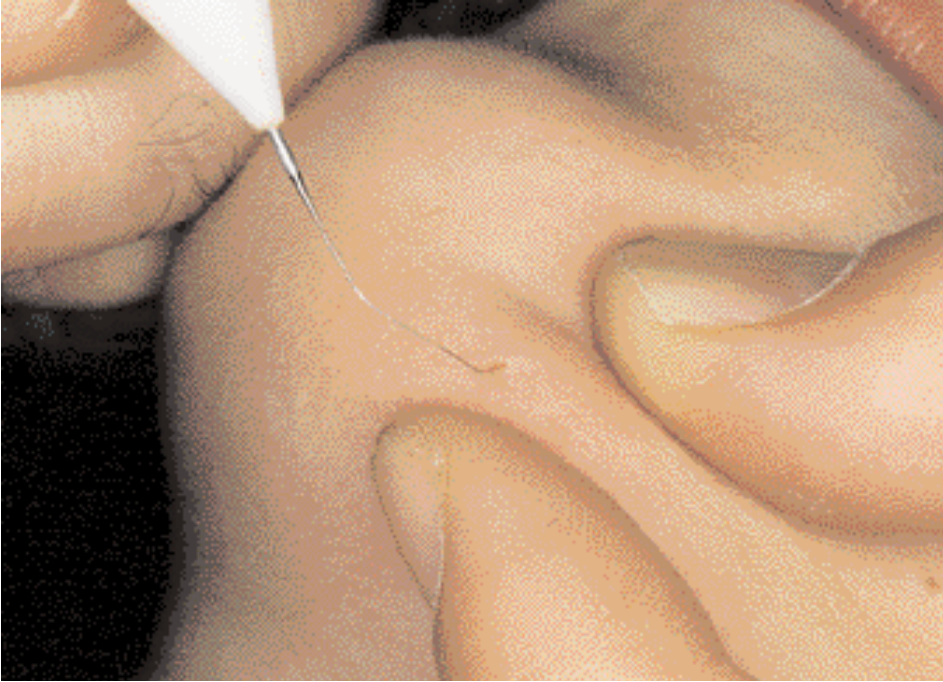


Fig. 47.1.2 The timed emission produces a micro-cut.

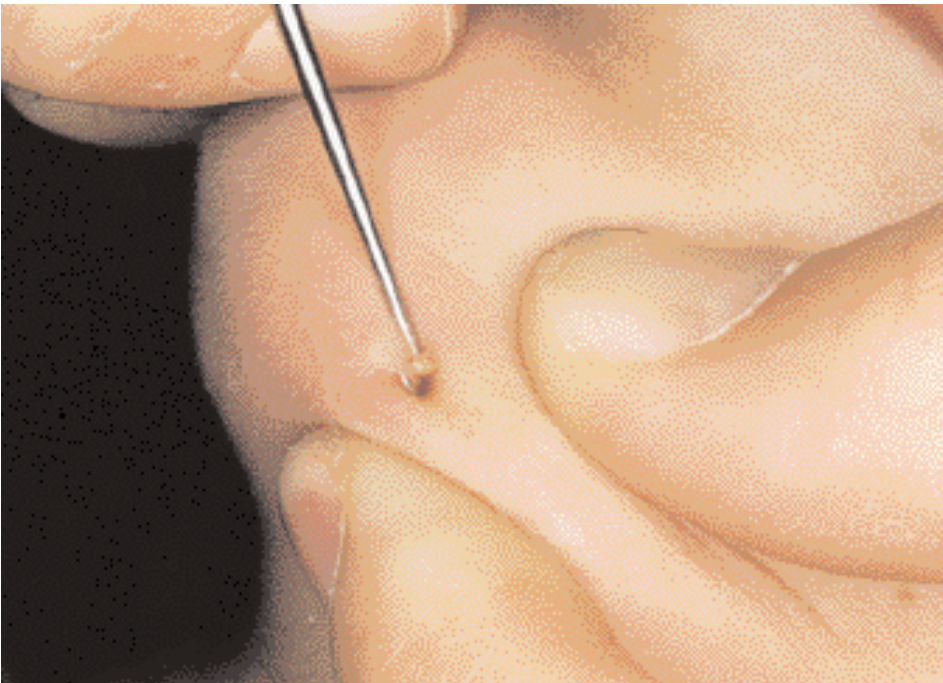


Fig. 47.1.3 After incision, the contents of the whitehead are expelled with the curved portion of a hook.

The direction of the cut is parallel to facial expression lines in the skin (**Fig. 47.1.4**). The operator leaves the micro-cuts exposed to the air, and the patient is recommended to wash the face thoroughly at home and to expel any further material from the cysts with finger pressure.



Fig. 47.1.4 The direction of the cut is parallel to facial wrinkles.

48

REMOVAL OF MILIA

Programme data

**Timed 1 hundredth of a second-
Cut - 27 Watts - EM 10 White.**

Milia are tiny sub-epidermal cysts, about the size of a pin-head. They occur frequently on the face, especially in the region of the eye-lids.

48.1 Technique

After positioning the patient return

electrode and disinfecting the skin, the operator sets the Timed apparatus to the timed mode, emission time to **1 hundredth of a second**, function to **cut** and power to **27 Watt**.

An **EM 10 White** electromaniple is used. The treatment consists of cutting the epidermal dome of the milia by means of timed emission (**Fig. 48.1.1**), and squeezing gently with the angled part of the non-activated electromaniple, to remove the contents (**Fig. 48.1.2**).

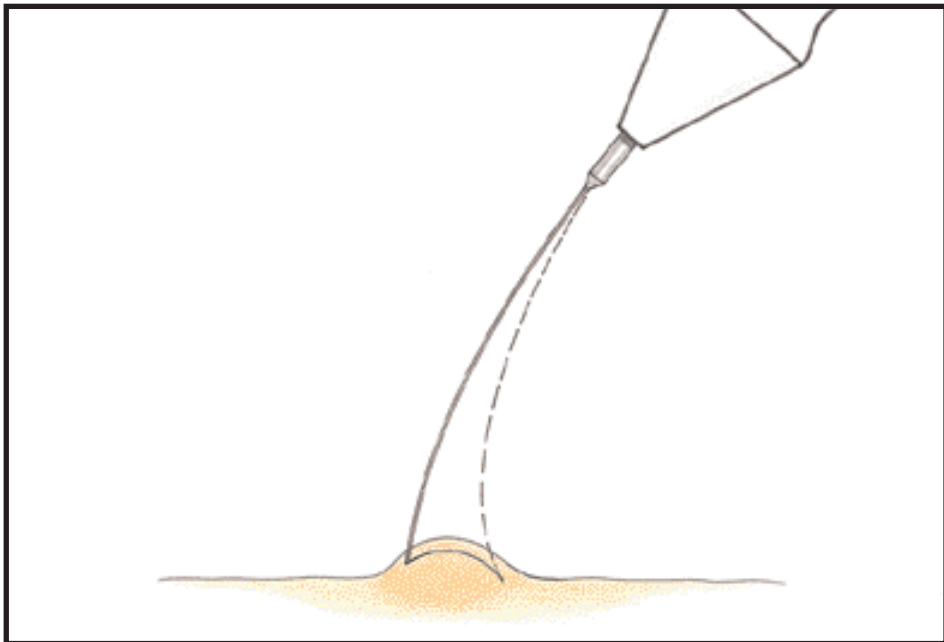


Fig. 48.1.1 Timed surgical cutting is performed.

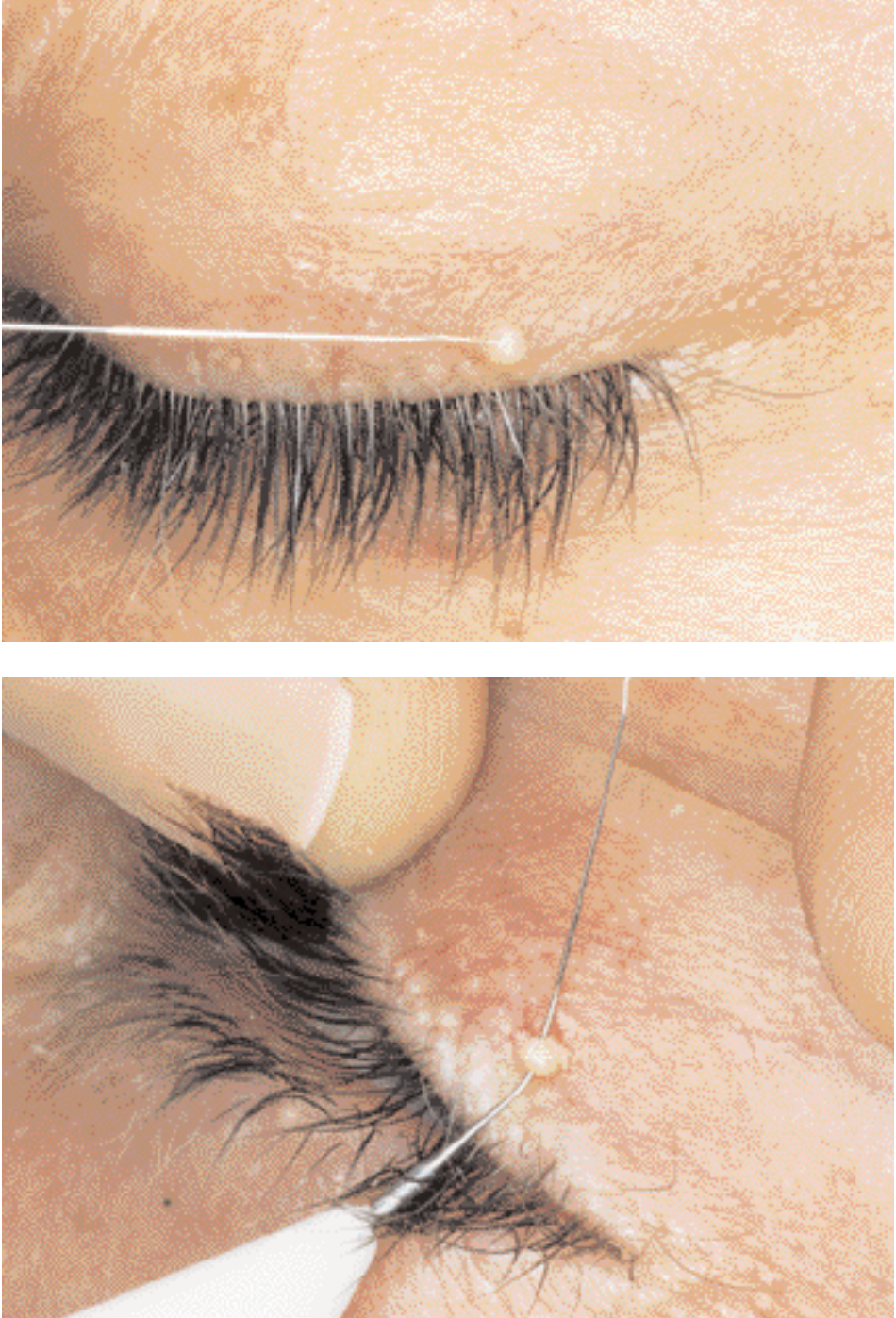

Fig. 48.1.2 Programme data: cut, 27 Watts, 1 hundredth of a second, EM 10 White electro-maniple. Executing a micro-cut in the epidermic dome of the milia, the operator uses the angled part of the non-activated electromaniple to evacuate the contents.

49

ATRAUMATIC EXCISION OF MELANOMA

Programme data

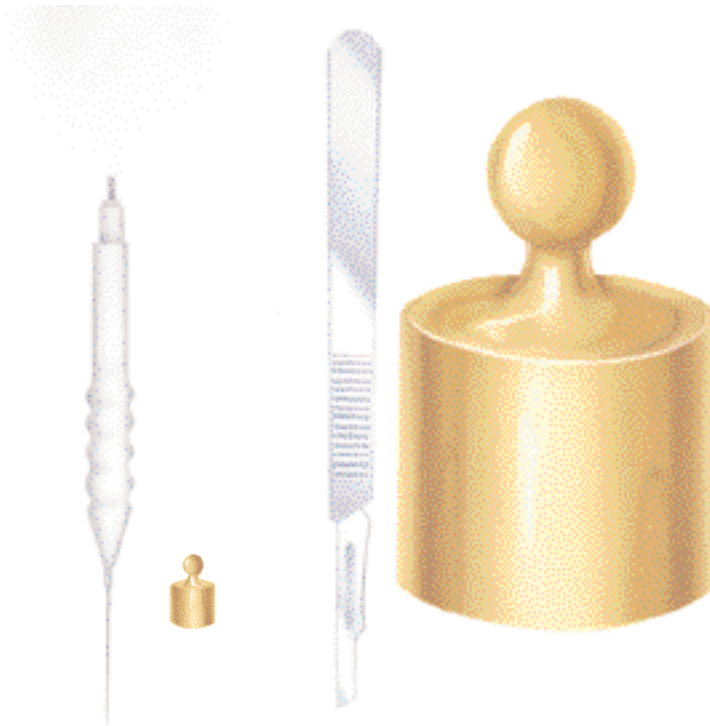
Timed 3 hundredths of a second
- Cut - 50 Watts - EM 10 Grey.

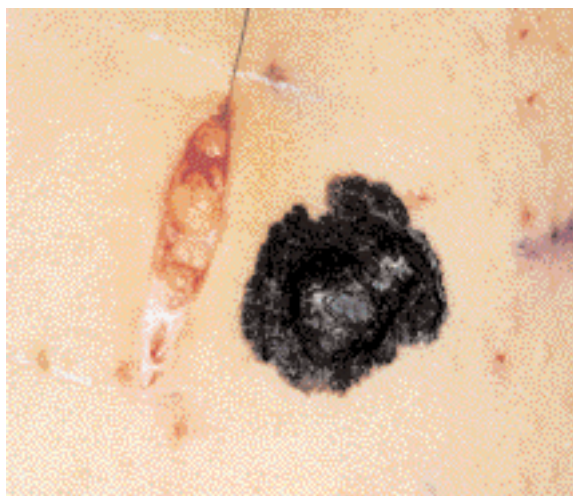
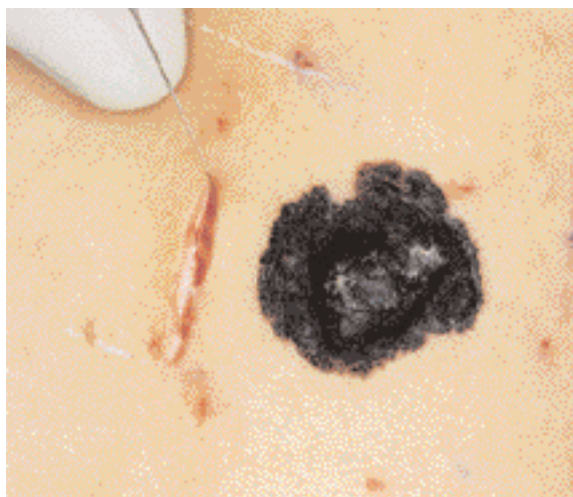
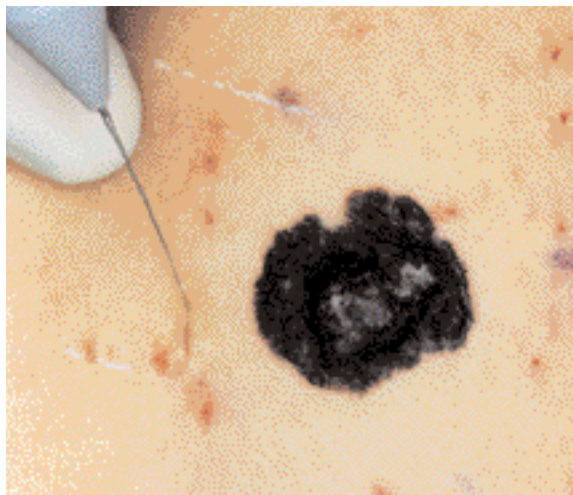
Timed cutting is the technique of choice for the excision of a malignant melanoma, as it enables the lesion to be removed without trauma. The need for atraumatic excision of melanomas stems from the frequent finding of postoperative metastases 12 months after excision with a surgical scalpel. It may be hypothesised that such metastases are due to the high

pressure exerted by the scalpel (about 2 kg with a No. 15 blade) during incision of the tissue surrounding the lesion, and to the traumatic squeezing of the tumour during the operation. The risk of metastatic spread naturally increases with the depth of the melanoma.

Timed cutting seals the lymphatic and venous capillaries and exerts negligible pressure (≤ 5 g) on the tissue. The sutured edges of the cut heal well.

From 1988 to 1993, melanomas





ranging from 1.5 to 4.2 mm in thickness were excised from 10 patients in our centre. To date (2000) none has shown any clinical or instrumental sign of metastases. These preliminary results lend support to the validity of atraumatic excision according to a concept which I like to quote: "the melanoma must not notice that it is being removed".

Timed cutting is also used for the excision of suspect pigmented neoformations.

49.1 Technique

Once the patient return electrode has been positioned, the Timed apparatus is set to the timed mode, the duration to **3 or 4 hundredths of a second**, the function to cutting (**cut**) and the power to **50 Watts**. The operating field is then disinfected and an **EM 10 Grey** electromaniple is fitted. The anaesthetic (mepivacaine with epinephrine) must be injected slowly with a fine needle all around the lesion, at a distance of 3 cm from the tumour (barrier anaesthesia).

Excision must be carried out delicately, without compressing the area with the hands, at a minimum distance of 1/2 cm from the lesion (**Fig. 49.1.1**). The blood should be mopped up with swabs, in the same way as oculists remove blood from the anterior surface of the eye. Once the skin has been incised, excision of the subcutaneous tissue is carried out by means of non-timed (direct) cutting, and the power is reduced to **27 Watts**. On completion of excision, the wound is sutured (**Fig. 49.1.2**).

Before the operation, or within 10 days afterwards, the patient must undergo all the necessary tests to

detect the presence of metastases. Examinations and treatment will follow the usual protocols.

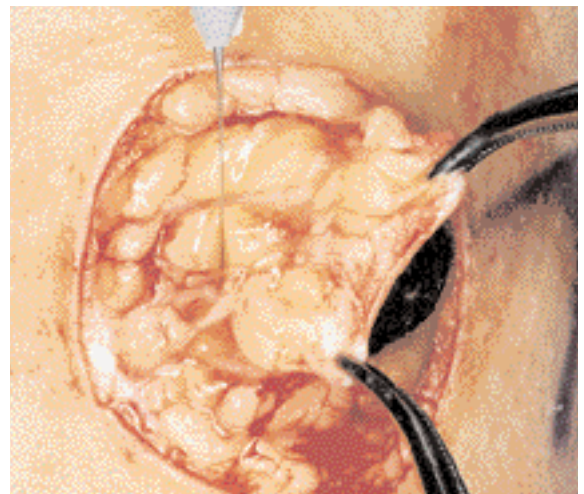
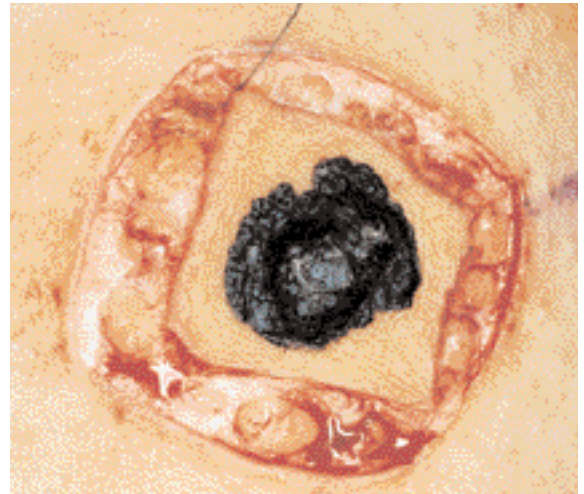
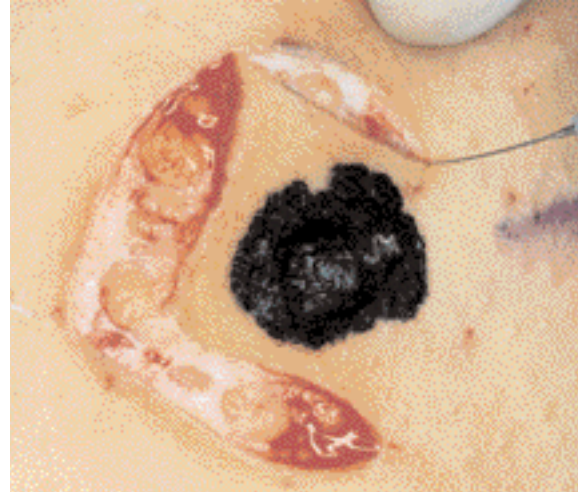


Fig. 49.1.1 Atraumatic excision of a malignant melanoma. Clark IV, Breslow 3 mm. The skin incision was carried out by means of timed cutting. Programme data: **cut, 50 Watts, 4 hundredths of a second, EM 10 Grey** electromaniple. Local anaesthesia. The subcutaneous tissue was incised down to the muscle band by means of non-timed (direct) cutting performed at **27 Watts**.

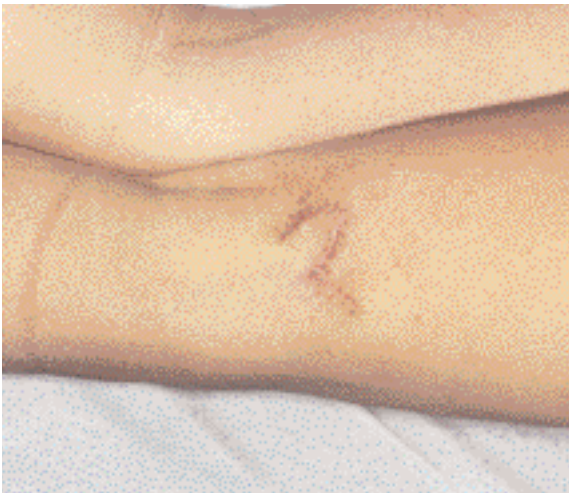
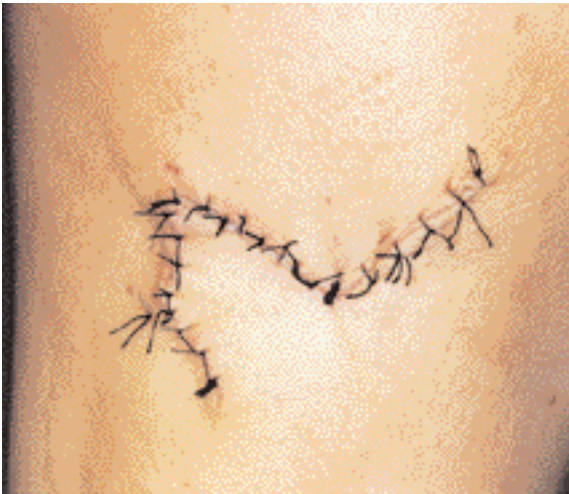
Fig. 49.1.2 The patient has not presented any clinical or instrumental signs of metastases in the eight years since excision.

50

TREATMENT OF PRECANCEROUS LESIONS

Programme data

Micro-arc

**Direct - Coag microelectrodes -
50 Watts - EM 15**

High-frequency current is rarely used today to destroy malignant lesions, as the procedure prevents normal histological examination of the specimen, making it impossible to determine whether the lesion has been completely removed. The treatment of choice for malignant skin lesions is surgical excision, with removal of a margin of healthy tissue. The operator may create the incision by means of timed or pulsed cutting.

High-frequency current may be used for superficial basal cell carcinomas, small basal cell carcinomas on the trunk (Casson 1980), some types of oral tumour, premalignant conditions and for palliative treatment of extensive lesions that are not amenable to surgery.

For such lesions a micro-arc is frequently used in timed surgery; this is produced in the **coagulation with microelectrodes** mode at a power of **50 Watts**, by keeping the tip of an **EM 15** electromanipule a few millimetres above the tissue, after making contact with the tissue for an instant.

At this power, the Timed apparatus produces a sustained arc, which is

much hotter than that produced by the original spark-gap generators.

If the tumour is ulcerated or infected, the micro-arc sterilises the field as well as destroying the growth (see section 51). It has been speculated that the heat generated may also have an anti-tumoral action.

In patients with multiple lesions, it may be difficult to accurately define appropriate margins for surgical excision, perhaps making this a less suitable form of treatment. The use of the micro-arc allows the condition to be controlled simply and rapidly without widespread tissue destruction.

The micro-arc is frequently used to eliminate solar keratoses. It also allows areas to be treated which are only suspect.

On the facial skin, the micro-arc technique yields very good results (**Fig. 50.0.1**). Particular care is needed when treating tumours situated above the cartilages of the nose or ears.

The physical treatment of malignant neoformations must be carried out by an expert who is able to select those cases in which it will be efficacious.

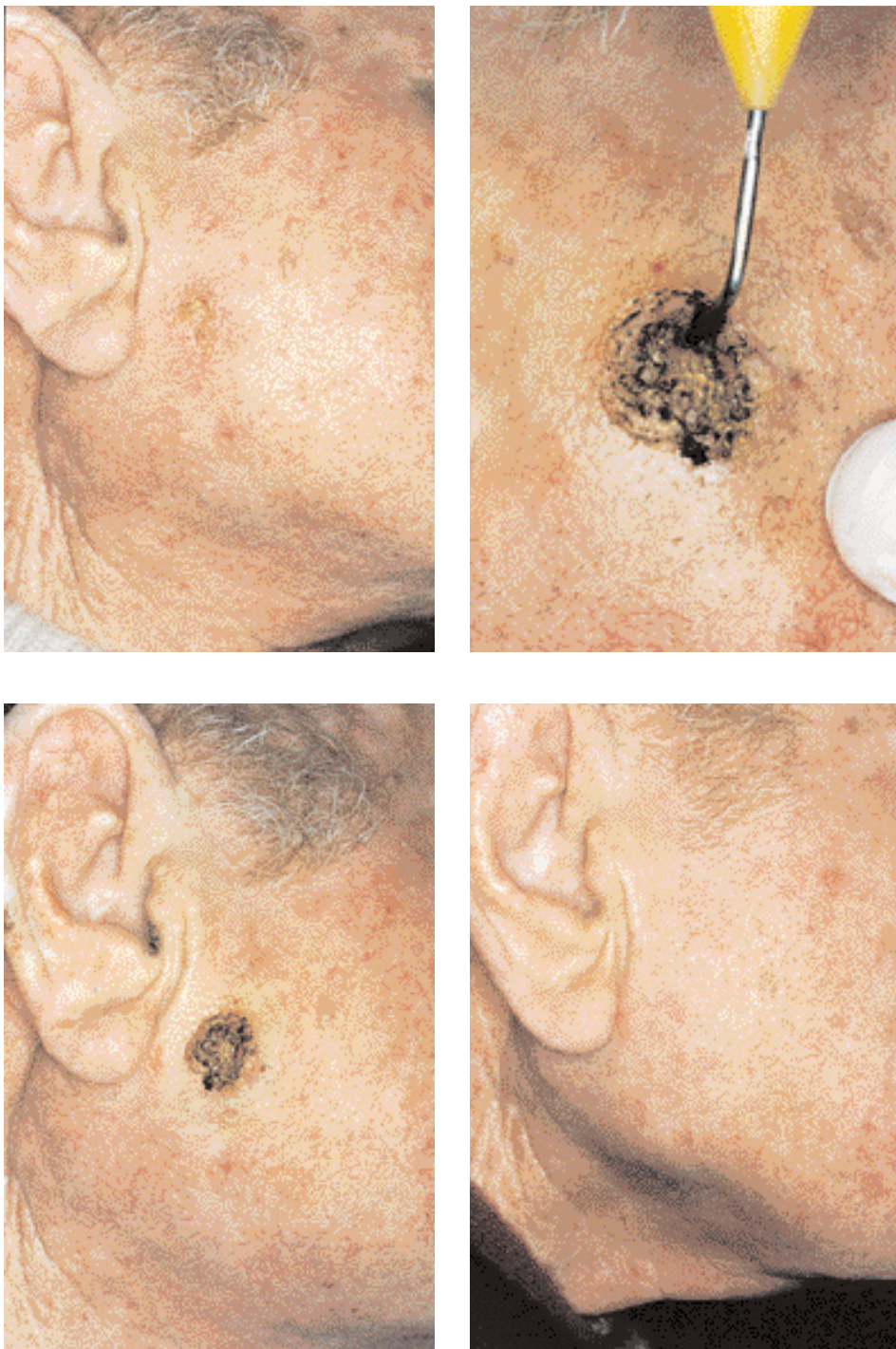


Fig. 50.0.1 Solar keratosis. Micro-arc. Programme data: **coagulation with microelectrodes, 50 Watts, EM 15** electromaniple. Local anaesthesia. The action of the micro-arc must extend 0.5 cm beyond the margins of healthy tissue. No recurrence after 8 years.

51 TIMEDSURGICAL CLEANSING OF ULCERS

Programme data

Micro-arc

Direct - Coag microelectrodes - 50 Watts - EM 15 .

Cutaneous ulcers have many causes (Tab. 51.1) and involve the dermis and often the subcutaneous tissues (**Fig. 51.0.1**).

Wound healing may be impaired by local factors (deep necrosis, infection, oedema, neuropathy, arterial insufficiency) or general conditions (illness and metabolic deficiency).

Most ulcers heal after degradation and removal of the overlying dead tissue and eschar. It is the long duration of the process which is the major

Tab. 51.1 Cause of cutaneous ulcers

Venous insufficiency
Arterial insufficiency
Neuropathy
Trauma
Chemical and physical injury
Metabolic illness
Infections
Haematological illness
Auto-immune disorders
Malnutrition
Tumours
Iatrogenic causes

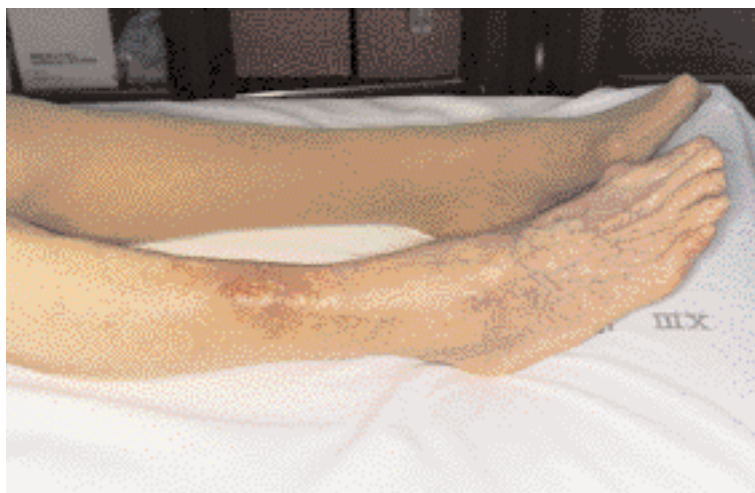
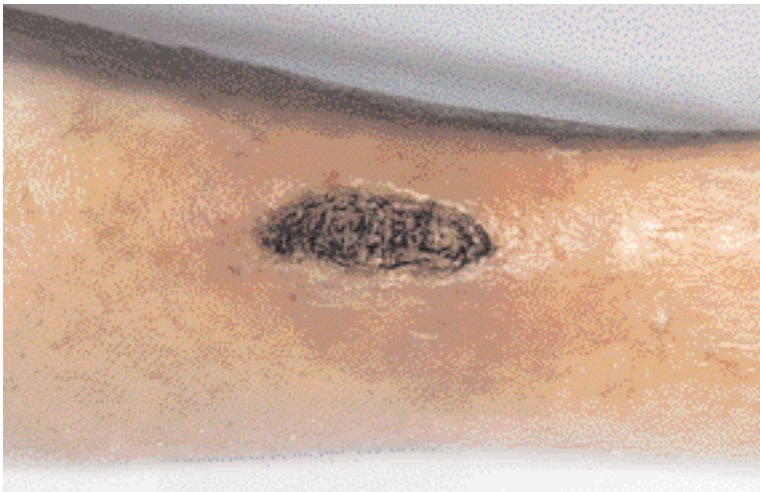

Fig. 51.0.1 Ulcer present for more than three years.

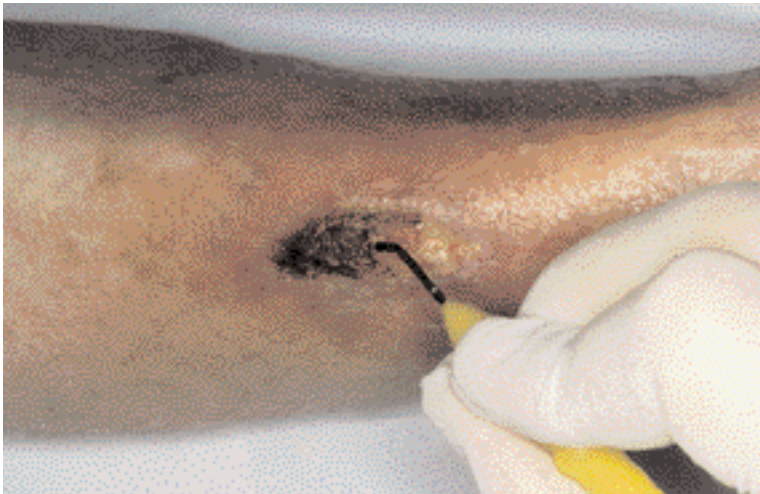
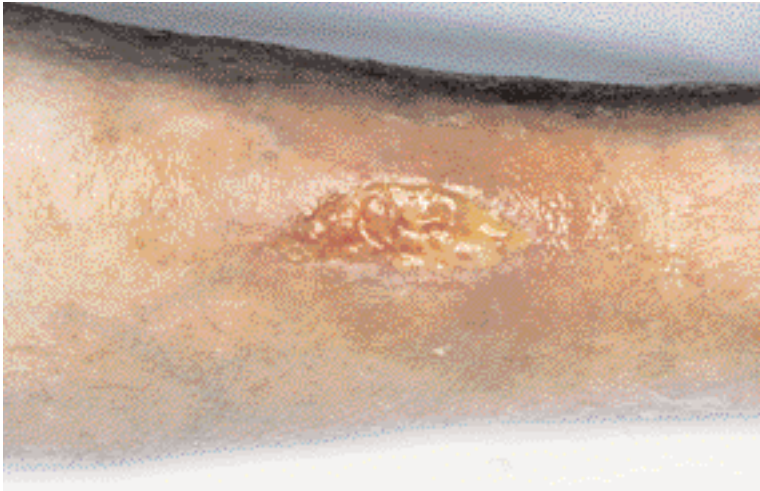
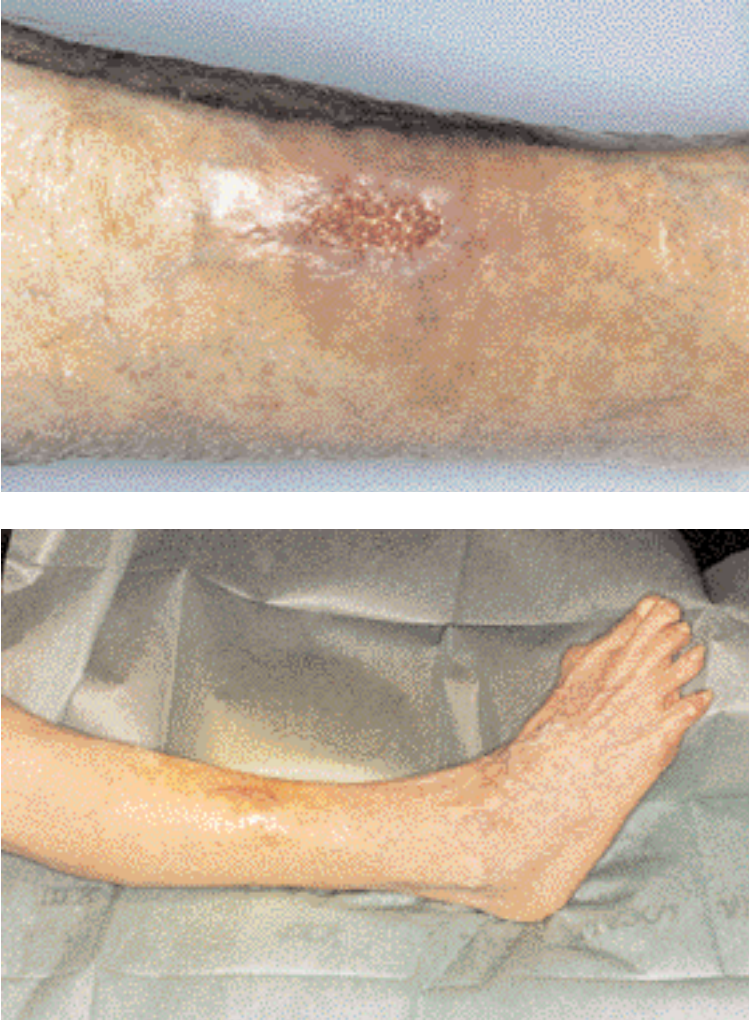



Fig. 51.0.2 Timedsurgical cleansing. The tip of the **EM 15** electromaniple passes very close to the edges and base of the ulcer, generating a high-energy micro-arc. As well as eliminating damaged tissue, the micro-arc stimulates granulation tissue. Healing is spontaneous after only one session of timed surgical cleansing. Programma data: **coagulation with microelectrodes, 50 Watts, EM 15** electromaniple.

problem, particularly in leg ulcers, due to their reduced vascularity. Timedsurgical cleansing (Capurro 1990) eliminates damaged tissue and “sterilises” the area, stimulating the

formation of granulation tissue (**Fig. 51.0.2**).

After cleansing, suitable medication is applied (Tab. 51.2).

Until the ulcer has been completely

Tab. 51.2 Local treatment of cutaneous ulcers

A) Local cleansing	1) Chlorhexidine 2) Povidone iodine 3) Potassium permanganate
B) Topical antiseptics, or antibiotics	1) Povidone iodine ointment 2) Silver sulphadiazine 3) Mupirocin 4) Saline solution with antibiotic 5) 0.5% acetic acid solution 6) Michigan solution (1/3 0.5% acetic acid, 1/3 H₂O₂, 1/3 saline)
C) Dressing	1) Absorbent 2) Non-adherent impregnated with Petrolatum Povidone-iodine Silver Bismuth Scarlet red Hydrogel Aloe vera Balsam of Peru 3) Trasparent films 4) Foams 5) Hydrogels 6) Xerogels Alginates Dextranomers 7) Hydrocolloids 8) Emerging technology
D) Compressing	1) Graduate stockings or elastic bandages
E) Debridement	1) Surgical 2) Timedsurgical cleansing 3) Streptokinase
F) Neuropathy	1) Appropriate dressings to avoid local pressure
G) Surgery	1) Attention to veins, arteries, skin grafts, flaps
H) Regional tridimensional sclerotherapy	1) 6% or 8% Bisclero

Tab. 51.3 Phases in the healing process of cutaneous ulcers.

Surgical removal or spontaneous detachment of eschar.
Elimination of the residual necrotic tissue by proteolytic and lipolytic enzymes from leucocytes.
Formation of granulation tissue at the base of the ulcer.
Re-epithelialisation from the surrounding skin or surgical repair with skin grafts or flaps.

cleansed, spontaneous healing cannot take place, nor can plastic reconstruction be carried out (Tab. 51.3).

This technique enables ulcers which may otherwise require months of more conventional treatment to be cleansed in a few weeks (**Fig. 51.0.3-9**).

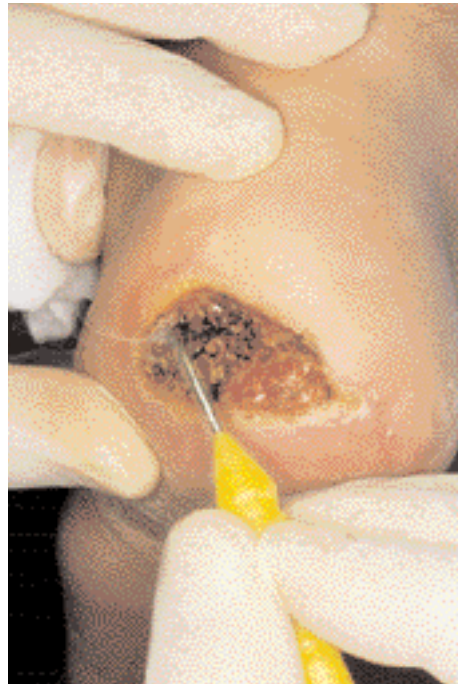
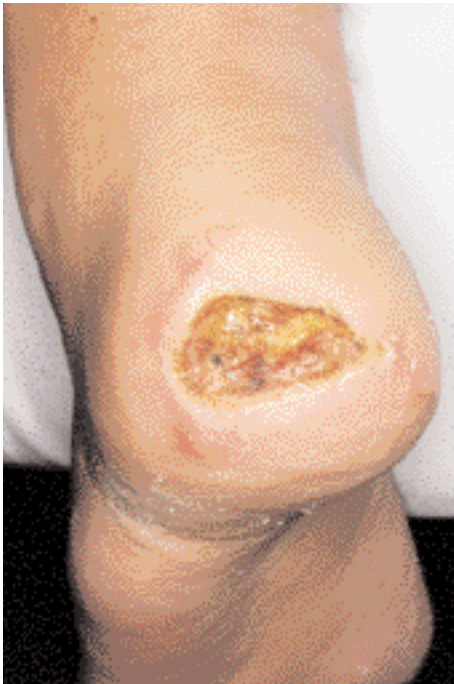
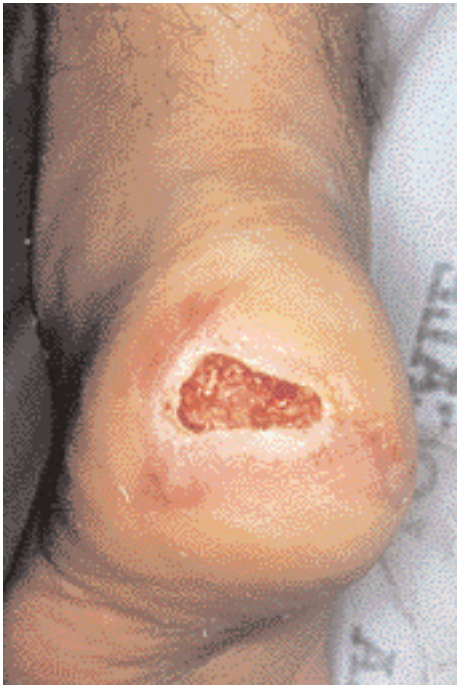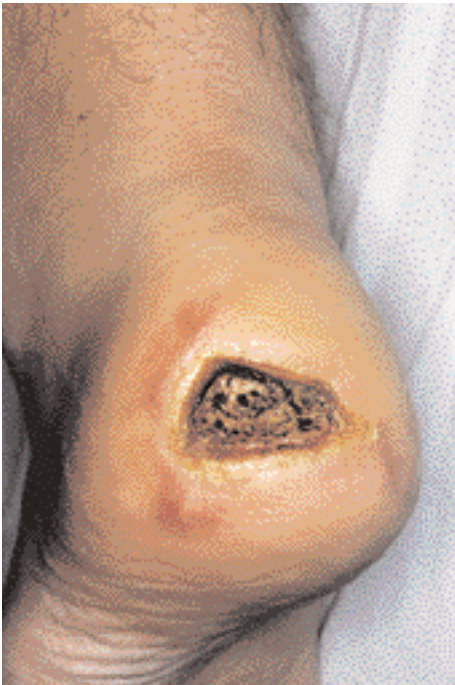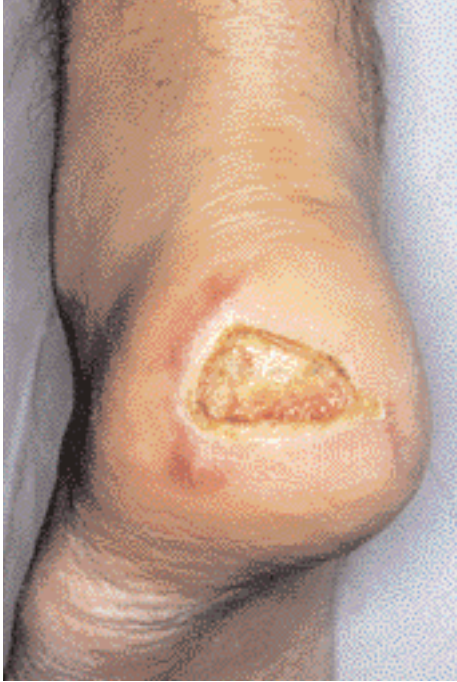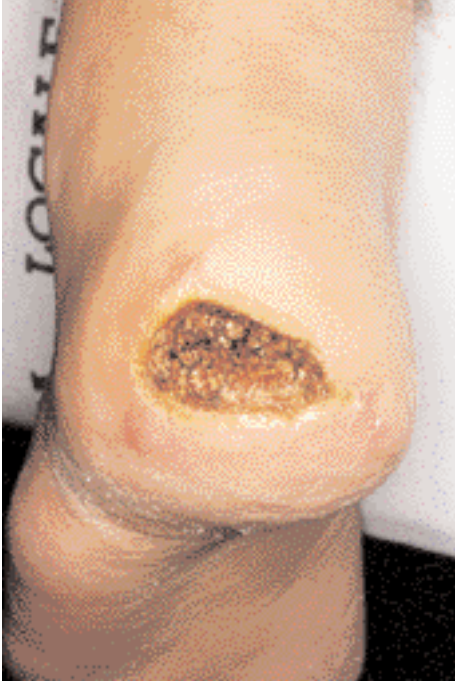Fig. 51.0.3 Neuropathic decubitus ulcer in a foot denervated as a result of injury to sensory nerves. Timsurgical cleansing.



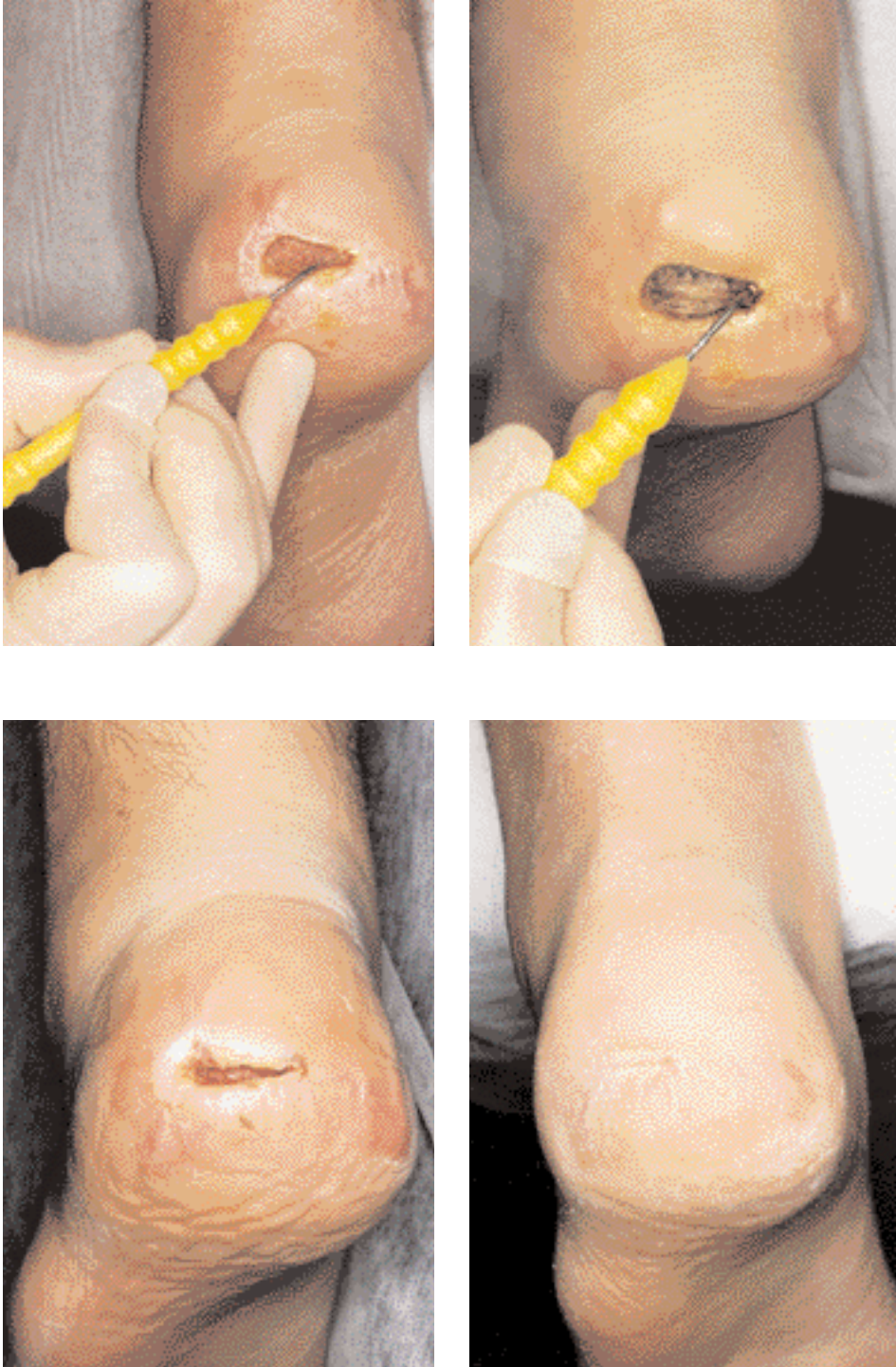


Fig. 51.0.4 Programme data: coagulation with microelectrodes, 50 Watts, EM 15 electro-manipule. Results after four cleansing sessions carried out at intervals of five days.

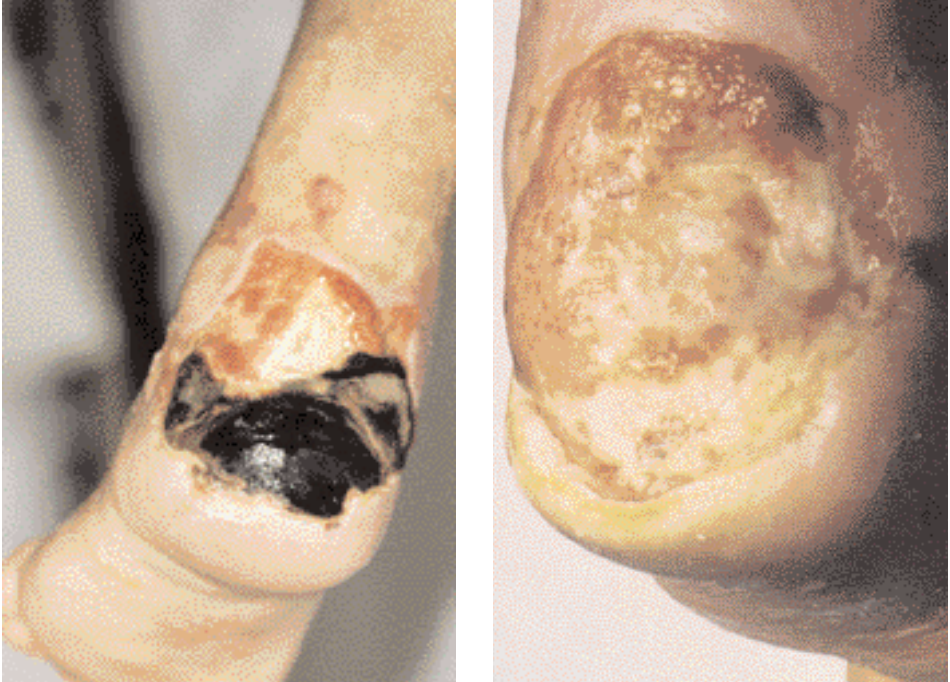

Fig. 51.0.5 Traumatic ulcer. After removal of the eschar the ulcer must be thoroughly cleansed.

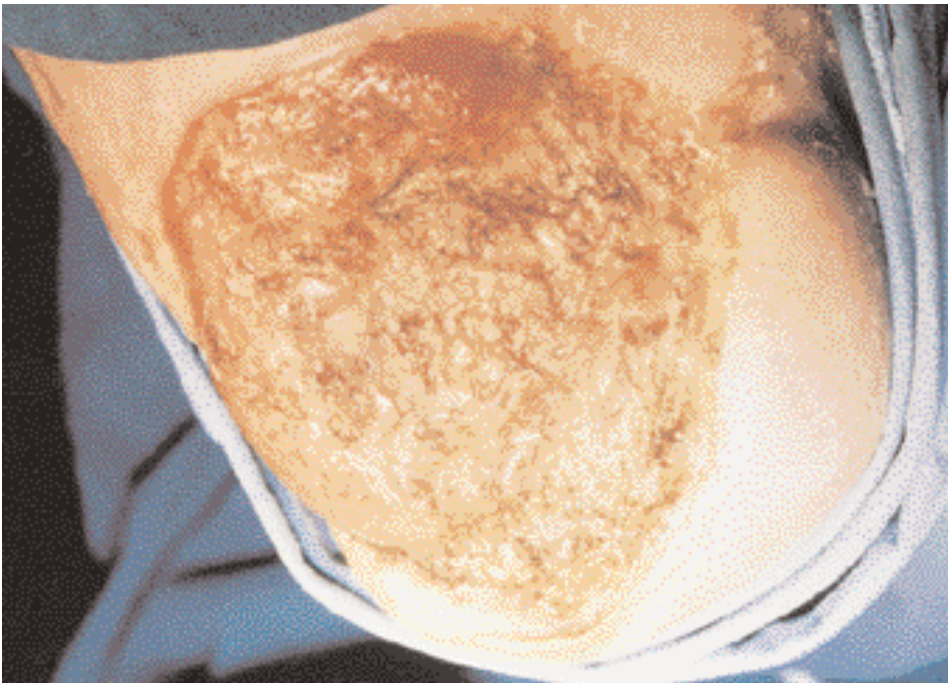


Fig. 51.0.6 Timedsurgical cleansing. Programme data: coagulation with microelectrodes, 50 Watts, EM 15 electromaniple.

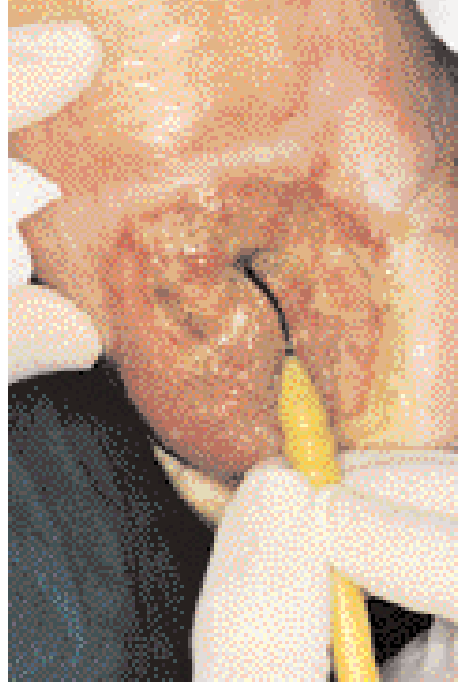
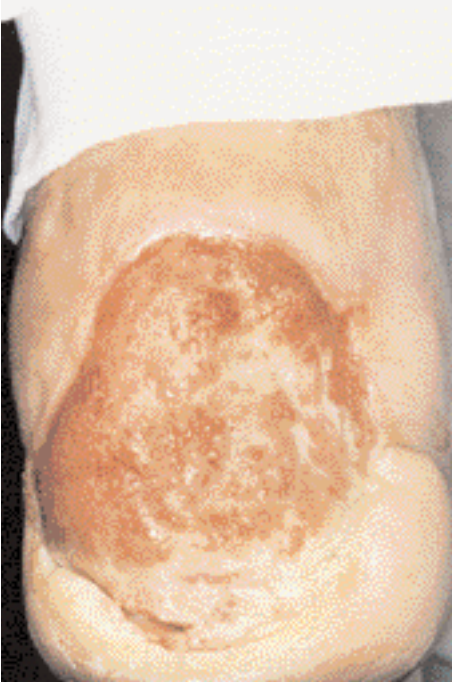

Fig. 51.0.7 Five days after the first timed surgical cleansing, the operator carries out a second treatment on the residual pathological tissue.

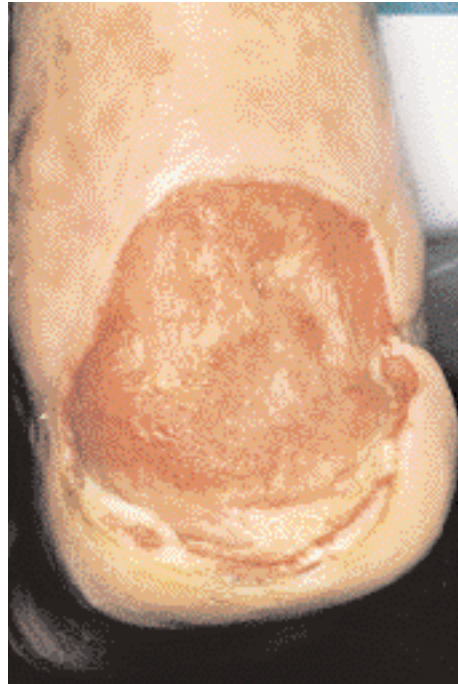
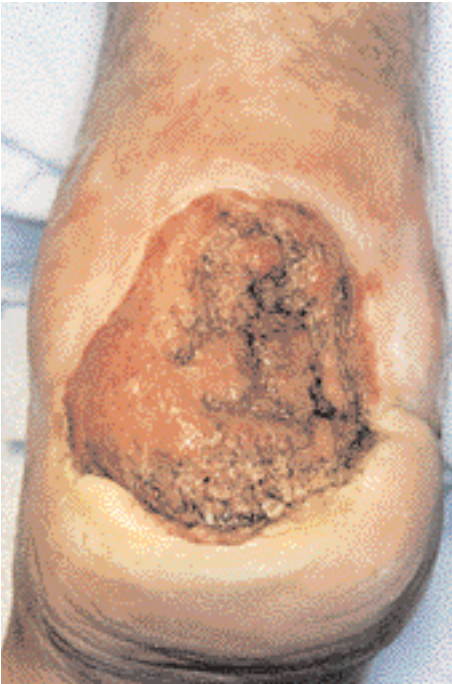
Fig. 51.0.8 Five days later the base of the ulcer is in an ideal condition for skin grafting. Microbiological tests show no growth.

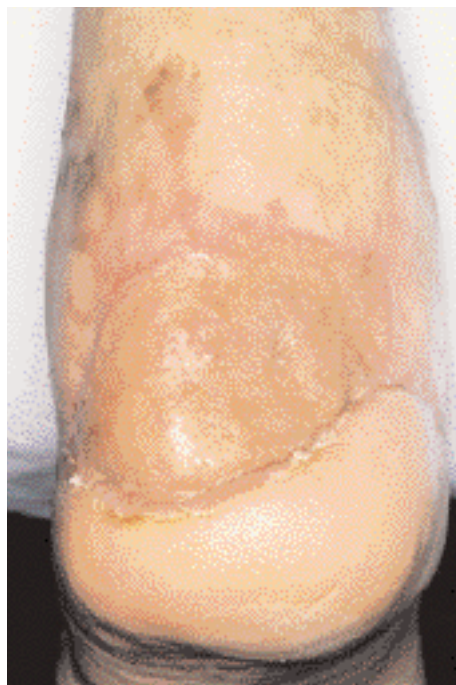
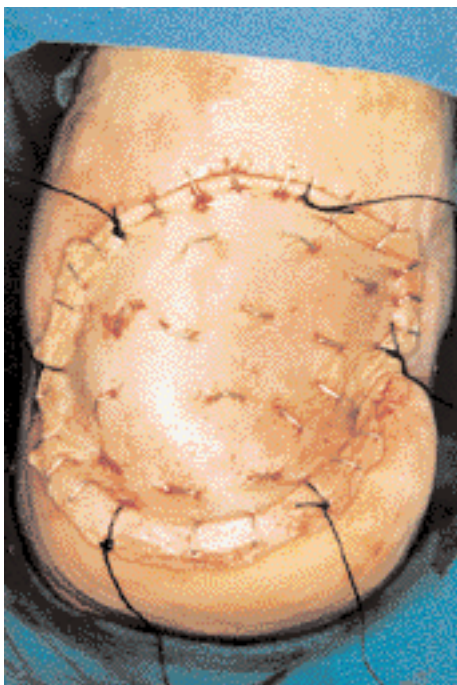
Fig. 51.0.9 A skin graft is applied to the area. The graft takes root completely.

51.1 Technique

Many ulcers (95%) can be treated without anaesthetic; if the patient does feel some pain, a local or regional anaesthetic is used.

The operator wears a mask and uses a fume extractor. The Timed apparatus is set to the **direct** mode, function to **coagulation with micro-electrodes** and power to **50 Watts**; an **EM 15** electromaniple is used. The healthy tissue at the base and edges of the ulcer is brushed with the tip of the electromaniple, generating a micro-arc.

The operator will avoid areas of granulation tissue. However, if the ulcer is infected, the whole area should be treated (**Fig. 51.1.1**).

A prolonged micro-arc is necessary

where the pathological tissue is deep. After the procedure, an antiseptic or antibiotic cream is applied. With normal vascularisation, lesions may be ready to receive a skin graft after two or three sessions of timed surgical cleansing, at intervals of five days. If vascularisation is deficient, more sittings are required, at weekly intervals.

Any type of ulcer may be cleansed timed surgically with the exception of arterial ulcers.

With venous ulcers of the legs, timed surgical cleansing is performed after the removal of a little of the fibrin layer, which is always present (**Fig. 51.1.2-3**).

After sterilisation, skin grafting and saphenectomy can be performed simultaneously.

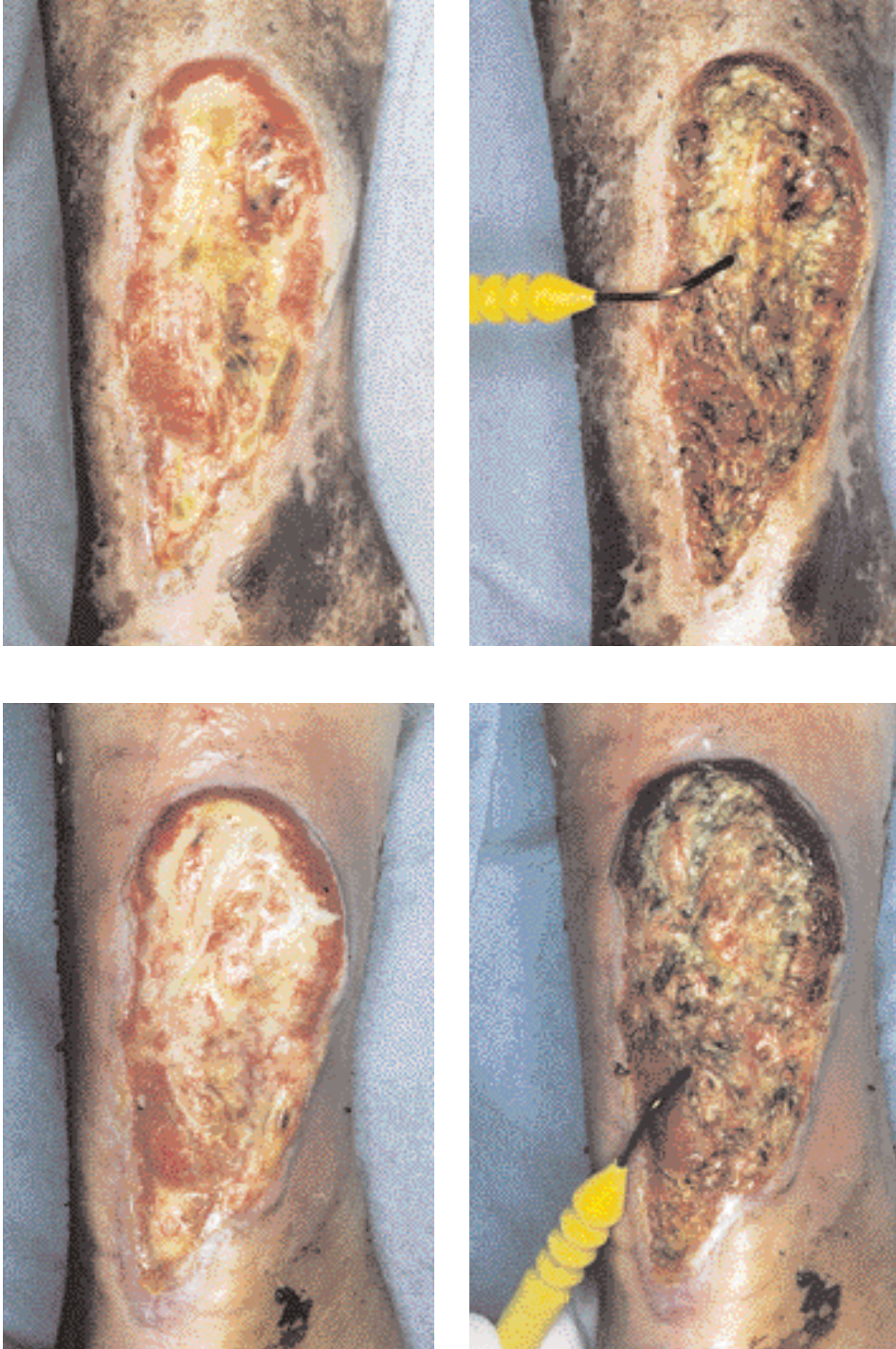
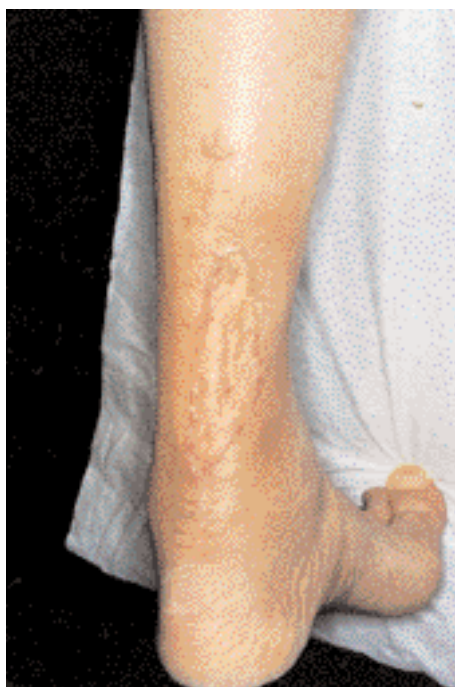
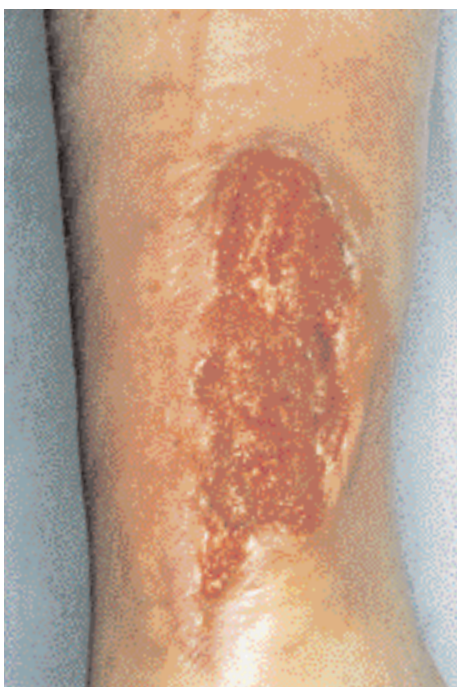
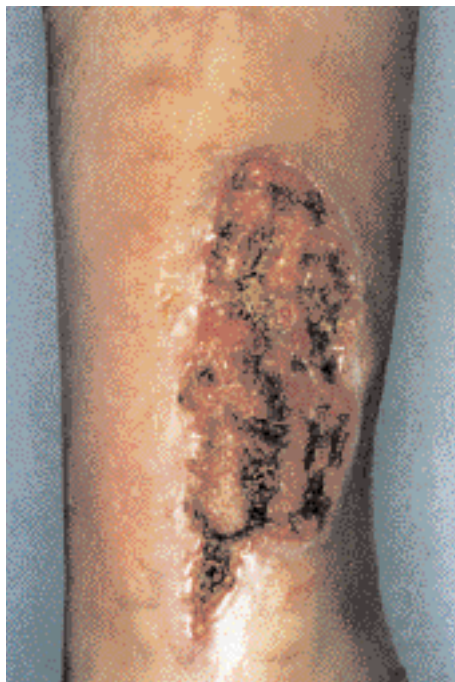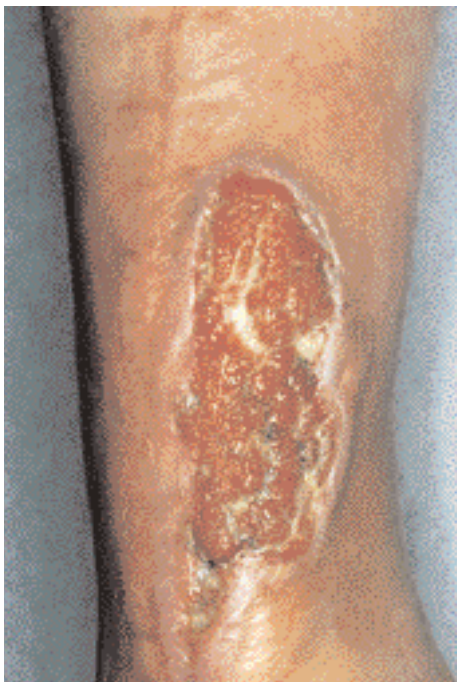Fig. 51.1.1 Ulcer following infection (top left). During the first timed surgical cleansing session (top right). After five days, marginal re-epithelialisation is already present (bottom left). During the second cleansing session (bottom right). *(see below)*



After five sessions of timed surgical cleansing (top left). After the sixth session (top right). Microbiological examination is negative, leaving the operator free to treat only the residual devitalised tissue. Four days later the base is ready to receive a skin graft (bottom left). Result (bottom right). Programme data: **coagulation with microelectrodes, 50 Watts, EM 15** electromanipule.

Skin grafting can be carried out immediately after timed surgical cleansing, if the carbonised layer is removed (S. Inzerillo).

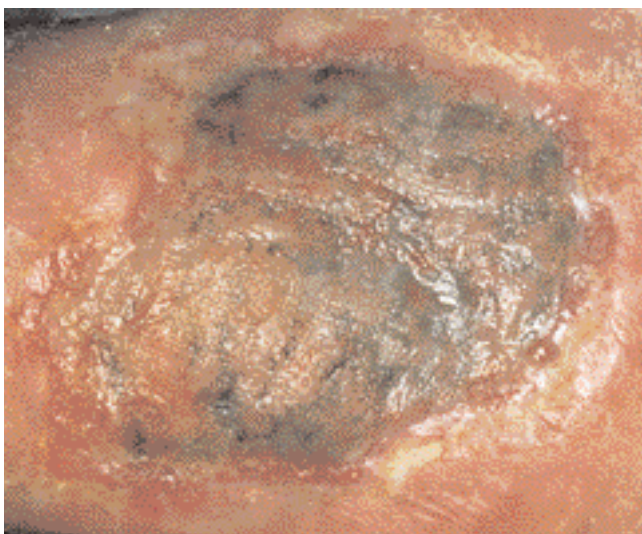
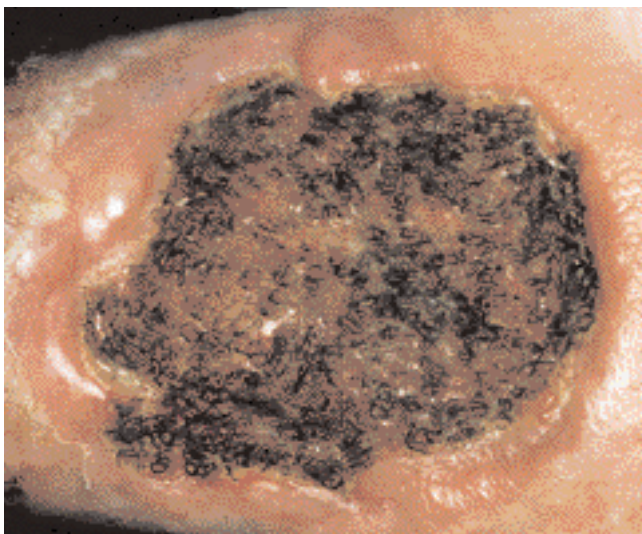
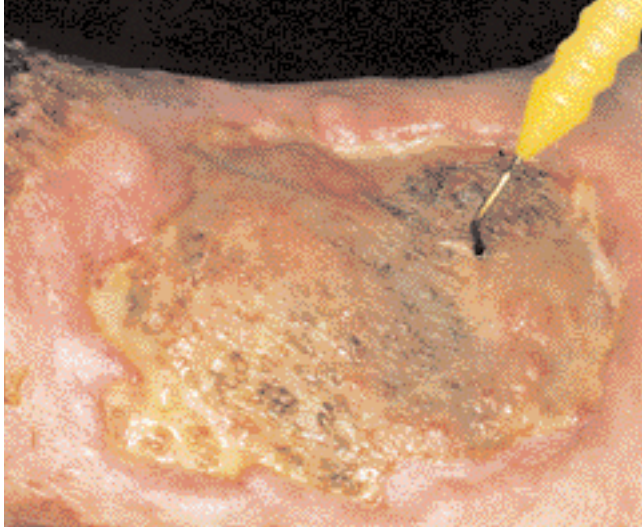
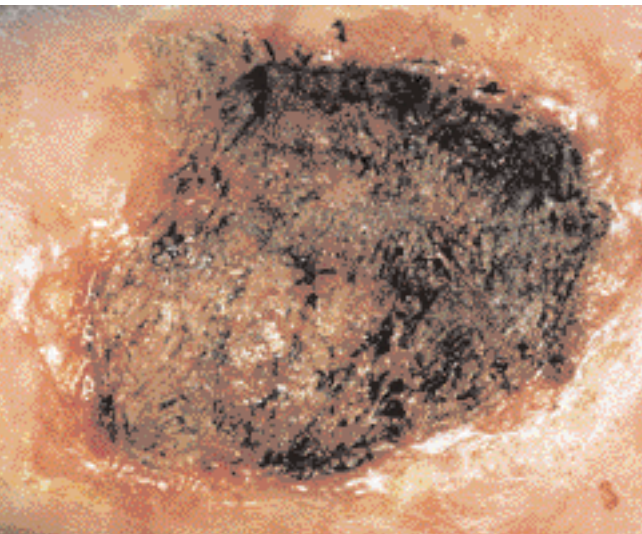
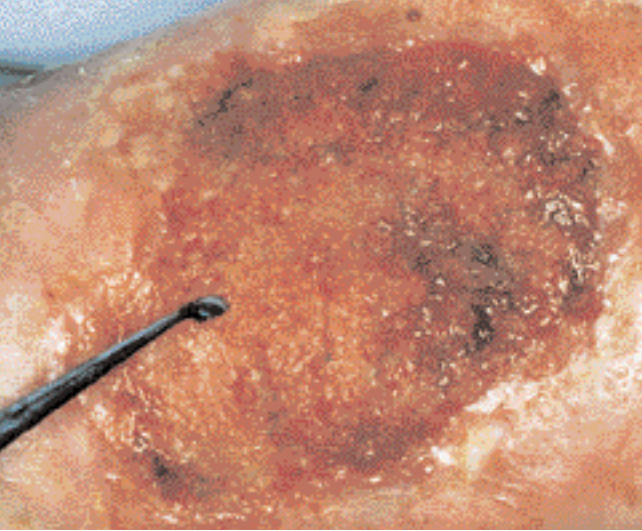


Fig. 51.1.2 Venous ulcers. Timed surgical cleansing is performed every four days, once the fibrin layer has been delicately removed.
(see below)




Saphenectomy and plastic reconstruction using grafts are carried out simultaneously. Programme data: **coagulation with microelectrodes, 50 Watts, EM 15** electro-manipule.

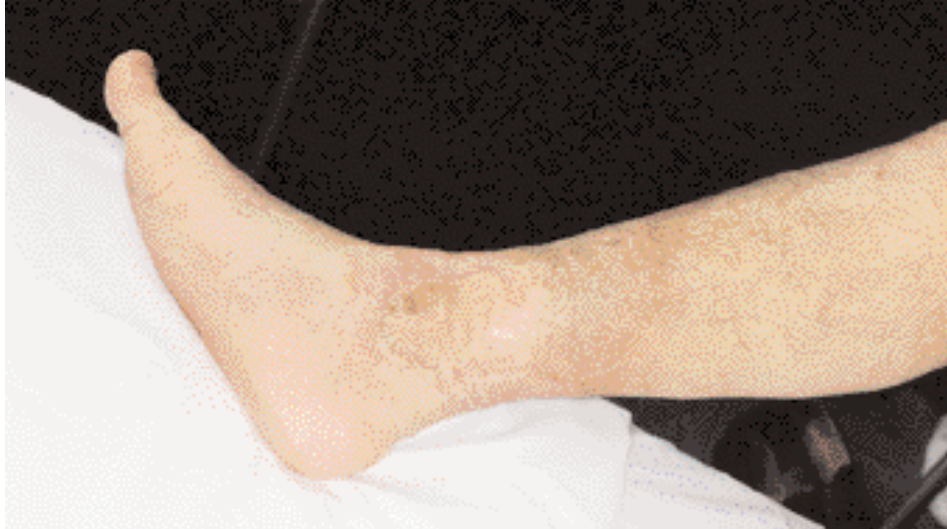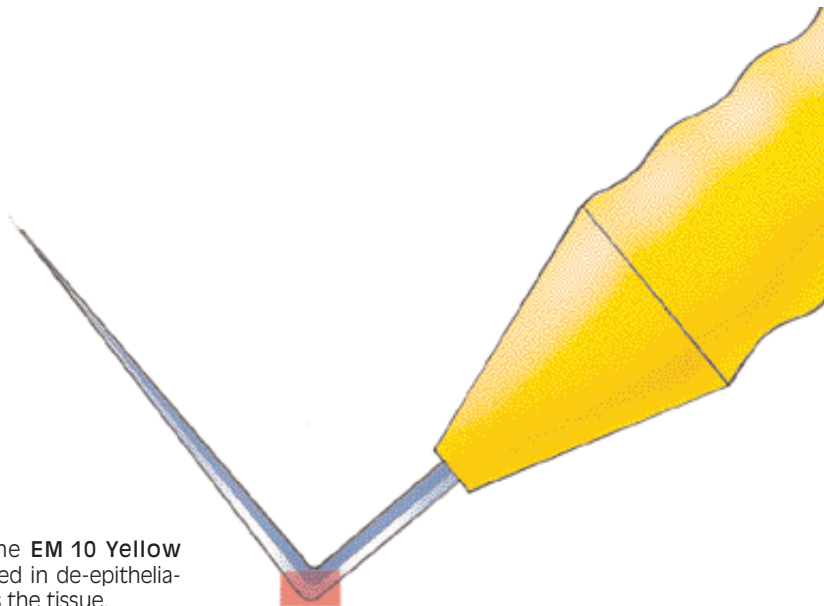


Fig. 51.1.3 Result.

How to use the conducting surface of the EM 10 and EM 15 electromaniples



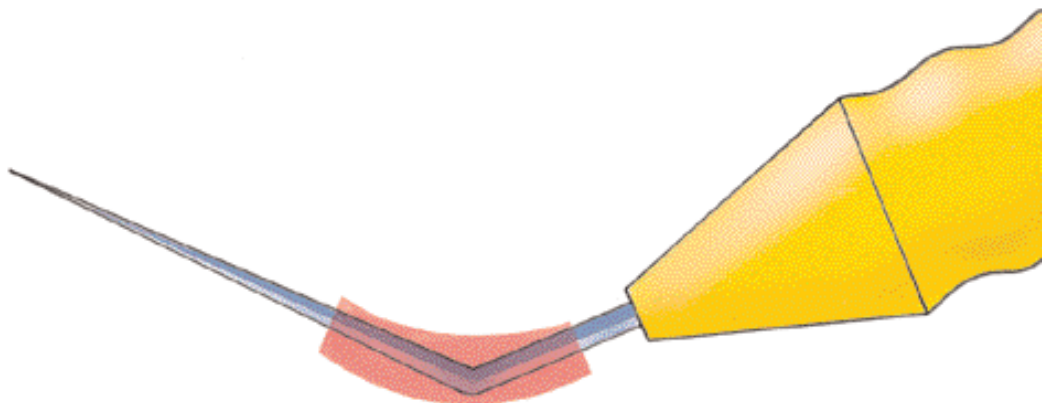
EM 10 electromaniple. Surface used in coagulation. The extreme tip of the electromaniple penetrates the tissues.



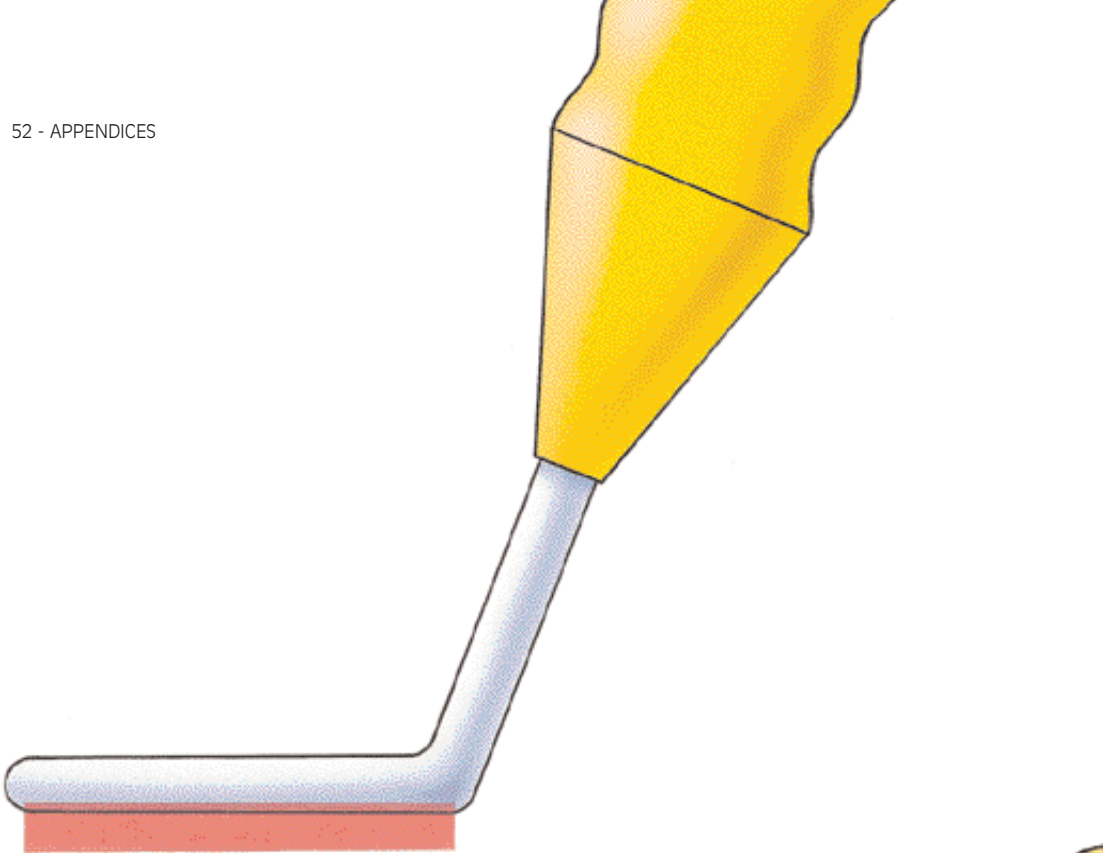
Edge of the corner of the **EM 10 Yellow** electromaniple. Surface used in de-epithelialisation. The operator skims the tissue.



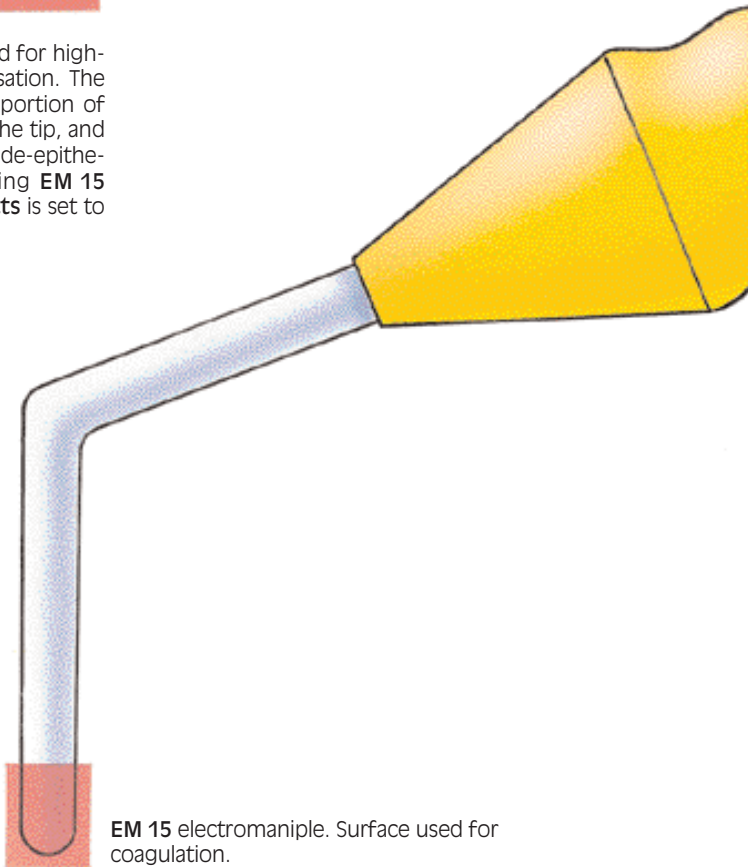
EM 10 electromaniple. Surface used for cutting.



EM 10 Yellow electromaniple bent at an obtuse angle. Surface used for detaching keratoses.



EM 15 electromanipule. Surface used for high-power timed surgical de-epithelialisation. The operator skims the skin with the portion of the point between the angle and the tip, and executes a circular movement to de-epithelialise large areas uniformly. Using **EM 15** electromanipule, a power of **20 Watts** is set to de-epithelialise large areas.




EM 15 electromanipule. Surface used for coagulation.

Programme data used in the most common procedures





TIMEDSURGERY

DIRECT-MODE PROGRAMME DATA

Mode	Function	Power Watts	Electromaniple	Monopolar/ Bipolar	Book Section	CD ROM
Bipolar coagulation of vessels	Coag macroelectrodes	4÷50	Bipolar forceps	Monopolar	8-10	
<i>Comment:</i> Recommended for haemostasis in microsurgery						
Coagulation of vessels	Coag microelectrodes	50 or 72	EM 15 + forceps	Monopolar		
<i>Comment:</i> Recommended for surgical haemostasis.						
Coagulation cutting	Blend	20 or 27	EM 10 Green EM 10 Yellow	Monopolar	17	
<i>Comment:</i> The haemostatic effect is greater than in the cutting function. May be substituted by coagulation with microelectrode						
Treatment of rhinophyma (cutting)	Cut	20 or 27	EM 10 Yellow	Monopolar	17.2	
<i>Comment:</i> Used in rhinophyma surgery						
Treatment of rhinophyma (peeling at high power)	Coag microelectrodes	20 or 27	EM 15	Monopolar	17.2	
<i>Comment:</i> Used in rhinophyma surgery						
Treatment of venous lakes, varices and mucous cysts	Coag microelectrodes	10	EM 10 Yellow	Monopolar	19	
<i>Comment:</i> The tip of the electromaniple is inserted into the lesion, which is coagulated.						




TIMEDSURGERY

DIRECT-MODE PROGRAMME DATA

Mode	Function	PowerElectromaniple Watts	Monopolar/ Bipolar	Book Section	CD ROM
Peeling at low power	Coag microelectrodes	1 or 2	EM 10 Yellow (bent at an angle)	22	
<i>Comment:</i> Enables small raised scars on facial skin resulting from surgical operations to be levelled. Larger scars are levelled by means of timed surgical resurfacing, which is more efficacious and heats the tissues less.					
Elimination of epidermal hyperpigmentation (superficial timed surgical coagulation)	Coag microelectrodes	1	EM 15	26.1	
<i>Comment:</i> Epidermal hyperpigmentation of the face is eliminated by superficial timed surgical coagulation or by timed surgical resurfacing, (Coag microelectrodes, 27 or 38 Watts, EM 15). The coagulated epidermis is not removed.					
Elimination of dermal-epidermal hyperpigmentation (timed surgical de-epithelialisation)	Coag microelectrodes	1	EM 10 Yellow (bent at an angle)	26.3	
<i>Comment:</i> Dermal-epidermal blemishes are eliminated by means of timed surgical de-epithelialisation followed by the application of a resorcin solution for 20 seconds.					
Elimination of tattoos (electrosalting)	Coag microelectrodes	14 or 20	EM 15	Monopolar 27	
<i>Comment:</i> Extensive tattoos can be de-epithelialised prior to salting. Electrosalting is an efficacious procedure but is more complex than timed surgical resurfacing.					


TIMEDSURGERY

DIRECT-MODE PROGRAMME DATA





Mode	Function	Power Watts	Electromaniple	Monopolar/ Bipolar	Book Section	CD ROM
Elimination of lip wrinkles (timedsurgical de-epithelialisation)	Coag microelectrodes	1	EM 10 Yellow (bent at an angle)	Monopolar	28	
Comment: Even deep wrinkles are eliminated by applying saturated resorcin solution to the de-epithelialised area for 1 or 2 minutes.						
Treatment of telangiectatic naevi (timedsurgical de-epithelialisation)	Coag microelectrodes	1	EM 10 Yellow (bent at an angle)	Monopolar	29.2	
Comment: After timedurgical de-epithelialisation, a resorcin solution is applied for 1 or 2 minutes. If injectable vessels are present, up to 6 ml of 8% Bisclero is injected. If the vascular network is deep, numerous micro-perforations are made using the pulsed mode. Direct pulsed 0.3/5/3 hundredths of a second - Cut - 14 Watts - EM 10 White.						
Coagulation of xanthelasma	Coag microelectrodes	20 or 27	EM 15	Monopolar	31	
Comment: Coagulation dries the xanthelasma and must not penetrate beyond the skin of the eyelid.						
Coagulation of common warts	Coag microelectrodes	10, 14 or 20	EM 15	Monopolar	32.1	
Comment: The antiviral effect of the heat is exploited by slowly inserting the tip of the electromaniple into the wart and carrying out small circular movements. The wart detaches from the dermal plane and is removed with scissors. 15% trichloracetic acid is applied to the dermis.						

TIMEDSURGERY

DIRECT-MODE PROGRAMME DATA





	Mode	Function	Power Watts	Electromaniple	Monopolar/ Bipolar	Book Section	CD ROM
Coagulation of non-keratotic neoformations	Direct	Coag microelectrodes	27 or 38	EM 15	Monopolar	-	
Coagulation of condyloma acuminata	Direct	Coag microelectrodes	10,14 or 20	EM 15	Monopolar	33	
<i>Comment:</i> The antiviral effect of the heat is exploited.							
Coagulation of pyogenic granulomas	Direct	Coag microelectrodes	27	EM 15	Monopolar	34	
<i>Comment:</i> Coagulation is carried out until the slight bleeding ceases.							
Coagulation of keratoses	Direct	Coag microelectrodes	14 or 20	EM 15	Monopolar	39	
<i>Comment:</i> The keratotic tissue is coagulated and removed.							
Timedsurgical undermining of keratoses	Direct	Coag microelectrodes	5 or 7	EM 10 Yellow (obtuse angle)	Monopolar	39	
<i>Comment:</i> The open angle of the electromaniple is used to detach the keratosis from the dermis. The dermis must not be coagulated further.							

TIMEDSURGERY
DIRECT-MODE PROGRAMME DATA

Mode	Function	Power Watts	Electromaniple	Monopolar/ Bipolar	Book Section	CD ROM
Hypertrophy of turbinates	Direct Coag microelectrodes	20	Bipolar electrode	Monopolar	42	
<i>Comment:</i> The two tips of the bipolar electrode are run along the turbinate. This operation is combined with timed coagulation of the vascular-nervous centre.						
Cutting	Direct Cut	20, 27, 38 or 50	EM 10 Grey EM 10 Yellow EM 10 Black	Monopolar	49 17	
<i>Comment:</i> Unlike timed and pulsed timsedsurgical cutting, it is not used on the skin as it causes burning at the edges of the cut and retards scarring. Used in rhinophyma surgery and in subcutaneous excision of malignant melanoma						
Treatment of solar keratoses	Direct Coag microelectrodes	50	EM 15	Monopolar	50	
<i>Comment:</i> The micro-arc destroys a solar kearatosis.						
Timsedsurgical cleansing of cutaneous ulcers	Direct Coag microelectrodes	50	EM 15	Monopolar	51	
<i>Comment:</i> Cleanses and “sterilises” all cutaneous ulcers, including those caused by burns, with the exception of arterial ulcers. Shortens healing times.						

TIMEDSURGERY

DIRECT PULSED-MODE PROGRAMME DATA

Mode	Hundredths of a second	Function	Power Watts	Electromaniple	Monopolar/ Bipolar	Book Section	CD ROM
Treatment of telangiectasias of the face	Pulsed 5/29	Coag microelectrodes	7	EM 10 Green	Monopolar	15-16	
<i>Comment:</i> Enables facial telangiectasias to be eliminated without leaving scars. The electromaniple penetrates as deeply as is necessary to coagulate the ectatic capillary. Two or more emissions are generated according to the diameter of the vessel. Timedsurgical treatment is preceded by a few sessions of bisclerotherapy, if the diameter of the vessels is adequate.							
Epilation of the face and body	Pulsed 25/67	Coag microelectrodes	3-5	EM 10 Green	Monopolar	21	
<i>Comment:</i> Definitive epilation can be achieved without leaving any traces. Faster than timed epilation.							
Scar levelling (timedsurgical resurfacing)	Pulsed 0.3/5.3	Cut	50-72	EM 15	Monopolar	23	
<i>Comment:</i> Residual acne scars and raised scars can be levelled by means of timedsurgical resurfacing. As the deep tissues are not heated, healing is rapid.							
Repigmentation of vitiligo (pulsed timedsurgical de-epithelialisation)	Pulsed 4/9	Coag microelectrodes	1 or 2	EM 10 Yellow (bent at an angle)	Monopolar	25	
<i>Comment:</i> Pulsed timedsurgical de-epithelialisation enables the epidermis to be removed while leaving intact the dermal papillae and the capillary-papillary plexus. The dermal base created by this technique enables grafts of autologous keratinocytes and melanocytes to take root perfectly and allows repigmentation of stabilised vitiligo and achromic skin.							



TIMEDSURGERY

DIRECT PULSED-MODE PROGRAMME DATA

Mode	Hundredths of a second	Function	Power Watts	Electromaniple	Monopolar/ Bipolar	Book Section	CD ROM
Elimination of lentigines of the hands	Direct	Pulsed 4/9	Coag microelectrodes	1 - 3	EM 15	Monopolar	26.2
	Direct	Pulsed 03/5.3	Coag microelectrodes	27 or 38	EM 15	Monopolar	26.2
<i>Comment:</i> Senile patches on the hands are often not epidermal but dermal-epidermal, and require two treatment sessions. Leaving the coagulated epidermis in place has a protective function and allows the patient to use the hands freely after a few days.							
Elimination of tattoos (timsurgical resurfacing)	Direct	Pulsed 0.3/5.3	Coag microelectrodes	27 or 38	EM 15	Monopolar	27
<i>Comment:</i> Professional, amateur and traumatic tattoos can be safely removed by means of timsurgical resurfacing. On its first sweep, the tip of the electromaniple brushes the skin, de-epithelialising it. On subsequent sweeps, the tip of the electromaniple skims over the dermis, generating the micro-arc that is characteristic of resurfacing. An area already treated must not be re-treated within 2 months of re-epithelialisation.							
Elimination of wrinkles from the eyelids (pulsed timsurgical de-epithelialisation)	Direct	Pulsed 4/9	Coag microelectrodes	1	EM 10 Yellow (bent of an angle)	Monopolar	28
<i>Comment:</i> Pulsed de-epithelialisation at 1 Watt, followed by application of non-saturated resorcin solution for a few seconds, is used to eliminate wrinkles from the eyelid							



TIMEDSURGERY

DIRECT PULSED-MODE PROGRAMME DATA



	Mode	Hundredths of a second	Function	Power Watts	Electromaniple	Monopolar/ Bipolar	Book Section	CD ROM
Elimination of small non-pedunculated neoformations	Direct	Pulsed 5/29	Coag microelectrodes	38 or 50	EM 15	Monopolar	35-36	
Slow pulsed micro-cutting	Direct	Pulsed 0.5/24.5	Cut	38	EM 10 White EM 10 Green	Monopolar	43-44.1 45-46	
Comment: Cutaneous and mucosal microexcisions are almost bloodless, extremely precise and can be sutured.								
Rapid pulsed cutting	Direct	Pulsed 0.3/5.3	Cut	27-38 50-72	EM 10 White	Monopolar	43-44.2 44.3-49	
Comment: Cutaneous and mucosal incisions and excisions can be performed with great precision and almost bloodlessly. The edges of the cut are not scorched, can be sutured and heal rapidly. Rapid pulsed cutting exerts negligible pressure on the tissues. Also used in upper and transconjunctival blepharoplasty as it allows perfect visibility and precise dissection, as well as providing haemostasis.								
Elimination of Birthmarks (timsurgical resurfacing)	Direct	Pulsed 0.3/5.3	Cut	50 or 100	EM 15	Monopolar	29	
Comment: This new technique looks extremely promising.								

TIMEDSURGERY

TIMED-MODE PROGRAMME DATA

	Mode	Hundredths of a second	Function	Power Watts	Electromanipile	Monopolar/ Bipolar	Book Section	CD ROM
Timed bipolar coagulation in microsurgery	Timed	20	Coag macroelectrodes	7 or 10	Bipolar forceps (1 mm)	Bipolar	8.6	
Comment: Enables accurate electrocoaptation of vessels to be performed in microsurgery.								
Treatment of microtelangiectasias of the face	Timed	3÷9	Coag microelectrodes	7	EM 10 Green EM 10 Grey	Monopolar	15 16	
Comment: Enables facial telangiectasias to be eliminated without leaving scars. The electromanipile penetrates deeply enough to pass through the ectatic capillary. Penetration is facilitated by the timed surgical emission. Two emissions are normally generated. Vessel diameter permitting, the timed surgical treatment is preceded by a few sessions of bisclerotherapy.								
Treatment of Spider naevi	Timed	25÷50	Coag microelectrodes	7	2 partially-sleeved EM 10 Green	Bipolar	18	
Comment: Monopolar timed emissions, as used in the treatment of microtelangiectasias of the face, allow elimination of the fine telangiectasias that branch off from the central vessel. Bipolar timed emissions carried out with two partially-sleeved EM 10 electromanipiles enable electrocoaptation of the ascending artery to be performed at the origin, in the subcutaneous tissue. The procedure does not leave scars on the skin.								
Treatment of telangiectasias in the lower limbs	Timed	9	Coag microelectrodes	7 or 10	EM 10 Yellow	Monopolar	20	
Comment: In the lower limbs three-dimensional regional bisclerotherapy is used. Timed surgical treatment is carried out only if fine capillaries remain which are difficult to inject.								

TIMEDSURGERY
TIMED-MODE PROGRAMME DATA

Mode	Hundredths of a second	Function	Power Watts	Electromaniple	Monopolar/ Bipolar	Book Section	CD ROM
Epilation of the upper lip.	20	Coag microelectrodes	2	EM 10 White	Monopolar	21	
Epilation of the cheeks, chin and body	25		3-4-5	EM 10 Green EM 10 Grey			
<i>Comment:</i> Enables definitive epilation to be carried out rapidly without leaving a trace. All hair in the area selected can be removed in the same session.							
Elimination of small cutaneous cavernous angiomas	99	Coag macro or microelectrodes	14 or 20	Bipolar electrode	Bipolar	30	
<i>Comment:</i> Timed bipolar emissions from the bipolar electrode reduce small cutaneous angiomas and trigger their regression.							
Small common warts	9	Coag microelectrodes	50	EM 15	Monopolar	32.3	
<i>Comment:</i> Small common warts are eliminated by means of a brief high-power emission. After coagulation, 15% trichloroacetic acid may be applied.							
Plane warts	25	Coag microelectrodes	5	EM15	Monopolar	32.4	
<i>Comment:</i> Plane warts are coagulated by means of a prolonged low-power emission, thus enabling the antiviral effect of the heat to be exploited.							




TIMEDSURGERY

TIMED-MODE PROGRAMME DATA

Mode	Hundredths of a second	Function	Power Watts	Electromanipile	Monopolar/ Bipolar	Book Section	CD ROM
Elimination of ruby angiomas	Timed	9	Coag microelectrodes	38 or 50	EM 15	Monopolar	35
<i>Comment:</i> Ruby angiomas are eliminated by means of a brief high-power emission. If they are multiple, the pulsed function at 5/29 hundredths of a second may be used.							
Small non-pedunculated neoformations	Timed	9	Coag microelectrodes	38 or 50	EM 15	Monopolar	36
<i>Comment:</i> Small non-pedunculated neoformations are eliminated by means of a brief-high-power emission. If they are multiple, the pulsed function at 5/29 hundredths of a second may be used.							
Timed cutting	Timed	1÷3	Cut	20-27-38-50	EM 10 Green EM 10 White EM 10 Grey	Monopolar	43-44 47-48 49
<i>Comment:</i> Cutaneous and mucosal micro-incisions and micro-excisions are almost bloodless, extremely precise and can be sutured.							
Punctiform ruby angiomas and all extremely small neoformations	Timed	30	Coag macroelectrodes	7	EM 10 Yellow	Monopolar	37
<i>Comment:</i> Punctiform ruby angiomas and all extremely small neoformations are eliminated by means of a prolonged low-power emission by inserting the tip of the electromanipile into the lesion							
Small multiple keratoses	Timed	99÷10	Coag microelectrodes	20	EM 15	Monopolar	39.2
<i>Comment:</i> Small multiple keratoses are eliminated by means of timed emissions. If the lesions are larger than the tip of the electromanipile, the tip is moved over them like an eraser. If they are very small, the pulsed function at 6/29 hundredths of a second may be used.							




TIMEDSURGERY

TIMED-MODE PROGRAMME DATA

	Mode	Hundredths of a second	Function	Power Watts	Electromanipile	Monopolar/ Bipolar	Book Section	CD ROM
Obliteration of lachrymal ducts	Timed	20	Coag microelectrodes	20	EM 10 Yellow	Monopolar	41	
<i>Comment:</i> Precise programming enables the lachrymal ducts to be obliterated in cases of dryness of the eyes.								
Hypertrophic turbinates (timed bipolar coagulation)	Timed	99	Coag macroelectrodes	20, 27 or 38	Bipolar electrode	Bipolar	42	
<i>Comment:</i> Enables hypertrophic turbinates to be reduced through coagulation of the vascular-nervous centre. This procedure may be combined with bipolar coagulation of the surface of the turbinate, which is particularly effective in the case of vasomotor rhinitis.								
Electroshaving of benign neoformations	Timed	1 or 2	Cut	38 or 50	EM 10 White EM 10 Green EM 10 Grey	Monopolar	43.2	
<i>Comment:</i> Excision of benign neoformations of the trunk and edge of the eyelid is carried out at the level of the dermis. Tissue loss is recovered spontaneously.								
Elimination of pedunculated and liftable neoformations	Timed	10 ÷ 15	Cut	38 or 50	EM 10 Green EM 10 Grey EM 10 Yellow	Monopolar	46	
<i>Comment:</i> Tangential excision of pedunculated and liftable neoformations can be performed by means of a single emission.								

TIMEDSURGERY

TIMED-MODE PROGRAMME DATA

	Mode	Hundredths of a second	Function	Power Watts	Electromaniple	Monopolar/ Bipolar	Book Section	CD ROM
Removal of whiteheads	Timed	2	Cut	20	EM 10 White	Monopolar	47	
Comment: Closed comedones are evacuated by making a micro-incision.								
Removal of milia	Timed	1	Cut	27	EM 10 White	Monopolar	48	
Comment: The epidermal dome of a milium is opened by means of a timed micro-cut.								
Atraumatic excision of melanomas	Timed	3	Cut	50	EM 10 Grey	Monopolar	49	
Comment: The melanoma must not notice that it is being removed. The skin is incised by means of timed cutting. Direct cutting completes excision of the subcutaneous tissue. Tissue loss is sutured.								

BIBLIOGRAPHY

- ALBOM M.: **Electrosurgical treatment of rhinophima.** J. Dermatol. Surg. 2:3, June, 1976.
- AU Y.: **Intralesional electrodesiccation with a 30 gauge needle.** J. Dermatol. Surg. Oncol. 7:3, 1981.
- BARICALLA R.: **L'ipertrofia dei turbinati; Tecnica di decongestione chirurgica.** Otorinolaringol 1991; 41:45-52, 1928.
- BOVIE W.T.: **New electro-surgical unit with preliminary note on new surgical-current generator.** Surg. Gynecol Obstet 47 : 751 - 752, 1928.
- BRUNAMONTI I., CAPURRO S. jr., DE BARBIERI S.: **Il taglio con una corrente ad alta frequenza programmata.** 35° Congr. Naz. Soc. It. Chir. Plast., Milano, 1986.
- BRUNAMONTI I.: **Una nuova tecnica elettrochirurgica: i taglio diatermico programmato.** 79th Annual World Dental Congress of FDI, Ottobre, 1991.
- CAPURRO S.: **Applicazioni della diatermocoagulazione temporizzata (TD) in dermatologia estetica.** La Medicina Estetica, 3, 130, 1979.
- CAPURRO S.: **Diatermocoagulazione temporizzata per il trattamento delle microteleangettasi del volto (primi risultati).** Minerva Chirurgica, 48, 947, 1983.
- CAPURRO S.: **Diatermocoagulazione temporizzata bipolare (BTD) per il trattamento degli spider naevi.** 33° Congr. Naz. Soc. It. Chir. Plast., Capri, 1984.
- CAPURRO S.: **Diatermocoagulazione temporizzata per il trattamento delle piccole neoformazioni cutanee benigne non peduncolate.** Riv. It. Chir. Plast., 16, 291, 1984.
- CAPURRO S.: **La depilazione con la diatermocoagulazione programmata (TD).** Chronica dermatologica, Marzo-Aprile, 1986, n° 2.
- CAPURRO S.: HESSE A., TONIUTTI F., MAELLO M.: **Il diatermocausterio programmabile, un nuovo strumento microchirurgico.** Acta Chir. Ital. Vol. 42, fasc. 5, 1986.
- CAPURRO S.: BRUNAMONTI I.: **Una nuova tecnica elettrochirurgica: la diatermocoagulazione programmata.** La Medicina Estetica. Salus Internazionale, Roma, 1987.
- CAPURRO S.: **Elettrosalatura: una nuova prospettiva nell'eliminazione dei tatuaggi (primi risultati).** 3° Congr. Naz. Soc. It. Chir. Derm., Tirrenia, 1988.
- CAPURRO S.: **Diatermochirurgia Programmata: applicazioni dermatologiche.** 3° Congr. Naz. Soc. It. Chir. Derm., Tirrenia, 1988.
- CAPURRO S.: **Applicazioni dermatologiche ed estetiche della diatermochirurgia tradizionale e della diatermochirurgia programmata.** Cong. Naz. Soc. It. Dermatologia, Genova, 1988.
- CAPURRO S., DALLA COSTA R., CECCHI F., GABRIELLI A.: **Detersione diatermica delle ulcere cutanee. Primi risultati.** XV Congr. Soc. Ital. di Ricerche in Chirurgia, V Congr. Soc. Ital. di fisiopatologia Chirurgica. Bologna, V., 1990.
- CAPURRO S.: **Diatermochirurgia Programmata Dermatologica Estetica.** Edizioni D'Arsonval, Genova, 1993.
- CAPURRO S., FIALLO P.: **Epidermal de-epithelialisation by programmed diathermosurgery.** Dermatol. Surg., 1997; 23:600-601.
- CAPURRO S., RAVA C., FERRERO S.: **Tolleranza ed efficacia delle soluzioni Bisclero 6% e Bisclero 10% nella scleroterapia estetica.** La medicina estetica. Anno 22, numero 4, 1998.
- CASSON Ph.: **Basal cell carcinoma.** Clinics in Plastic Surgery, Vol. 7, n° 3, July 1980.
- COOK AW et Al.: **Vascular disease of extremities: electrical stimulation of spinal cord and posterior roots.** N.Y. State J. Med. 76 : 366 - 368, 1976.
- CRITTENDEN F. M., jr.: **Salabrasion - removal of tattoos by superficial abrasion with table salt.** Cultis, 7 : 295-300, 1971.
- D'ARSONVAL A. **Compt. Rend. Soc. de Biol.** 43 : 283, 1891; 45 : 122, 1893.
- D'ARSONVAL A.: **Action physiologique des**

- courants alternatifs a grande fréquence.** Arch. Physiol Norm. Pathol. 5:401-408, 1893.
- DOYEN D.: **Sur la destruction des tumeurs cancéreuses accessibles par la méthode de la voltaisation bipolaire et de l'électro-coagulation thermique.** Arch. Elec. med. 17 : 791-795, 1909.
- DOWSE C.M., IREDELL C.E.: **The effective resistance of the human body to high frequency currents.** Arch. Radiol. Electrotherap. 25-33-46; 1920.
- EPSTEIN N. N.: **Electrodesiccation and curettage.** in Epstein E. (ed): Skin Surgery, Philadelphia: Lea and Febiger, 1962.
- FORFORI P., SERRA CERVETTI, G.G., CAPURRO S. J.: **Detersione diatermica delle ulcere flebotattiche.** Minerva Angiol 1993, 18: 197, 201.
- FREERK G.: **Surgical depilation for treatment of pseudofolliculitis or local hirsutism of the face.** Plast. Reconstr. Surg. 390-395, Vol. 62, 3, 1978.
- GARDEN J.M., POLLA L.L., TAN O.T.: **The treatment of Port-Wine Stains by the pulsed dye laser: analysis of pulse duration and long-term therapy.** Arch. Dermatol. 124-889-896, June 1988.
- GEDDES L.A. and BAKER L.E.: **The specific resistance of biological material: a compendium of data for the biomedical engineer and physiologist.** Med. Biol. Eng. 5 : 271 - 193, 1967.
- GILCHREST B., FITZPATRICK T.B., et Al.: **Localization of melanin pigmentation in the skin with wood's lamp.** Br. J. Dermatol 96 : 245 - 248, 1977.
- GREENWOOD J. Jr: **Two point or interpolar coagulation: review after a twelve-year period with notes on addition of a sucker tip.** J. Neurosurg. 12/ 196-197, 1955.
- GUEQUIRRE J.P. and VIEDMAN F.D.: **High frequency currents in performing biopsies.** Jama Vol. 103? n° 22 Dec., 1934.
- GUERRA L., CAPURRO S., MELCHI F., PRIMAVERA G., BONDANZA S., CANCEDDA R., LUCI A., DE LUCA M., PELLEGRINI G.: **Treatment of «stable» vitiligo by timed surgery and transplantation of cultured epidermal autograft.** Archives of Dermatology in press.
- IMAYAMA S. KOLIDA H. AND URABE H.: **An electron microscope study on the vascular spider (Japa).** Dept. Dermatol., Fac. Med, Kyushu Univ. Eukuoka Jpn - Nischinihon J. Dermatol. 1980 42/6 (1977-1985).
- INABA M.: **The treatment of hircismus and hyperhidrosis of the axilla.** 2nd ed. Tokyo, Kinensha, 1976.
- INABA M. MCKINSTRY T., ANTHONY J. and EZAK T.: **Regeneration of axillary hair and related phenomena after removal of deep dermal and subcutaneous tissue by a special «shaving» technique.** J. Dermatol. Surg. Oncol. 4:921-925, 1978
- INABA M.: **Histological study of regeneration of axillary hair after removal with subcutaneous tissue shaver.** J. Invest. Dermatol. 72:224-231, 1979.
- JOHANNESSEN A.: **A Simplified Method of focal salabrasion for removal of linear tattoos.** J. Dermatol. Surg. Oncol. 11:10, 1985.
- JUHLIN L., EVERS H., BROGERG F.: **A lidocaine-prilocaine cream for superficial skin surgery and painful lesions.** Acta Derm. Venereol (Stckh) 1980: 60: 544-546.
- KARP F.L.: **High frequency current in the treatment of hypertrichosis.** Arch. Dermat. Syph., 43, 8-9 January, 1941.
- KELLY H.A., WARD G.E.: **Electrosurgery.** Philadelphia, WB Saunders Co, 1932.
- KIM M. BRUTUS P.: **Electrocoagulation percutanée d'angiomes et de varices des membres inférieurs.** Presse Méd. 1983, 12, pp. 1545-1546.
- KLEIN J.A.: **The tumescent technique for lipo-suction surgery.** AM. J. Cosmet Surg. 4: 163-167, 1987.
- KOERBER W.A. Jr, and PRICE N.M.: **Salabrasion of tattoos. A correlation of the clinical and histological results.** Arch. Dermatol. 114: 884-888, 1978.
- KOPF A.W., BART R.S., SCHRAGER D. et Al.: **Curettage and electrodesiccation treatment of basal cell carcinoma.** Arch. Dermatol., 113:439, 1977.
- KRULL E.A., PICKARD S.D. HALL J.C.: **Effects of electrosurgery on cardiac pacemakers.** J. Dermatol. Surg. 1 (3): 43-45, 1975.
- MALIS L.I.: **Bipolar coagulation in microsurgery.** Microvascular Surgery (Donaghy R.M.P. and Yasargil A.G. Eds.) Stuttgart: G. Thieme Verlag 1967.
- MANGIANTE P., BRUNAMONTI I., FAZIO S.: **Uso del taglio diatermico programmato in chirurgia orale.** Parodontologia e Stomatologia (Nuova), XXVI, 3 - 1987.
- MOCK H.E.: **Electrosurgery.** Jama, Vol. 104, n° 26, June 29, 1935.
- MONTAGNA W., DOBSON R.L.: **Hair Growth.** 19-33, Vol. IX, Pergamon Press Ltd, Oxford, 1967.

NAGELSCHMIDT F.: **Zur indikation der Behandlung mit hochfrequenz Ströme.** Deutsch med. wschr 33: 1025-1026; 1289-1291, 1907.

O'REILLY K.: **A technique of diathermy sclerosis of varicose veins.** Aust N.Z.J. Surg. Vol. 51 - n° 4, August, 1981.

OTTO J.F. and BLUMBERG T.: **Techniques of office electrosurgery.** Ed. Liebel-Plarsheim Company, Cincinnati, Ohio, USA, 1949.

POZZI M.: **Remarques sur la fulguration.** Bull. Assoc. Franc. Cancer. 2-64 - 69, 1909.

RAMELET A.A., RUFFIEUX C., POFFET D.: **Complications locales après sclérose à la glycérine chromée.** Phebologie 48. N° 3, 377-380, 1995.

RIEFKOHLE R., GEORGIADIS G.S., BARWICK W.J. and GEORGIADIS N.G.: **Rhynophyma: A thirty-five year experience.** Aesth. Plast. Surg. 7: 131-134, 1983.

RIVIÈRE A.J.: **Action des courants de haute fréquence et des effluves du résonateur Oudin sur certaines tumeurs malignes.** Journal de Médecine interne: 4: 776 - 777, 1990.

ROBINSON J.K.: **Extirpation by electrocautery of massive lesions of condyloma acuminatum in the genito-perineo-anal region.** J. Dermatol. Surg. Oncol. 6:9, 1980.

ROFFO A.: **Libro de Oro**, 1935.

RORIE D.K., DAVID E.B., DAVID O.N. RUNGSON S. KENNETH A.J.: **Assessment of block of the sciatic nerve in the popliteal fossa.** Anesthesia and analgesia, Vol. 59, n° 5, May 1980.

SAUNDERS T.S.: **Minimal scarring after electrodesiccation.** Arch. Derm. 45: 1166 June 1942.

SCHRODER T., HUKKL J., et Al.: **Comparison of surgical lasers and conventional methods in skin incisions.** Scand J. Plast Reconstr. Surg. 23: 187-190, 1989.

SCUTT R.W.B.: **The chemical removal of tattoos.** Br. J. Plast. Surg. 25:189, 1972.

SEMM K.: **New apparatus for cold coagulation of benign cervical lesions.** An. J. Obst. Gynec., 95, 7, 963, 1966.

SHELLEY W.B. and SHELLEY E.D.: **Focal salabrasion for removal of linear tattoos.** J. Dermatol. Surg. Oncol. 10:3 1984.

SHIELDS J.L. and JAN S.: **Therapy for superficial telangiectasias of the lower extremities.** J. Dermatol. Surg. Oncol. 8:10, 1982.

SIGEL B. and ACEVEDO F.J.: **Electrocoaptive**

union of blood vessels; a preliminary experimental study. J. Surg Res. 3:90, 1963.

SIGEL B. and DUNN M.R.: **The mechanism of blood vessel closure by high frequency electrocoagulation.** Surg. Gynec. and Obstetrics, 823-831, Oct. 1965.

SZABO G.: **The regional anatomy of the human integument with special reference to the distribution of hair follicles, sweat glands and melanocytes.** Phil. Trans. R. Soc. B 252, 447, 1967.

STREFFER C.: **Cancer therapy by hyperthermia and radiation.** Urban Schwarzenberg Baltimore, 1978.

TESTUD L.: **Anatomia Umana.** Libro settimo, 98-119, Unione Tipografico-Editrice Torinese, torino, 1931.

WYETH G.A.: **Surgery of neoplastic diseases by electrothermic methods.** New York, Paul B. Hoebr, Inc., 1926.

WYETH G.A.: **The endotherm.** Amer. J. surg. 18:417-441 (Dec.), 1932.

INDEX

A

Acne scars, 23
Adaptability of programme data, 14
Anaesthesia, 12
Angiomas, 19, 29, 30

B

Biopsy procedures, 8.9
Bipolar coagulation, 8.6, 8.7, 18
Bipolar forceps, 7.1, 8.6, 8.7
Bipolar mode, 7.1, 8.6
Birthmarks, 29
Bisclero, 20.1, 15.1, 16
- regional three-dimensional bisclerotherapy, 20.2
Blend, 6, 8.9, 10.1
Blepharoplasty of the upper lid, 44.2

C

Cavernous haemangiomas, 30
Chalazion, 44.1
Coag microelectrodes, tab. 7.4, 8.5
Coag macroelectrodes, tab. 7.4, 8.5
Coagulation, 8.4
Condylomata acuminata, 33
Couperosis, 15
Current, 2
- high frequency current, 2.3
Cutaneous hyperpigmentation, tab. 20.2, 26
Cutting, 6
Cutting, 8.8, 9, 10.1, 11.3
- timed and pulsed timed surgical cut, 5.4, 8.10, 8.11, 43, 44, 45, 46, 47, 48, 49, tab. 43.1, tab. 8.2

D

De-epithelialisation, 24, 25, 26, 27, 28, 29
- de-epithelialisation at 1 Watt, 24.2
- pulsed de-epithelialisation, 24.3
- de-epithelialisation over larger areas, 24.4

E

EA1 cable, 7.9
Ectatic vessels of the lower extremities, 20
Electrobliteration, 10.1, 43
Electrocoaptation, 10.2
Electrodes, 7
Electromanipules, 7.5, 7.6, 7.7
Electrosalting, 27.2
Electroshaving, 43.2
Electrosurgery, 1
Epilation, 21
Eyelid lesions,
- excision of, 44.1

F

Facial telangiectasia, 15
Fibromas of the nose, 36
Fulgoration, 4.3, 4.4, 8.1,
Functions, 8

H

Haemostatic forceps, 10.23
Hirsutism, 21
Hyperpigmentation, 26
Hypertrichosis, 21

I

Infection, 37, 51
Ingrowing toe-nails, 40

K

Keratoses, 39

L

Lachrymal canals,
- coagulation of, 41
Lasersurgery, 15, 31.5
Lidocaine, 12, 15, 20.1

M

Macroelectrodes, tab. 7.4, 7.8, 7.2
Medical diathermy, 4.1
Melanoma, 49
Mepivacaine, 12
Micro-arc, 4.6, 23, 27.1, 50, 51
Microelectrodes, tab. 7.4, 7.8, 7.2
Micro-excision, 8.10, 8.11, 43, 44
Microtelangiectasias, 15
Milia, 48
Mixed peeling, 26.2, 27.2, 28, 29
Monopolar, 7.1
Mucous cysts, 19

N

Naevus flammeus, 29
Nasal turbinates, 42

P

Pace-maker, 2.4, 7.2, 13.2
Pedunculated lesions, 46
Peeling
 - timedsurgical peeling, 22, 17.1
 - mixed timedsurgical peeling, 24, 26.2, 27.2, 28.1, 29.2
Photographic documentation, 14
Polydocanol, 20.1
Practising timedsurgical techniques, 11
Precancerous lesions, 50
Pulsed functions, 6
Pyogenic granulomas, 34

R

Rapid pulsed cutting, 6, 43, 44.2, 44.3, 45
Red nose, 16
Resorcin solution, 26.3, 26.4, 28, 29
Resurfacing, 23, 24.4, 26.1, 26.2, 27.1, 29
Rhinophyma
 - medium-grade rhinophyma, 17.1
 - high-grade rhinophyma, 17.2
Ruby angiomas, 35
 - punctiform ruby angiomas, 37

S

Scars,
 - small scars, 22
 - hypertrophic scars, 23
 - acne scars, 23
 - acromic scars, 25
Sclerosing solution, 20
Sclerotherapy, 20.1
Senile lentigo, 26

Slow pulsed cutting, 6, 43, 44.1, 45
Small non-pedunculated lesions, 36
Sodium chloride, 27.2
Sodium salicylate, 20.1
Soft fibromas, 46
Solar Keratosis, 50
Spark, 2.3, 4.4
Spider naevus, 18
Surgical diathermy, 4.2

T

Tattoo
 - timedsurgical resurfacing, 23.1, 27.1
 - electrosalting, 27.2
Telangiectasia of the face, 15
Telangiectasia of the lower extremities, 20
Timed apparatus, 6
Timed/Direct, 6
Timedsurgery, 1, 4.6, 5
Timedsurgical de-epithelialisation, 24, 25, 26, 27, 28, 29
Timedsurgical resurfacing, 23, 24.4, 27.1
Timedsurgical undermining, 39.3
Tissue conductivity, 3, 8.3, 15.2
Transconjunctival lower blepharoplasty, 44.3
Trichloroacetic acid, 31.32

U

Ulcers,
 - timedsurgical cleansing of, 51

V

Vaporisation, 8.3
Vaporising process, 4.2, 5.2, 8.8
Venous lakes, 19
Very small lesions, 37
Vitiligo,
 - re-pigmentation of, 25

W

Warts,
 - common warts, 32.1, 32.3
 - plane warts, 32.4
 - plantar warts, 32.2
Whiteheads, 47
Wood light, 25
Wrinkles,
 - elimination of, 24.3, 28

X

Xanthelasmas, 38



CD ROM TIMEDSURGERY

MINIMUM SYSTEM REQUIREMENTS

WIN

Intel Pentium 166 MHz
processor or equivalent
Windows 95/98 or NT 4.0
operating system
32 Mb di memory RAM
Color monitor,
800x600 pixels resolution, 24 bits
CD-ROM drive
sound card

MAC

PowerPC 100 MHz processor
7.6.1 operating system or upper
32 Mb di memory RAM
Color monitor,
800x600 pixels resolution, 24 bits
CD-ROM drive

EXECUTION INSTRUCTIONS

Double click on Timedsurgery icon: in case QuickTime installation is required, open QuickTime 3 installer folder, double click on install QuickTime icon and follow instructions.



*Timedsurgery, Timed, Korpo, D'Arsonval and
Bisclero are registered trademarks of
Korpo srl. - Via XX Settembre, 3/28 - 16121 Genova
Tel. 0039 010 580335 - Fax 0039 010 566968
info@korpo.com*

*Printing completed in March 2002 by Press Point, Abbiategrasso (Milan)
on behalf of Edizioni D'Arsonval®,
a dipartment of Korpo® srl, Genoa Italy*